Journal of Entomology and Zoology Studies

Available online at www.entomoljournal.com

E-ISSN: 2320-7078
P-ISSN: 2349-6800
JEZS 2019; 7(1): 137-142

Received: 11-11-2018
Accepted: 15-12-2018

R Prathisha
a) Department of Fish Pathology and Health Management,
b) Fisheries College and Research Institute, Thoothukudi, Tamil Nadu, India

Dr. M Rosalind George
a) Department of Fish Pathology and Health Management,
b) Dr MGR, FCRI Thalainayeru at TNFU Campus, Nagapattinam, Tamil Nadu, India

Dr. K Riji John
a) Department of Fish Pathology and Health Management,
b) Fisheries College and Research Institute, Thoothukudi, Tamil Nadu, India

Correspondence
R Prathisha
a) Department of Fish Pathology and Health Management,
b) Fisheries College and Research Institute, Thoothukudi, Tamil Nadu, India

Assessment of occurrence of *Enterocytozoon hepatopenaei* (EHP) in South Tamil Nadu

R Prathisha, Dr. M Rosalind George and Dr. K Riji John

Abstract
Disease surveillance work was carried out for the occurrence of *Enterocytozoon hepatopenaei* (EHP) in South Tamil Nadu during the period of September 2017 to May 2018 covering the districts of Nagapattinam, Thanjavur, Pudukottai, Ramanathapuram and Thoothukudi. For the assessment of occurrence of EHP in South Tamil Nadu, samples of *Penaeus vannamei* and *Penaeus monodon* were collected. A total of 73 shrimp samples were collected from shrimp farms and were diagnosed for the presence of EHP. Out of 73 shrimp samples collected, 27 (36.98%) samples were positive for EHP. The average *Vibrio* sp count of water and soil collected from EHP infected ponds were 5.083×10^3 (CFU/ml) and 5.62×10^3 (CFU/g) respectively, whereas the average *Vibrio* sp count of water and soil collected from EHP uninfected ponds were 6.33×10^3 (CFU/ml) and 3.23×10^4 (CFU/g) respectively. The screening of EHP was done with primers that targets 18s rRNA of the EHP.

Keywords: *Enterocytozoon hepatopenaei*, hepatopancreatic microsporidiosis, prevalence, Tamil Nadu

1. Introduction

Indian aquaculture showed a tremendous growth during the past decade. This is mainly due to the intensification in the aquaculture practices [24]. In shrimp aquaculture, *P. monodon* was the major farmed species till 2009, when a non-native hardy shrimp species *P. vannamei* was introduced during the year 2009-10 [24]. Culture of vannamei gained popularity due to its fast growth and column feeding habit and was increasingly taken up by the Indian farmers and the production showed an upward trend since 2009 [11]. Infectious diseases form the major constraint to the shrimp aquaculture. Spread of diseases has been promoted by the use of live or fresh broodstock feeds such as polychaetes and clams [21]. Also, shortages in the supply of imported SPF broodstock led some entrepreneurs to employ post larvae (PL) of imported SPF stocks to produce 2nd generation broodstock in open shrimp ponds where they became contaminated and carried latent pathogens. These practices left the whole shrimp industry vulnerable to rapid spread of the new emerging diseases and resulting in the current crisis in Asian shrimp culture [22].

Enterocytozoon hepatopenaei (EHP) is a recently emerging shrimp pathogen that causes severe growth retardation in shrimps resulting in a disease condition known as hepatic microsporidiosis [1, 4, 18, 20, 22]. The EHP is yeast like fungus belonging to a group called microsporidia. The parasite is an obligate intracellular pathogen affecting highly valued shrimps like tiger shrimp and the Pacific white shrimp resulting in growth retardation. The first report for the slow growth in shrimps was reported at Malaysia in *Penaeus monodon* [1]. And later similar slow growth syndrome was reported in *Penaeus japonicas* [9]. From these facts it has been suggested that that EHP is not an exotic pathogen but that it is endemic to Australasia. The first record of the emergence of EHP in Indian shrimp aquaculture was reported in 2016 covering 3 farms at south east coast of India [14]. Molecular diagnostic assays reported for screening of EHP includes single step PCR [22, 20], nested PCR [20, 10], Loop Mediated Thermal Amplification (LAMP) [15, 17], Real time PCR [13] and insitu hybridization [18]. Recent outbreak of hepatopancreatic microsporidiosis in shrimp warrant the researchers to pay attention towards the parasitic infections [16]. The current study was therefore carried out to find the prevalence of this serious *Enterocytozoon hepatopenaei* pathogen in the coastal districts of South Tamil Nadu.

2. Materials and Methods

2.1 Sources of samples

Shrimp samples which included *Penaeus monodon* and *Penaeus vannamei*, were collected from the shrimp farming ponds of South Tamil Nadu covering districts of Nagapattinam, Thanjavur, Pudukottai, Ramanathapuram, and Thoothukudi. The sampling window ranged from September 2017 to May 2018. A total of 73 samples along with the soil and water samples were collected. The animals were collected in live condition in polyethylene bags kept in ice and transported to the laboratory and were processed within 24 hours. The soil and water samples were collected in 50 ml sterile centrifuge tubes.

2.2 Obtaining samples for microbiological diagnosis from shrimp

The animal and soil samples were taken for microbiological analysis. The hepatopancreas from the animal samples were streaked to the TCBS (selective agar for *Vibrio* species) agar plate. The isolated colonies from the TCBS plate were then stored in glycerol stock. The soil and water samples were spread plated on the TCBS plate. Then the plates were incubated for 24 hrs at room temperature. And the total vibrio count for the water and soil samples was calculated.

2.3 DNA extraction from the samples

For the DNA isolation from animals, gills, pleopods, gut and hepatopancreas were pooled and used. The pooled samples were limited to not more than 50 mg. DNA express reagent kit (HIMEDIA) was used for the isolation of DNA from the samples as per manufacturer's instruction and was stored at 4˚ C (HIMEDIA DNA extraction kit method).

Primers (Lightner DV, University of Arizona) targetting 18s rRNA of EHP were used for the screening the samples for the presence of EHP (Table 1). The DNA was used for the amplification of EHP DNA using primers (Table 1). The amplification products were analysed using agarose gel electrophoresis (Fig 1).

Table 1: Primers used for the screening of EHP.

Target gene	Primer sequence 5'- 3'	Size of PCR product (bp)	Annealing conditions
Single step SSU gene	GGG AAC GAC GAA CGG CTC AGT CCG TTG GTC CAG GTG GGG TC	517	70˚C/15 sec
Nested step SSU gene	GCC AGC AGCCGC GGT AAT TC CCG TTG GTC CAG GTG GGG TC	191	70˚C/15 sec

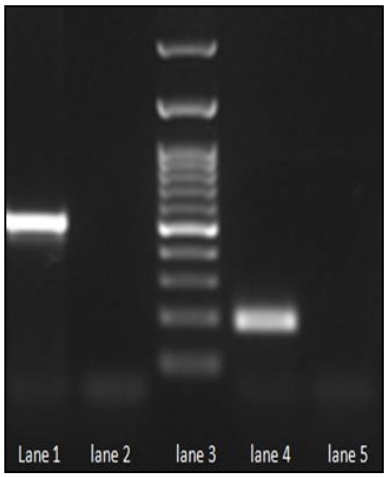

Fig 1: Detection of EHP using primers. Agarose gel electrophoretic analysis of the PCR products obtained from the EHP positive samples with primers targeting SSU rRNA of the EHP microsporidian. Lane 1: single step EHP positive control (517bp); Lane 2: negative control; Lane 3: 100bp marker (Gene Direx, Inc.); Lane 4: nested step EHP positive control (191bp); Lane 5: negative control

2.4 PCR screening of samples for EHP

An aliquot (2µl) of the DNA was analysed by PCR in a reaction mixture of 25 µl contained, 2 µl of DNA, 2 µl of each forward and reverse primer, 12.5 µl of master mix (Smart prime; 2X PCR Mastermix) and 6.5 µl of deionised water. The PCR step was carried out in eppendorf Mastercycler gradient and BIO-RAD T100 Thermal cycler. Pure agarose procured from Lonza, USA was used for separation of the PCR amplicons by gel electrophoresis. The amplified products were resolved by agarose gel electrophoresis. Agarose gel of 1.5% were prepared by using 1X Tris-Borate-EDTA buffer (TBE buffer) containing 0.2 µg of ethidium bromide/ ml. For electrophoresis, the apparatus was assembled with comb and the mixture was loaded on casting tray and allowed to solidify. After setting, the comb was removed carefully so as the wells are not damaged. The gel was placed on horizontal gel electrophoresis apparatus and running buffer was added to just immerse the gel surface. About 7 µl of PCR product were loaded alongside the 100 bp DNA ladder (5 µl). The loaded products were electrophoresed at 90 v for 40 min, viewed and documented in UV gel documentation system (Biorad, USA).

Table: Statistical data

S. No.	Sample code	Date of sampling	Farm location	District	Name of the species cultured	Days of culture	Result for EHP	
							Single step	Nested step
1	P-1	26.09.2017	Manamelkudi	Pudukkottai	*P. vannamei*	58	positive	positive
2	P-2	26.09.2017	Manamelkudi	Pudukkottai	*P. vannamei*	32	positive	positive
3	P-3	26.09.2017	Manamelkudi	Pudukkottai	*P. vannamei*	27	positive	positive

4	P-4	26.09.2017	Manamelkudi	Pudukkottai	*P. vannamei*	39	positive	positive
5	P-5	16.10.2017	Vepalodai	Thoothukudi	*P. vannamei*	66	positive	positive
6	P-6	16.10.2017	Vepalodai	Thoothukudi	*P. vannamei*	66	positive	positive
7	P-7	16.10.2017	Vepalodai	Thoothukudi	*P. vannamei*	33	positive	positive
8	P-8	16.10.2017	Vepalodai	Thoothukudi	*P. vannamei*	135	positive	positive
9	P-9	25.10.2017	Thethakudi south	Nagapattinam	*P. vannamei*	120	negative	negative
10	P-10	25.10.2017	Thethakudi south	Nagapattinam	*P. vannamei*	120	negative	negative
11	P-11	25.10.2017	Periyakuthagai	Nagapattinam	*P. vannamei*	60	negative	negative
12	P-12	25.10.2017	Periyakuthagai	Nagapattinam	*P. vannamei*	60	negative	negative
13	P-13	07.11.2017	Kottaipattinam	Pudukkottai	*P. vannamei*	51	negative	negative
14	P-14	07.11.2017	Kottaipattinam	Pudukkottai	*P. vannamei*	51	negative	negative
15	P-15	10.11.2017	Periyakuthagai	Nagapattinam	*P. vannamei*	75	negative	negative
16	P-16	10.11.2017	Periyakuthagai	Nagapattinam	*P. vannamei*	75	negative	negative
17	P-17	10.11.2017	Thethakudi south	Nagapattinam	*P. vannamei*	79	negative	Positive
18	P-18	10.11.2017	Thethakudi south	Nagapattinam	*P. vannamei*	79	negative	negative
19	P-19	10.11.2017	Thoputhurai	Nagapattinam	*P. vannamei*	26	negative	Positive
20	P-20	21.11.2017	Kottaipattinam	Pudukkottai	*P. vannamei*	65	negative	negative
21	P-21	21.11.2017	Kottaipattinam	Pudukkottai	*P. vannamei*	65	negative	negative
22	P-22	5.12.2017	Kottaipattinam	Pudukkottai	*P. vannamei*	79	Negative	Negative
23	P-23	5.12.2017	Kottaipattinam	Pudukkottai	*P. vannamei*	79	Negative	Negative
24	P-24	11.12.2017	Vepalodai	Thoothukudi	*P. vannamei*	120	Negative	Negative
25	P-25	11.12.2017	Vepalodai	Thoothukudi	*P. vannamei*	96	Negative	Negative
26	P-26	11.12.2017	Vepalodai	Thoothukudi	*P. vannamei*	96	positive	positive
27	P-27	11.12.2017	Vepalodai	Thoothukudi	*P. vannamei*	96	positive	positive
28	P-28	22.12.2017	Kottaipattinam	Pudukkottai	*P. vannamei*	94	positive	positive
29	P-29	22.12.2017	Kottaipattinam	Pudukkottai	*P. vannamei*	94	Negative	Negative
30	P-30	22.12.2017	Peravurani	Thanjavur	*P. vannamei*	67	Negative	Negative
31	P-31	22.12.2017	Karayankadu	Thanjavur	*P. vannamei*	67	Negative	positive
32	P-32	04.01.2018	Pushpavanam	Nagapattinam	*P. vannamei*	120	positive	positive
33	P-33	01.02.2018	Thethakudi north	Nagapattinam	*P. vannamei*	90	Negative	Negative
34	P-34	01.02.2018	Thethakudi north	Nagapattinam	*P. vannamei*	94	Negative	positive
35	P-35	01.02.2018	Thoputhurai	Nagapattinam	*P. vannamei*	35	Negative	Negative
36	P-36	13.03.2018	Mimisal	Pudukkottai	*P. vannamei*	15	Negative	Negative
37	P-37	13.03.2018	Mimisal	Pudukkottai	*P. vannamei*	15	Negative	Negative
38	P-38	13.03.2018	Mumpalai	Pudukkottai	*P. vannamei*	39	Negative	Negative
39	P-39	13.03.2018	Mumpalai	Pudukkottai	*P. vannamei*	31	Negative	Negative
40	P-40	13.03.2018	Mumpalai	Pudukkottai	*P. vannamei*	47	Negative	Negative
41	P-41	03.04.2018	Thoothukudi	Thoothukudi	*P. vannamei*	21	Negative	Negative
42	P-42	04.04.18	Paravai	Nagapattinam	*P. vannamei*	25	Negative	Negative
43	P-43	04.04.18	Paravai	Nagapattinam	*P. vannamei*	25	Negative	Negative
44	P-44	04.04.18	Paravai	Nagapattinam	*P. vannamei*	31	Negative	Negative
45	P-45	04.04.18	Paravai	Nagapattinam	*P. vannamei*	31	Negative	Negative
46	P-46	04.04.18	Paravai	Nagapattinam	*P. vannamei*	34	Negative	Negative
47	P-47	04.04.18	Paravai	Nagapattinam	*P. vannamei*	34	Negative	Positive
48	P-48	04.04.18	Vanjore	Nagapattinam	*P. vannamei*	34	Negative	Negative
49	P-49	04.04.18	Vanjore	Nagapattinam	*P. vannamei*	34	Negative	Negative
50	P-50	04.04.18	Vanjore	Nagapattinam	*P. vannamei*	34	Negative	Negative
51	P-51	04.04.18	Vanjore	Nagapattinam	*P. vannamei*	34	Negative	Negative
52	P-52	19.04.18	kottaipattinam	Pudukkottai	*P. vannamei*	50	Negative	Negative
53	P-53	19.04.18	kottaipattinam	Pudukkottai	*P. vannamei*	50	Negative	Positive
54	P-54	19.04.18	kottaipattinam	Pudukkottai	*P. vannamei*	50	Negative	Positive
55	P-55	19.04.18	kottaipattinam	Pudukkottai	*P. vannamei*	50	Negative	Negative
56	P-56	19.04.18	sambaipattinam	Thanjore	*P. vannamei*	40	Negative	Negative
57	P-57	19.04.18	sambaipattinam	Thanjore	*P. vannamei*	40	Negative	Positive
58	P-58	19.04.18	sambaipattinam	Thanjore	*P. vannamei*	18	Negative	Negative
59	P-59	19.04.18	sambaipattinam	Thanjore	*P. vannamei*	18	Negative	Negative
60	P-60	26.04.18	thethakudi north	Nagapattinam	*P. vannamei*	40	Negative	Positive
61	P-61	26.04.18	thethakudi north	Nagapattinam	*P. vannamei*	40	Negative	Positive
62	P-62	26.04.18	thethakudi north	Nagapattinam	*P. vannamei*	40	Negative	Negative
63	P-63	26.04.18	thethakudi north	Nagapattinam	*P. vannamei*	37	Negative	Positive
64	P-64	26.04.18	avarikadu	Nagapattinam	*P. vannamei*	36	Negative	Negative
65	P-65	26.04.18	avarikadu	Nagapattinam	*P. Monodon*	36	Negative	Negative
66	P-66	26.04.18	avarikadu	Nagapattinam	*P. Monodon*	39	Negative	Negative
67	P-67	26.04.18	pushpavanam	Tanjore	*P. vannamei*	70	Positive	Positive
68	P-68	26.04.18	pushpavanam	Tanjore	*P. vannamei*	45	Positive	Positive
69	P-69	26.04.18	pushpavanam	Tanjore	*P. vannamei*	45	Negative	Negative
70	P-70	09.05.18	Vepalodai	Thoothukudi	*P. vannamei*	60	Negative	Positive
71	P-71	09.05.18	Vepalodai	Thoothukudi	*P. vannamei*	60	Negative	Negative

72	P-72	09.05.18	Vepalodai	Thoothukudi	*P. vannamei*	59	Positive	Positive
73	P-73	09.05.18	Vepalodai	Thoothukudi	*P. vannamei*	59	Negative	Negative

3. Results

3.1 Prevalence of EHP

From the sampling study it was observed that the overall prevalence of EHP was36.98% from the 73 samples collected. Prevalence of EHP was found more in Nagapattinam (29.6%) and Thoothukudi (29.62%) followed by Pudukottai (25.92%) and Thanjavur (14.81%) districts (Figure 2). There is no prevalence of EHP from the samples collected from Ramanathapuram district. The temporal analysis for prevalence of EHP showed that summer crops were mostly infected (Figure 3). During the sampling study, the combined infection of both WSSV and EHP were not predominant and only one sample collected from Nagapattinam at 120 DOC showed combined infection of both EHP and WSSV. The details of the samples collected is given in the Table 2.

Table 2: Details of the samples analysed for EHP

S. No	RESULT	
1	Total number of samples collected	73
2	Total number of single step positive samples	14
3	Total number of nested step positive samples	13
4	Total number of positive samples	27

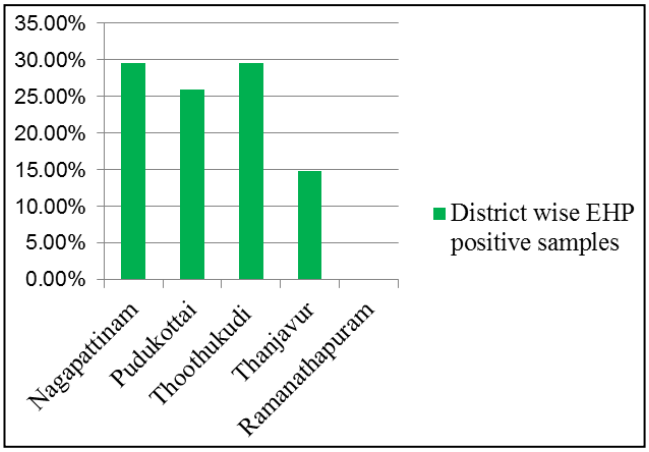

Fig 2: District wise prevalence of EHP. The above figure shows that the highest positive samples were obtained from Nagapattinam and Thoothukudi followed by Pudukottai and Thanjavur, and with no positive samples at Ramanathapuram.

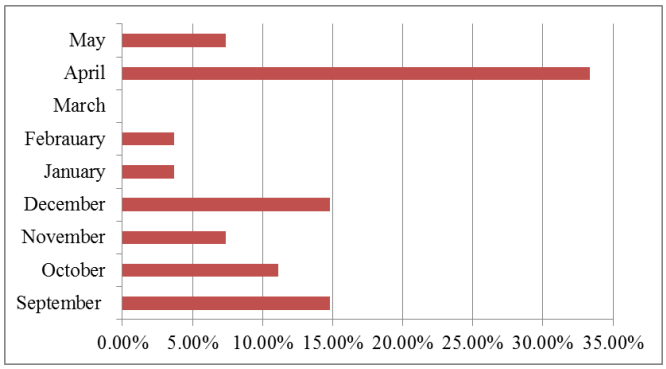

Fig 3: Month wise EHP positive samples (Sep 2017- May 2018). The above graph shows that the summer crops are mostly infected than the winter crops.

3.2 Correlation of the EHP infection with DOC

From the samples collected, the DOC of the infected samples started from a minimum of 27 to a maximum of 135. This data indicate that the EHP infects shrimps irrespective of their size and weight. The maximum range of infection with EHP with respect to DOC was found between 31 to 60 DOC of the shrimp samples (Fig 4). However, the infection range was minimum between 10 to 20 DOC. This DOC data indicates that the nursery phase samples are less prone to EHP infection than the grow out phase samples of shrimp.

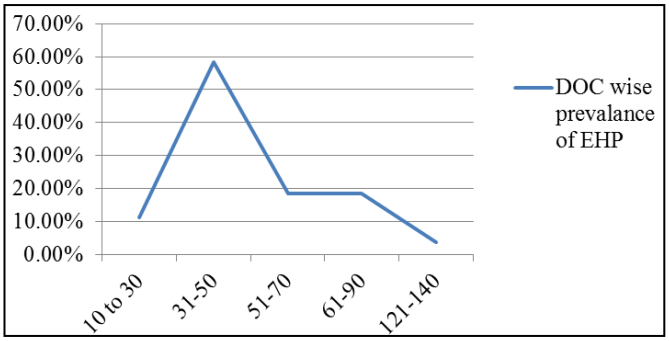

Fig 4: DOC wise prevalence of EHP

4. Discussion

The occurrence of hepatopancreatic microsporidiosis associated with EHP infection has been reported in various shrimp farming countries like Malaysia, Australia, Thailand, Vietnam, China, and Venezuela [1, 9, 4, 7, 12, 19]. The first report on prevalence of EHP causing hepatopancreatic microsporidiosis (HPM) in India was reported in 2016 [14]. Thus EHP might be an endemic pathogen in the Australasian region [22]. The first report on ultrastructural features and a partial SSU rRNA gene sequence of a microsporidian infecting hepatopancreatic tubule epithelial cells of the black tiger shrimp *P. monodon* was reported in the year 2009 [22]. *Agmasoma penaei* is the only other microsporidian described from *penaeid* shrimp in Thailand [13] that causes infections in muscle and connective tissue. *A. penaei* is distantly related to EHP since SSU rRNA sequence of *A. penaei* shared only 71% identity with that of *E. hepatopenaei* [13]. In India, EHP associated with white faeces (WFS) has caused severe production losses to the shrimp farmers. Although the shrimp farmers are well focused on the occurrence of WSSV in shrimp farms, only less importance was given to parasitic diseases due to less incidence of the parasitic disease. Recent outbreak of hepatopancreatic microsporidiosis in shrimp warrants the researchers to pay attention towards the parasitic infections.

In 2016 a sampling study has been carried out covering 3 farms at south east coast of India. The sampling showed relatively high prevalence of EHP infection (63.5%), as revealed by the nested PCR result [14]. A subsequent sampling study has been carried out in the states of Tamil Nadu, Andhra Pradesh and Orissa. The samping study covered about 235 ponds which has reported growth retardation in shrimps. Among the samples collected 59 (25%) were identified to be PCR-positive for EHP, and 155 (66%) were identified to be nested PCR-positive for EHP. This report confirmed the prevalence of EHP in the states of Tamil Nadu (North), Andhra Pradesh and Orissa [3]. In our study, sampling was carried out to assess the occurrence of EHP in South Tamil Nadu. The study indicated the occurrence of EHP in almost every district except Ramanathapuram where sampling was

carried out. Further, EHP infected samples showed growth variation in size and weight. The current study showed high prevalence of EHP in South Tamil Nadu accounting 36.98% of the shrimp farm in the district covered Nagapattinam, Ramanathapuram, Thanjavur, Pudukkottai and Thoothukudi. Even though hepatopancreatic microsporidiosis does not cause mortality, it is seriously associated with growth retardation in *P. vannamei* [21] there by affecting the production and profits in commercial shrimp farming.

The diagnosis of EHP is difficult since even the mature spores may not be visible in histology [20]. Hence molecular diagnostic assay proves to be the reliable tool for the diagnosis of EHP in shrimp samples. The molecular diagnostic assay developed earlier targeted only the 18s r RNA of EHP. However it was reported that 18s rRNA primers of EHP may have cross reactivity with other closely related microsporidia such as *Enterospora canceri* infecting crabs. Hence there is a need for more specific diagnostic assay for the screening of EHP. A more specific primer that targets the spore wall protein gene of EHP was developed [10]. This method was more specific and 100 times more sensitive than other 18s rRNA primers and did not produce any false positive results as in the case of 18s rRNA primers [10]. We have checked the reliability of primer used in this study by using spore wall protein primers [10] for the randomly selected EHP positive samples and all the positive samples checked gave positive results for the SWP primers.

Vibrios are the normal inhabitants of the healthy aquatic ecosystems. However their balance dynamically changes depending upon the inputs and outputs of nutrients and other bacteria. Earlier studies indicated that the mean value of occurrence of various *Vibrio* sp in water, sediment and shrimp samples from multiple shrimp farm environments was relatively higher in west coast farms (4.73 ± 4.69 (S.E)$\times 10^4$ cfu/ml) when compared to the east coast (5.48 ± 3.43 (S.E)$\times 10^2$ cfu/ml) [6]. Under this study the average *Vibrio* sp count of the EHP infected sample for water is 5.083×10^3 cfu/ml and soil is 5.62×10^3 cfu/g, whereas the uninfected samples shows an average *Vibrio* sp count of 6.33×10^3 cfu/ml and 3.23×10^4 cfu/g in water and soil respectively. This study reveals that the average *Vibrio* sp count is relatively low in EHP infected ponds than the uninfected EHP ponds (Fig 5). This may be due to the competition existing between the EHP microsporidian and the *Vibrio sp* which needs a further detailed study.

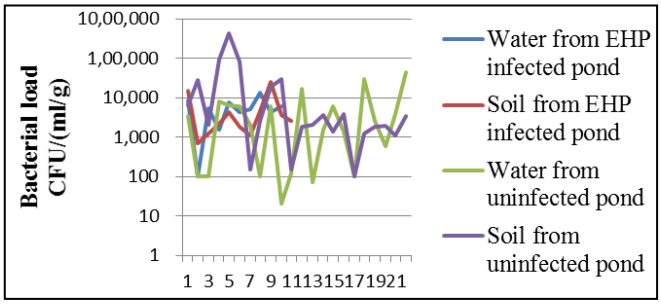

Fig 5: *Vibrio* sp count in EHP infected and uninfected water and soil samples.

The above figure shows the average *Vibrio* sp count of the EHP infected sample (for water 5.083×10^3 cfu/ml and soil 5.62×10^3 cfu/g) and the uninfected samples (for water 6.33×10^3 cfu/ml and soil 3.23×10^4 cfu/ml).

5. Conclusion

The current study determined the prevalence of EHP in one third of the shrimp farming ponds in South Tamil Nadu (Nagapattinam (29.6%) and Thoothukudi (29.62%) followed by Pudukottai (25.92%) and Thanjavur (14.81%)). Growth retardation caused by EHP is highly economically limiting and therefore merit more attention for early detection and control. Although the shrimp farmers are well focused on the occurrence of WSSV in shrimp farms, only less importance was given to parasitic diseases due to less incidence of the parasitic disease so far. Therefore this study indicates the need of strong biosecurity measures and chemotheraupaeutic measures that need to be seriously undertaken to keep this microsporidian disease EHP under control.

6. Acknowledgements

We acknowledge DBT-BBSRC Indo – UK Project on Novel Molecular Approaches for Advancing Prediction and Mitigation of Disease Outbreaks in Aquaculture for Small – scale Farmers" (Sc. No. 14- 120-01) for providing fund for this study.

7. References

1. Anderson IG, Shariff M, Nash G. A hepatopancreatic microsporidian in pond-reared tiger shrimp, *Penaeus monodon*, from Malaysia. Journal of Invertebrate Pathology. 1989; 53(2):278-280.
2. Aranguren LF, Han JE, Tang KF. *Enterocytozoon hepatopenaei* (EHP) is a risk factor for acute hepatopancreatic necrosis disease (AHPND) and septic hepatopancreatic necrosis (SHPN) in the Pacific white shrimp *Penaeus vannamei*. Aquaculture. 2017; 471:37-42.
3. Biju N, Sathiyaraj G, Raj M, Shanmugam V, Baskaran B, Govindan U *et al*. High prevalence of *Enterocytozoon hepatopenaei* in shrimps *Penaeus monodon* and *Litopenaeus vannamei* sampled from slow growth ponds in India. Diseases of aquatic organisms. 2016; 120(3):225-230.
4. Chayaburakul K, Nash G, Pratanpipat P, Sriurairatana S, Withyachumnarnkul B. Multiple pathogens found in growth-retarded black tiger shrimp *Penaeus monodon* cultivated in Thailand. Diseases of aquatic organisms. 2004; 60(2):89-96.
5. Desportes I, Charpentier YL, Galian A, Bernard F, Cochand-Priollet B, Lavergne A *et al*. Occurrence of a new microsporidan: *Enterocytozoon bieneusi* ng, n. sp., in the enterocytes of a human patient with AIDS. Journal of Eukaryotic Microbiology. 1985; 32(2):250-254.
6. Gopal S, Otta SK, Kumar S, Karunasagar I, Nishibuchi M, Karunasagar I. The occurrence of *Vibrio* species in tropical shrimp culture environments; implications for food safety. International Journal of food microbiology. 2005; 102(2):151-159.
7. Ha NTH, Ha DT, Thuy NT, Lien VTK. *Enterocytozoon hepatopenaei* has been detected parasitizing tiger shrimp (*Penaeus monodon*) cultured in Vietnam and showing white feces syndrome. Agriculture and Rural Development: Science and Technology. 2010; 12:45-50.
8. Hirt RP, Logsdon JM, Healy B, Dorey MW, Doolittle WF, Embley TM. Microsporidia are related to Fungi: evidence from the largest subunit of RNA polymerase II and other proteins. Proceedings of the National Academy of Sciences. 1999; 96(2):580-585.

9. Hudson DA, Hudson NB, Pyecroft SB. Mortalities of *Penaeus japonicus* prawns associated with microsporidian infection. Australian Veterinary Journal. 2001; 79:504-505.
10. Jaroenlak P, Sanguanrut P, Williams BA, Stentiford GD, Flegel TW, Sritunyalucksana K *et al*. A nested PCR assay to avoid false positive detection of the microsporidian *Enterocytozoon hepatopenaei* (EHP) in environmental samples in shrimp farms. PloS one. 2016; 11(11):0166320.
11. Kumaran M, Anand PR, Kumar JA, Ravisankar T, Paul J, Vimala DD *et al*. Is Pacific white shrimp (*Penaeus vannamei*) farming in India is technically efficient?-A comprehensive study. Aquaculture. 2017; 468:262-270.
12. Liu Z, Zhang QL, Wan XY, Huang J. Development of real-time PCR assay for detection of microsporidian *Enterocytozoon hepatopenaei* and detection in shrimp samples under different growth rates. Progress in Fishery Science (in press, in Chinese, English Abstract), 2015.
13. Pasharawipas T, Flegel TW, Chaiyaroj S, Mongkolsuk S, Sirisinha S. Comparison of amplified RNA gene sequences from microsporidian parasites (*Agmasoma* or *Thelohania*) in *Penaeus merguiensis* and *P. monodon*. Asian Fisheries Science. 1994; 7:169-178.
14. Rajendran KV, Shivam S, Praveena PE, Rajan JJS, Kumar TS, Avunje S *et al*. Emergence of *Enterocytozoon hepatopenaei* (EHP) in farmed *Penaeus (Litopenaeus) vannamei* in India. Aquaculture. 2016; 454:272-280.
15. Sathish Kumar T, Navaneeth Krishnan A, Joseph Sahaya Rajan J, Makesh M, Jithendran KP, Alavandi S *et al*. Visual loop-mediated isothermal amplification (LAMP) for the rapid diagnosis of *Enterocytozoon hepatopenaei* (EHP) infection. Parasitology Research. 2018; 117(5):1485-1493.
16. Sritunyalucksana K, Sanguanrut P, Salachan PV, Thitamadee S, Flegel TW. Urgent appeal to control spread of the shrimp microsporidian parasite *Enterocytozoon hepatopenaei* (EHP). Network of Aquaculture Centres in Asia-Pacific (NACA), 2015, 4-6.
17. Suebsing R, Prombun P, Srisala J, Kiatpathomchai W. Loop-mediated isothermal amplification combined with colorimetric nanogold for detection of the microsporidian *Enterocytozoon hepatopenaei* in penaeid shrimp. Journal of Applied Microbiology. 2013; 114(5):1254-1263.
18. Tang KF, Pantoja CR, Redman RM, Han JE, Tran LH, Lightner DV. Development of in situ hybridization and PCR assays for the detection of *Enterocytozoon hepatopenaei* (EHP), a microsporidian parasite infecting penaeid shrimp. Journal of invertebrate pathology. 2015; 130:37-41.
19. Tang KF, Aranguren LF, Piamsomboon P, Han JE, Maskaykina IY, Schmidt MM. Detection of the microsporidian *Enterocytozoon hepatopenaei* (EHP) and Taura syndrome virus in *Penaeus vannamei* cultured in Venezuela. Aquaculture. 2017; 480:17-21.
20. Tangprasittipap A, Srisala J, Chouwdee S, Somboon M, Chuchird N, Limsuwan C *et al*. The microsporidian *Enterocytozoon hepatopenaei* is not the cause of white feces syndrome in whiteleg shrimp *Penaeus (Litopenaeus) vannamei*. BMC veterinary research. 2013; 9(1):139.
21. Thitamadee S, Prachumwat A, Srisala J, Jaroenlak P, Salachan PV, Sritunyalucksana K *et al*. Review of current disease threats for cultivated penaeid shrimp in Asia. Aquaculture. 2016; 452:69-87.
22. Tourtip S, Wongtripop S, Stentiford GD, Bateman KS, Sriurairatana S, Chavadej J *et al*. *Enterocytozoon hepatopenaei* sp. Nov. (Microsporida: *Enterocytozoonidae*), a parasite of the black tiger shrimp *Penaeus monodon* (Decapoda: *Penaeidae*): Fine structure and phylogenetic relationships. Journal of invertebrate pathology. 2009; 102(1):21-29.
23. http://www.fao.org/3/a-i7546e.pdf