Journal of Entomology and Zoology Studies

Available online at www.entomoljournal.com

E-ISSN: 2320-7078
P-ISSN: 2349-6800
www.entomoljournal.com
JEZS 2020; 8(3): 589-596

Received: 28-03-2020
Accepted: 30-04-2020

T Rajendrakumar
Department of Veterinary Pathology, Veterinary College, KVAFSU, Nandinagar, Bidar, Karnataka, India

Suguna Rao
Department of Veterinary Pathology, Veterinary College, KVAFSU, Hebbal, Bangalore, Karnataka, India

ML Satyanarayana
Department of Veterinary Pathology, Veterinary College, KVAFSU, Hebbal, Bangalore, Karnataka, India

HD Narayanaswamy
Department of Veterinary Pathology, Veterinary College, KVAFSU, Hebbal, Bangalore, Karnataka, India

SM Byregowda
Institute of Animal Health and Veterinary Biological, KVAFSU, Bangalore, Karnataka, India

Corresponding Author:
T Rajendrakumar
Department of Veterinary Pathology, Veterinary College, KVAFSU, Nandinagar, Bidar, Karnataka, India

Effect of *Andrographis paniculata* on cisplatin induced renal histopathology in Wistar albino rats

T Rajendrakumar, Suguna Rao, ML Satyanarayana, HD Narayanaswamy and SM Byregowda

Abstract
The role of ethanolic extract of *Andrographis paniculata* [AP], in preventing cisplatin [CP] induced histopathological changes in renal tissue was evaluated in 60 Wistar albino rats. Five equal-sized groups of rats were used as control**,** recipient of CP alone, recipient of AP alone, pre recipient of AP for 15 days prior to CP and concurrent treatment of AP with CP. CP was administered at 7.5 mg/kg body weight intraperitoneally for single dose. AP was at the dose of 500mg/kg body weight by oral gavaging for 45 days. Histopathological examination of kidney was carried out on 7th, 14th, 28th and 45th day. Results documented that, CP produced severe congestion of tubular vessels, vacuolar degeneration, necrosis, apoptosis of renal cells, distension of the tubules and inflammatory cell infiltration. The AP treatment groups revealed improvement in the kidney architecture, while pretreatment of AP produced the much earlier amelioration of the pathological changes. The study indicated that, prior administration of AP inhibited the CP induced kidney injury and has good prophylactic effect.

Keywords: *Andrographis paniculata*, cisplatin, histopathology, necrosis, apoptosis

1. Introduction
Nephrotoxicity is one of the major kidney problems caused by drugs, diagnostic agents, chemical reagents and heavy metals [1]. One such platinum chemotherapeutic drug is the cisplatin and used in variety of malignancies. It kills malignant cells in all stages of life cycle and hinders DNA synthesis and function through binding to DNA via formation of interstand and intrastand crosslinks [2]. Unfortunately, cisplatin administration was associated with numerous side effects including nephrotoxicity, hepatotoxicity, myelosuppression, neurotoxicity and ototoxicity [3]. Of these, most clinically significant and common toxicity is nephrotoxicity. The mechanism for cisplatin induced nephrotoxicity is not sufficiently understand, but appears to involve inflammation, oxidative stress and apoptosis [4]. The clinical usefulness of CP has been limited because of the nephrotoxic effect. Therefore, alleviating the nephrotoxic effect of CP without inhibiting its antitumor effects, in different experiments were carried out with radical scavengers and natural foods with antioxidant properties [5]. In the recent years, traditional medicine using herbal plants is considered as best therapeutic for renal failure than conventional method.
Recently, several studies suggested that, combined chemotherapy with CP and plant extracts can reduce the side effects and enhance the antitumor efficacy [6]. One such plant is *Andrographis paniculata* (AP) commonly known as Kalmegh, native of India and China has been used for years in herbal medicine [7]. AP contains, therapeutically active principles like andrographalide, neoandrographalide, deoxyandrographalide and didehydroandrographalide[8]. AP has a broad range of pharmacological effects including anticancer, antihepatitis, anti-inflammatory, antioxidant, antimicrobial, antimalarial and immunomodulatory effects [9]. AP is locally and commonly available plant in India and the leaves were used for renoprotective action [10]. Thus, the aim of the present work to study the effect of CP on renal tissue of rat histologically and on other hand to investigate the role of AP in experimentally induced nephrotoxicity.

2. Materials and Methods
2.1 Drugs and chemicals: Cisplatin [Kemoplat] was procured from Fresenius Kabi India Pvt. Ltd. Pune, India. and the ethanolic extract of *Andrographis paniculata* was obtained from Himalaya Herbal Pvt Ltd. Bangalore, India.

2.2 Animals: Sixty normal adult Wistar albino rats weighing approximately 180-200 grams were procured from commercial animal facility, Bangalore for the study. They were maintained under standard laboratory conditions and fed with *ad libitum* standard commercial rat feed and clean drinking water. The duration of experiment was for a period of 45 days and a prior permission was obtained from the Institutional Animal Ethics Committee [IAEC] for the conduct of the experiment (VCH/IAEC/2016/24 dated 29.12.2016).

2.3 Experimental design: The rats were maintained under standard laboratory conditions for a period of 15 days for acclimatization in the experimental animal house. The rats were divided into five groups with twelve rats in each group.

Group I: Negative control - injected with 0.5ml sterile PBS intraperitoneally on Day 1 and gavaged with PBS daily.

Group II: Positive control- nephrotoxicity induced with administration of cisplatin at 7.5mg/kg body weight intraperitoneally for single dose.

Group III: *Andrographis paniculata* control-animals supplemented with ethanolic extract of *Andrographis paniculata* alone at the dose rate of 500 mg/kg body weight.

Group IV: Supplemented with *Andrographis paniculata* extract at the dose rate of 500mg/kg bodyweight 15 days prior to induction of nephrotoxicity by CP.

Group V: Supplemented with *Andrographis paniculata* extract at the dose rate of 500mg/kg bodyweight concurrently with the administration of CP.

2.4 Histopathology: To study the progressive effects of the treatments given to different groups, rats from each group were sacrificed humanely under ketamine hydrochloride on 7th, 14th, 28th and 45th day of post induction of nephrotoxicity. Further, the representative kidney tissues samples of 3-5 mm thickness were collected and preserved in 10 per cent neutral buffered formalin for 48hrs and the tissues were processed by the routine paraffin embedding technique and sections of 4 µ thickness were cut using a microtome and subjected to routine hematoxylin and eosin (H&E) staining [11].

3. Results

3.1 Normal control group (Group I) and AP control group (Group III): The kidney showed apparently normal microscopical architecture throughout the study period (Fig. 1, 2).

3.2 Cisplatin control group (Group II): In kidney, the cisplatin induced injury was observed mainly in the tubules of corticomedullary junction involving proximal convoluted tubules primarily and also distal tubules (Fig. 3). On 7th day of the experiment, revealed moderate to severe congestion of glomerular capillaries and inter tubular vessels in both cortex and medulla (Fig. 4). Some of the glomeruli were atrophied with reduction in glomerular tuft and increase in Bowman's space. The tubular changes were appreciable in the tubules of distal cortical and corticomedullary junction. Varying degenerative and necrotic changes were observed in many tubules which included lining epithelial cell swelling, severe vacuolar degeneration and necrosis of cells with desquamation (Fig. 5). The tubules that showed necrosis, contained granular eosinophilic material with scattered pyknotic nuclei in the lumen (Fig. 6). Several tubules also showed a number of cells with apoptotic morphological characteristics along with necrotic cells. The apoptotic cells lining the tubules appeared highly eosinophilic with condensed nuclei. Some cells also showed fragmentation and irregular chromatin condensation.

On 14th day, there was a reduction in the severity of congestion. The various microscopical changes observed in the kidney were similar to those observed on 7th day. There was an increase in the number of tubules affected in the corticomedullary junction. Most of the tubules appeared distended with total absence of lining cells (Fig. 7). A few tubules showed eosinophilic necrotic debris with nuclear remnants. Some also showed presence of apoptotic cells. Glomeruli and upper cortical proximal tubules appeared normal. There was also a mild infiltration of mononuclear inflammatory cells in the interstitium (Fig. 8) as well as into the lumen of the tubules. On 28th day of the experiment, persistence of moderate degree of congestion was observed. There was a progression in the severity of the tubular lesions which included dilation of large number of tubules with lesions similar to those observed on 14th day. However, in several tubules, loss of basement membrane was observed along with total tubular necrosis. In addition, presence of apoptotic cells and few tubules under regeneration were also observed. On 45th day, there was total reduction in congestion and was characterized by regeneration and fibrosis of the affected areas (Fig. 9, 10). However, in some rats there was persistence of cisplatin induced tubular injury along with regeneration of tubules. In addition, mineralization was also observed.

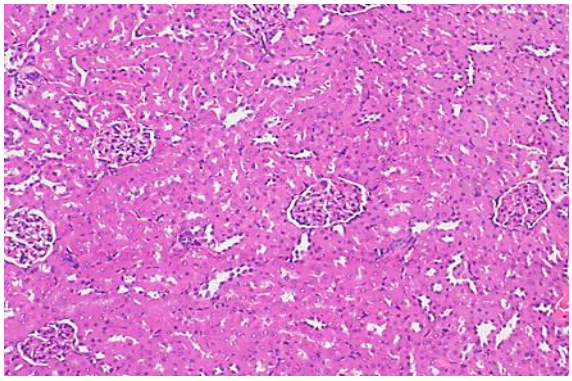

Fig 1: Kidney from Group I showing normal architecture at 7th day of the experiment. H&E ×100

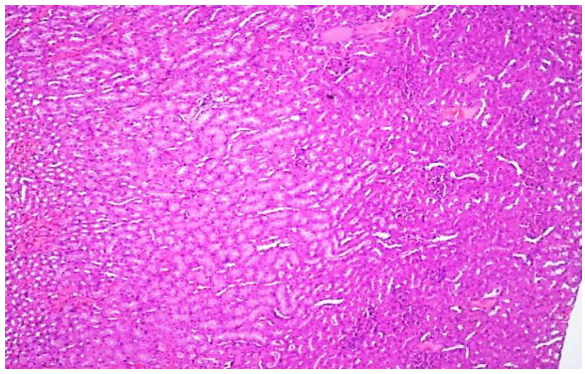

Fig 2: Section of kidney from negative control rat (Group I) showing normal appearance of the kidney. H&E ×40

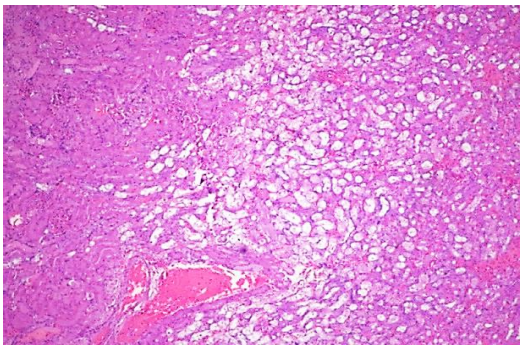

Fig 3: kidney from Group II rat showing severe degenerative and necrotic changes involving tubules of corticomedullary junction. H&E ×40

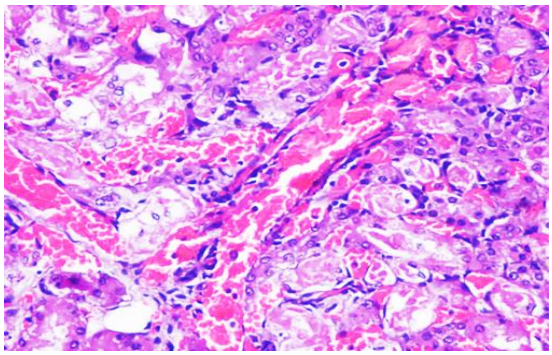

Fig 4: Section of kidney from a Group II rat at 7th day showing severe congestion of the intertubular vessels and degeneration and necrosis of tubular epithelial cells. H&E ×200

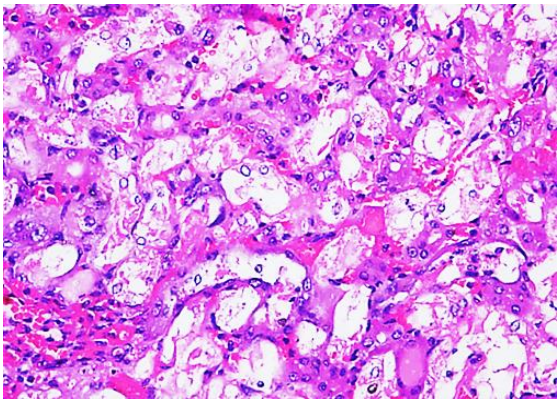

Fig 5: Section of kidney from a Group II rat at 7th day showing severe degeneration and necrosis of renal tubules. H&E ×200

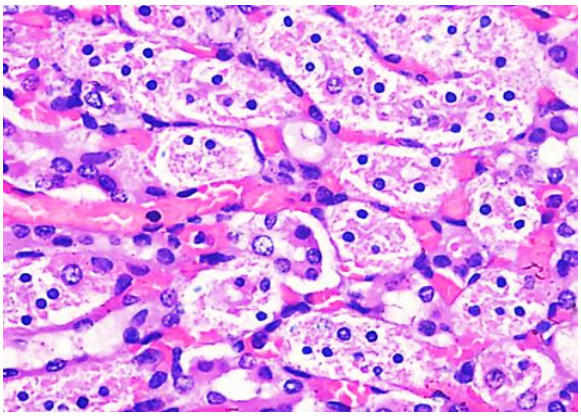

Fig 6: Section of kidney from a Group II rat at 7th day showing congestion and eosinophilic granular necrotic material with scattered pyknotic nuclei in the lumen of affected renal tubules. H&E ×400

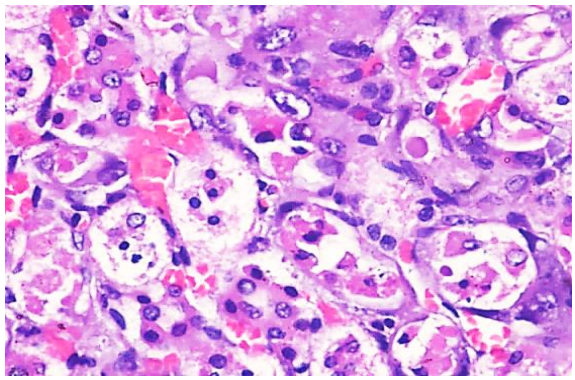

Fig 7: Section of kidney from a Group II rat at 14th day showing necrotic renal tubules with desquamated cells in the lumen. H&E ×400

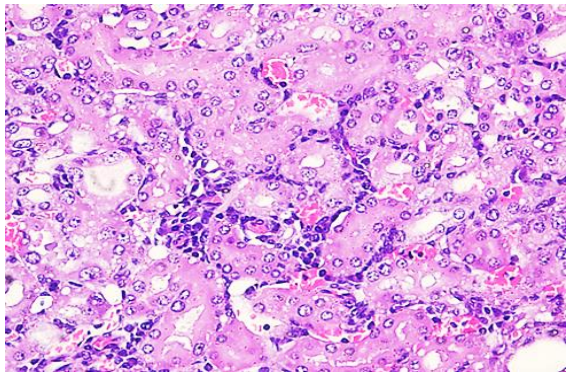

Fig 8: Section of kidney from a Group II rat at 14th day showing interstitial mononuclear infiltration. H&E ×200

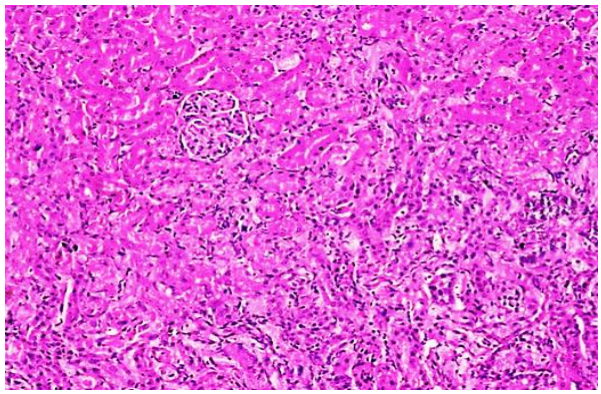

Fig 9: Section of kidney from a Group II rat at 45th day showing fibrosis and occasional regenerating tubules in the distal cortex region. H&E ×100

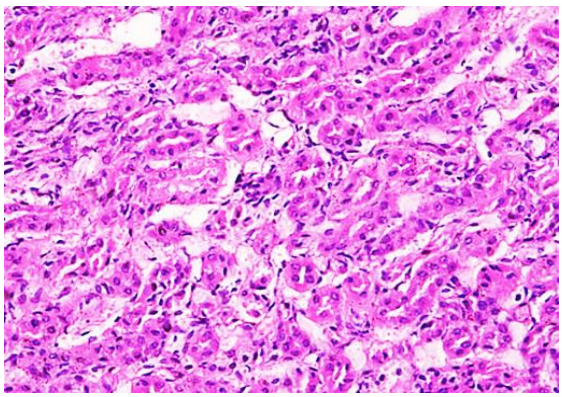

Fig 10: Section of kidney from a Group II rat at 45th day showing fibrosis and regenerating newly formed renal tubules lined by cuboidal epithelial cells without lumen formation. H&E ×200

3.3 *Andrographis paniculata* pre-treatment group (Group IV): Microscopically on day 7th, there was mild congestion of vessels in the kidney. Majority of the tubules appeared normal in the architecture with only occasional tubules showed vacuolar degeneration (Fig. 11). Some of the tubules at the corticomedullary junction revealed distension with flattened or low cuboidal lining epithelial cells. Occasional lining cells showed apoptosis. There was infiltration of mononuclear cells in large number in the interstitial space. On 14th day, also there was mild degree of congestion and majority of the tubules at corticomedullary junction appeared normal in architecture with regenerated tubules (Fig. 12). Occasional tubules revealed vacuolar degeneration, necrosis, desquamation, presence of apoptotic cells and eosinophilic proteinaceous material in the lumen. Infiltration of large number of mononuclear cells was observed in the interstitium (Fig. 13) along with mild fibrous connective tissue proliferation. On 28th day, the corticomedullary junction showed presence of numerous regenerated tubules (Fig. 14) along with infiltration of inflammatory cells and mild fibrous connective tissue proliferation in the interstitium. The regenerating tubules were lined by cuboidal epithelial cells and were more basophilic. The adjacent tubules appeared either normal or showed atrophic changes with pyknotic nuclei and eosinophilic cytoplasm. On 45th day there was persistence of the similar changes in the kidney of those observed on 28th day

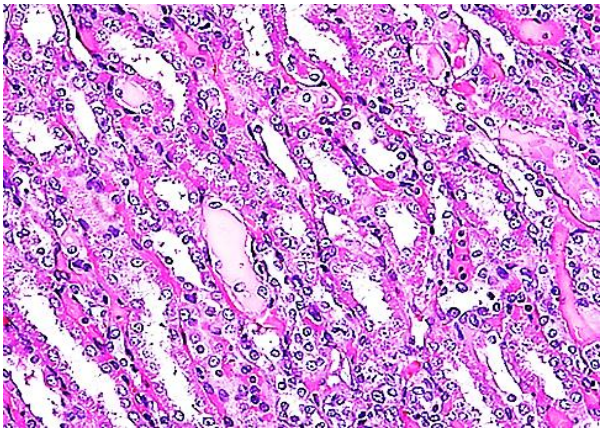

Fig 11: Section of kidney from a Group IV rat at 7th day showing affection of renal tubules with mild degeneration and necrotic changes. Lumen of occasional tubules are showing presence of eosinophilic hyaline cast. H&E ×200

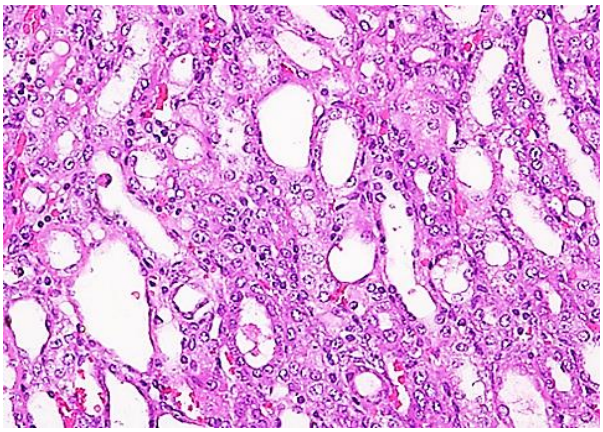

Fig 12: Section of kidney from a Group IV rat at 14th day showing mild affection of kidney with occasional tubules dilated cystically lined by flattened renal tubular cells.H&E ×200

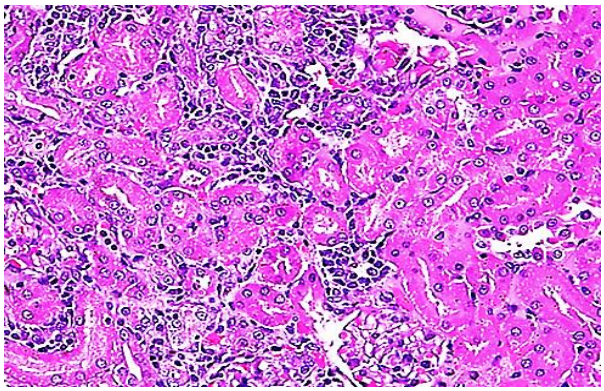

Fig 13: Section of kidney from a Group IV rat at 14th day showing infiltration of large number of mononuclear cells in the interstitium. Note almost normal appearance of adjacent renal tubules.

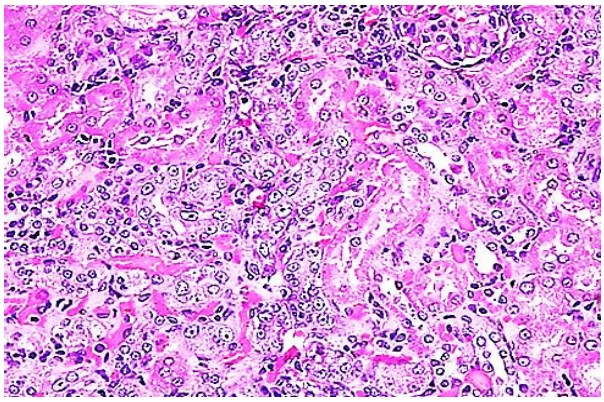

Fig 14: Section of kidney from Group IV rat at 28th day showing numerous regenerated tubules along with degenerated and necrotic adjacent tubules.H&E ×200

3.4 *Andrographis paniculata* concurrent treatment group (Group V): On 7th day, the microscopical changes observed in the kidney were similar to those observed in the cisplatin control group (Group II) which included moderate degree of congestion, tubular degeneration and necrosis restricted to the tubules of corticomedullary junction (Fig. 15), total desquamation of cells into the lumen with or without retained basement membrane, presence of apoptotic cells and mild infiltration of mononuclear cells in the interstitial space. Additionally, there was multifocal mineralization involving necrotic tubules (Fig. 16). On 14th day, there was an appreciable reduction in the degree of congestion. There was persistence of tubular changes and were similar to those observed on 7th day, however, in a reduced intensity. The affected areas showed regeneration of large number of tubules lined by either flattened or low cuboidal epithelial cells. On 28th day also, there was persistence of low grade of tubular injury and mild to moderate degree of congestion. Most of the tubules in the affected area revealed regeneration with flattened, low cuboidal or cuboidal lining epithelial cells (Fig. 17). Many of the tubules also showed infiltration of macrophages into the lumen. However, occasional tubules showed degenerative and necrotic changes. On 45th day, there was an appreciable reduction in the severity of congestion and tubular changes. Majority of the tubules revealed regeneration and lined by low cuboidal to cuboidal epithelial cells (Fig. 18). However, there was also persistence of tubules that were distended, consisting of eosinophilic homogenous material. There was infiltration of mononuclear cells and mild connective tissue proliferation interstitially with macrophages in the lumen of some of the tubules.

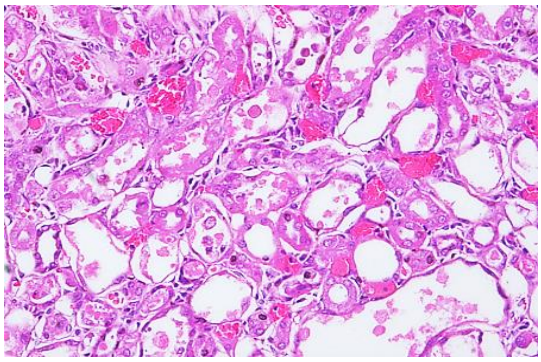

Fig 15: Section of kidney from a Group V rat at 7th day showing congestion and severely dilated tubules with flattened lining cells. Note necrotic debris in the lumen. H&E ×100

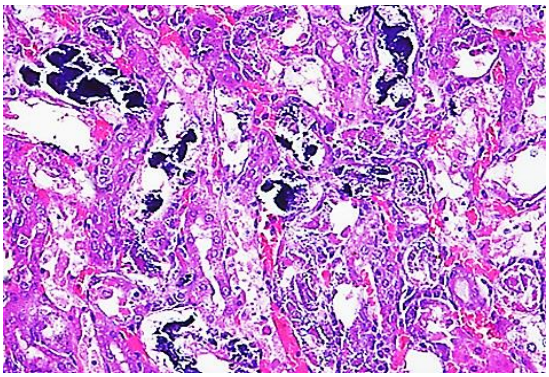

Fig 16: Section of kidney from a Group V rat at 7th day showing multifocal mineralization involving necrotic tubules. H&E ×100

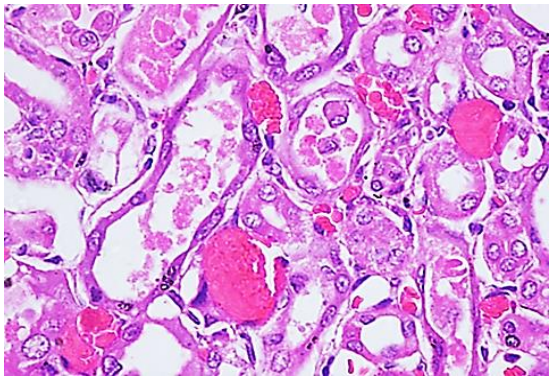

Fig 17: Section of kidney from a Group V rat at 28th day showing occasional intertubular vessel congestion, distended tubules lined by flattened low cuboidal epithelial cells. Also note necrotic debris and desquamated cells in the lumen of tubules. H&E ×400

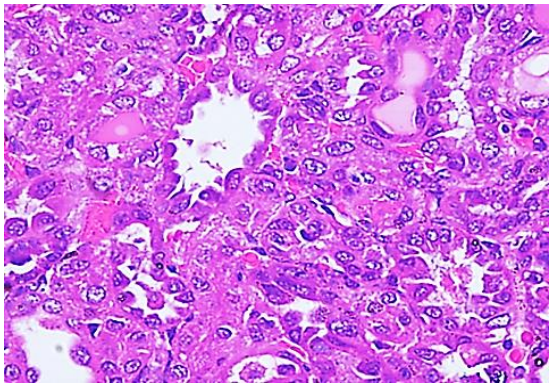

Fig 18: Section of kidney from a Group V rat at 45th day showing regenerating tubules lined by low cuboidal to cuboidal epithelial cells. H&E ×400

4. Discussion

Cisplatin is an effective chemotherapeutic agent for a wide variety of tumors. The therapeutic effect of cisplatin is pointedly enhanced by dose acceleration. However, high dose therapy with CP is limited due to associated side effects such as nephrotoxicity and hepatotoxicity [5]. CP induced kidney injury is mainly attributed to higher accumulation of CP in tubular epithelial cells, oxidative stress, inflammation and apoptosis [4].

In the present study, single dose of CP (7.5mg/kg) treatment showed, severe congestion of inter tubular vessels, vacuolar degeneration and necrosis of tubular epithelial cells, apoptosis of renal cells, distension of tubules with necrotic desquamated cells during 7th day which progressed in severity on 14th and 28th day with infiltration of inflammatory cells in the interstitium. On 45th day of the study, there was regeneration and fibrosis of the affected areas along with some tubular injury. The cisplatin induced lesions were observed at corticomedullary junction mainly with upper cortex and medullary junction. Similar morphological changes in the kidneys in cisplatin toxicity have also been reported in earlier studies [12-23].

Cisplatin accumulates in greater amount in the kidney compared to any other organs and it is excreted mainly through kidney. The cisplatin concentration in the proximal tubular epithelial cells is about 5 times the serum concentration [24]. This disproportionate distribution of cisplatin in kidney tissue contributes to severe nephrotoxicity associated with cisplatin treatment [25]. In the present study, cisplatin induced severe renal damage was restricted mainly to the corticomedullary junction. Cisplatin enters renal tubular cells by passive diffusion or transporter facilitated diffusion through basolateral organic cation transporter (OCT) leading to disproportionate drug accumulation. OCT2 is expressed mainly in the S2 and S3 segments [26]. OCT2 is a critical transporter in cisplatin penetration and cytotoxicity in the proximal tubules and affects accumulation of the drug in the kidneys which could explain the drug's organ, site and cell-specific toxicity in the present study.

Extensive necrosis of the tubular epithelial cells observed in the present study could be attributed to the cytotoxic effect of the drug cisplatin. Once cisplatin is transported into the tubular cells, highest concentration of cisplatin occurs in cytosol, mitochondria, nuclei and microsomes [24]. Then cisplatin conjugates with glutathione and metabolized through Gamma glutamyl transpeptidase and a cysteine –S-conjugate beta –lyase dependent pathways to form a reactive thiol, which serves as a potent nephrotoxin. Such highly reactive cisplatin metabolite cross-links DNA and cause DNA damage along with generation of ROS leading to necrosis and apoptosis of renal tubular cells causing nephrotoxicity [26, 27]. Many earlier workers have observed increased oxidative stress in kidney tissues following cisplatin administration with increase in MDA levels and decrease in antioxidant enzymes such as SOD and GPx which clearly indicate that, oxidative stress is also an important cause of damage to renal tissue in cisplatin nephrotoxicity [4, 17, 18].

Another characteristic microscopic observation in the present study was presence of apoptotic cells in the kidney. Apoptotic cells and apoptotic bodies in cisplatin induced nephrotoxicity have been described in earlier studies [14, 15, 17]. Cisplatin, as indicated earlier, cross links the DNA in several different pathways and forms DNA adducts, causing G2 cell cycle arrest and interferes with cell division by mitosis. The

damaged DNA elicits DNA repair mechanisms, which in turn activate apoptosis when repair proves impossible [28, 29]. In addition, apoptosis in cisplatin nephrotoxicity could be due to increased oxidative stress with increased free radical injury, reduction in the mitochondrion membrane potential and proinflammatory cytokines or depletion of intracellular antioxidants [30, 31]. The increased oxidative stress may also cause structural changes in nucleus by causing DNA fragmentation and denaturation, which play a critical role in the initiation of apoptosis [32].

In the present study during 45th day extensive fibrotic change along with regenerative tubules was observed in the corticomedullary junction replacing the injured tissue. Cisplatin has been reported to induce fibrosis around the affected tubules accompanied by infiltration of macrophages and lymphocytes. The infiltrated macrophages play a role in renal interstitial fibrosis by production of fibrogenic factors TGF-beta1 and TNF alpha which mediate induction of myofibroblastic cells capable of producing extracellular matrix [33-35]. In the present study inflammatory changes were also observed in the kidney. Cisplatin has been reported to induce a series of inflammatory changes that mediate renal injury. Recent evidence indicates that inflammation has an important role in the pathogenesis of cisplatin-induced renal injury. Cisplatin increases degradation of inhibitor kappa beta (IkB) in a time-dependent manner and increases nuclear factor-kB (NF-kB) binding activity. These events lead to the enhanced renal expression of TNF-α. Other cytokines, such as transcribing growth factor-α (TGF-α), monocyte chemoattractant protein-1 (MCP-1), intercellular adhesion molecule (ICAM), hemeoxygenase-1, TNF receptor 1 (TNFR1), and TNF receptor 2 (TNFR2), are also increased in kidneys by cisplatin. TNF-α induces apoptosis, produces reactive oxygen species, and coordinates the activation of a large network of chemokines and cytokines in the kidney which attract inflammatory cells [36].

Microscopically, kidney of both the *Andrographis paniculata* treatment groups (Group IV and V) revealed restoration of almost normal architecture by 45th day of experiment. During initial period of the experiment, changes in the kidney were similar to that of cisplatin group in concurrent group (Group V). However, in the pre-treatment group (Group IV) only occasional tubules showed changes indicating protection rendered by pre-treatment of *Andrographis paniculata* against cisplatin injury. The various changes noticed in the kidney were moderate degree of congestion, tubular degeneration and necrosis restricted to the tubules of corticomedullary junction, presence of apoptotic cells and mild infiltration of mononuclear cells in the interstitial space along with mild fibrotic and regenerative changes from 14th to 28th day in the concurrent group (Group V). However, in pre-treatment group (Group IV) regeneration of the numerous tubules with mild vacuolar degeneration and necrosis of tubular cells along with interstitial infiltration were noticed. In comparison to Group V, Group IV revealed better nephroprotective and early restoration of normal architecture.

The nephroprotective effect of *Andrographis paniculata* has been well established and reported in various earlier studies against various chemical induced nephrotoxicity [10, 37-40]. Pre-treatment with leaf extracts (300mg/kg, for 10 days) of *Andrographis paniculata* significantly prevented histopathological changes in kidney induced by gentamycin in Wistar albino rats towards normalcy and this inhibitory action of *Andrographis paniculata* leaves extract against nephrotoxin is due to the presence of secondary metabolites like flavonoid and polyphenolic compounds responsible for the nephroprotective activity [38]. Andrographolide, of *Andrographis paniculata* as indicated earlier, possess antioxidant activity. Oxidative damage at the cellular level of the renal cortex by gentamicin induced free radicals was alleviated by the antioxidant and free radical-scavenging properties of *Andrographis paniculata* signifying its possible mechanism of renoprotection [37, 41]. *Andrographis paniculata* extract also can attenuate the myeloperoxidase activity, showing the anti-inflammatory effect of *Andrographis paniculata* as reported in earlier study [42]. In the present study, cisplatin induced inflammation with infiltration of macrophages and lymphocytes was reduced by *Andrographis paniculata* in both Group IV and V rats. Ethanolic extract of *Andrographis paniculata* decreased kidney injury molecule-1 (Kim-1) and increased nuclear factor erythroid 2-related factor 2 (Nrf2) expression thereby ameliorated cisplatin induced nephrotoxicity by inhibiting inflammatory and oxidative stress response [40]. Andrographolide, an active biomolecule of AP, activate the Nrf2 and this plays a predominant role in antioxidant protection against oxidative damage [43]. Once activated, Nrf2 translocate into nucleus and binds to the antioxidant responsive element located in promoter region of antioxidant and phase II enzymes, including HO-1, GSH, GPx, ROS, and glutamate cysteine ligase, etc. to enhance antioxidant capacity and restore redox homeostasis [44].

5. Conclusion

Findings of the present study concluded that, cisplatin when administered at the dose of 7.5 mg/kg induced the nephrotoxicity as evidenced by the histopathology. On the other hand, AP treatment has beneficial and responsible for nephroprotective properties. It is therefore, recommended this to be useful co-treatment for cisplatin during treatment of cancer.

6. Acknowledgment

Authors are thankful to the Head of the Department, Department of Veterinary pathology and Dean, Veterinary College, Bangalore, for providing facilities to carry out the present study.

7. References

1. Lakshmi SM, Reddy UK, Rani SRKS. A review on medicinal plants for nephroprotective activity. Asian Journal of Pharmaceutical and Clinical Research. 2012. 5(4):8-14.
2. Sweetman SC. The Complete Drug Reference. Edn Pharmaceutical Press, London. 2011; 37(9):764 -767.
3. Barabas K, Milner R, Lurie D, Adin C. Cisplatin: a review of toxicities and therapeutic applications. Veterinary and Comparative Oncology. 2008; 6(1):1-8.
4. Yao X, Panichpisal K, Kurtzman N, Nugent K. Cisplatin nephrotoxicity: a review. The American Journal of the Medical Sciences. 2007; 334(2):115-124.
5. İşeri S, Ercan F, Gedik N, Yüksel M, Alican I. Simvastatin attenuates cisplatin-induced kidney and liver damage in rats. Toxicology. 2007; 230(2, 3):256-264.
6. Kim YH, Kim YW, Oh YJ, Back NI, Chung SA, Chung HG *et al*. Protective effect of the ethanol extract of the roots of *Brassica rapa* on cisplatin-induced nephrotoxicity in LLC-PK1 cells and rats. Biological and

Pharmaceutical Bulletin. 2006; 29(12):2436-2441.
7. Akbar S. *Andrographis paniculata*: A review of pharmacological activities and clinical effects. Alternative Medicine Review. 2011; 16(1):66-77.
8. Chen LX, Qu GX, Qiu F. Studies on flavonoids of *Andrographis paniculata*. Chinese Materia Medica. 2006; 31(5):391-395.
9. Hossain MD, Urbi Z, Sule A, Rahman KM. *Andrographis paniculata* (Burm. f.) Wall. ex Nees: a review of ethnobotany, phytochemistry, and pharmacology. The Scientific World Journal, 2014.
10. Bijoy B, Meghali C. Reno-protective action of the ethanolic extracts of *Andrographis paniculata* leaves in albino rats. Indian Journal Basic Applied Medical Research. 2017; 6(2):436-446.
11. Luna LG, Manual of Histopathological Staining Methods of the Armed Forces Institute of Pathology. Edn 3, McGraw Hill Book Co., New York, 1968, 12-32.
12. Fenoglio C, Boncompagni E, Chiavarina B, Cafaggi S, Cilli M, Viale M. Morphological and histochemical evidence of the protective effect of procainamide hydrochloride on tissue damage induced by repeated administration of low doses of cisplatin. Anticancer Research. 2005; 25(6B):4123-4128.
13. Ibrahim MY, Abdul AB, Ibrahim TA, Wahab SA, Elhassan MM, Mohan S. Attenuation of cisplatin-induced nephrotoxicity in rats using zerumbone. African Journal of Biotechnology. 2010; 9(28):4434-4441.
14. Abdelgawad SK, Mohamed AA. Silymarin administration protects against cisplatin-induced nephrotoxicity in adult male albino rats (Histological and Immunohistochemical Study). Egyptian Journal of Histology. 2010; 33(4):683-691.
15. Ezz-Din D, Gabry MS, Farrag AR, Abdel Moneim AE. Physiological and histological impact of *Azadirachta indica* (neem) leaves extract in a rat model of cisplatin-induced hepato and nephrotoxicity. Journal of Medicinal Plants Research. 2011; 5(23):5499-5506.
16. Ali BH, Abdelrahman AM, Al-Salam S, Sudhadevi M, AlMahruqi AS, Al-Husseni IS *et al*. The effect of sildenafil on cisplatin nephrotoxicity in rats. Basic & Clinical Pharmacology & Toxicology. 2011; 109(4):300-308.
17. Sherif IO. Amelioration of cisplatin-induced nephrotoxicity in rats by triterpenoid saponin of *Terminalia arjuna.* Journal of Clinical Experimental Nephrology. 2015; 19(4):591-597.
18. Divya MK, Lincy L, Raghavamenon AC, Babu TD. Ameliorative effect of *Apodytes dimidiata* on cisplatin-induced nephrotoxicity in Wistar rats. Pharmaceutical Biology. 2016; 54(10):2149-2157.
19. Tohamy AA, Aref AM, Moneim AE, Sayed RH. Cinnamic acid attenuates cisplatin-induced hepatotoxicity and nephrotoxicity. Journal of Basic Environmental Sciences. 2016; 3:1-9.
20. Song Z, Chang H, Han N, Liu Z, Liu Y, Wang H *et al*. He-Wei granules (HWKL) combat cisplatin-induced nephrotoxicity and myelosuppression in rats by inhibiting oxidative stress, inflammatory cytokines and apoptosis. RSC Advances. 2017; 7(32):19794-19807.
21. Ma X, Yan L, Zhu Q, Shao F. Puerarin attenuates cisplatin-induced rat nephrotoxicity: The involvement of TLR4/NF-κB signaling pathway. PloS One. 2017; 12(2):1-15.
22. Kpemissi M, Eklu-Gadegbeku K, Veerapur VP, Negru M, Taulescu M, Chandramohan V *et al*. Nephroprotective activity of *Combretum micranthum* G. Don in cisplatin induced nephrotoxicity in rats: In vitro, in-vivo and in-silico experiments. Biomedicine & Pharmacotherapy. 2019; 116:1-14.
23. Saif-Elnasr M, Abdel-Aziz N, El-Batal AI. Ameliorative effect of selenium nanoparticles and fish oil on cisplatin and gamma irradiation-induced nephrotoxicity in male albino rats. Drug and Chemical Toxicology. 2019; 42(1):94-103.
24. Kuhlmann MK, Burkhardt G, Köhler H. Insights into potential cellular mechanisms of cisplatin nephrotoxicity and their clinical application. Nephrology, dialysis, transplantation: official publication of the European Dialysis and Transplant Association-European Renal Association. 1997; 12(12):2478-2480.
25. Arany I, Safirstein RL. Cisplatin nephrotoxicity. Seminars in Nephrology. 2003; 23(5):460-464.
26. Peres LA, da Cunha Jr AD. Acute nephrotoxicity of cisplatin: molecular mechanisms. Brazilian Journal of Nephrology. 2013; 35(4):332-340.
27. Ai D, Guan Y, Liu XJ, Zhang CF, Wang P, Liang HL *et al*. Clinical comparative investigation of efficacy and toxicity of cisplatin plus gemcitabine or plus Abraxane as first-line chemotherapy for stage III/IV non-small-cell lung cancer. Onco Targets and Therapy. 2016; 9:5693.
28. Kishimoto S, Miyazawa K, Terakawa Y, Ashikari H, Ohtani A, Fukushima S *et al*. Cytotoxicityofcis-[((1R,2R)-1,2-Cyclohexanediamine-N, N') bis (myristato)]-platinum (II) Suspended in Lipiodol in a Newly Established Cisplatin resistant Rat Hepatoma Cell Line. Japanese Journal of Cancer Research. 2000; 91(12):1326-1332.
29. Hesham AA, Ghobara MM. Histological Study of the Effect of Cisplatin on the Liver of Adult Male Albino Rat. International Journal of Academic and Scientific Research. 2013; 1(1):22-33.
30. De Bono DP, Yang WD. Exposure to low concentrations of hydrogen peroxide causes delayed endothelial cell death and inhibits proliferation of surviving cells. Atherosclerosis. 1995; 114(2):235-245.
31. Hoek JB, Pastorino JG. Ethanol, oxidative stress, and cytokine-induced liver cell injury. Alcohol. 2002; 27(1):63-68.
32. Al-Jawary AH, Ahmad RM. Effect of vitamin C on the hepatotoxicity induced by cisplatin in rats. Rafidain Journal of Science. 2012; 23(2E):23-33.
33. Robbins ME, Bywaters T, Jaenke RS, Hopewell JW, Matheson LM, Tothill P *et al*. Long-term studies of cisplatin-induced reductions in porcine renal functional reserve. Cancer Chemotherapy and Pharmacology. 1992; 29(4):309-315.
34. Yamate J, Sato K, Ide M, Nakanishi M, Kuwamura M, Sakuma S *et al*. Participation of different macrophage populations and myofibroblastic cells in chronically developed renal interstitial fibrosis after cisplatin-induced renal injury in rats. Veterinary Pathology. 2002; 39(3):322-333.
35. Yamate J, Machida Y, Ide M, Kuwamura M, Sawamoto O, LaMarre J. Effects of lipopolysaccharide on the appearance of macrophage populations and fibrogenesis in cisplatin-induced rat renal injury. Experimental and Toxicologic Pathology. 2004; 56(1, 2):13-24.

36. Ramesh G, Reeves WB. Salicylate reduces cisplatin nephrotoxicity by inhibition of tumor necrosis factor-α. Kidney International. 2004; 65(2):490-498.
37. Singh P, Srivastava MM, Khemani LD. Renoprotective effects of *Andrographis paniculata* (Burm. f.) Nees in rats. Upsala Journal of Medical Sciences. 2009; 114(3):136-139.
38. Padmalochana K, Dhana Rajan KS. In vivo nephroprotective potential from leaves extracts of *Andrographis paniculata*. World Journal of Pharmacy and Pharmaceutical Sciences. 2015; 4:1416-1425
39. Adejo GO, Gnimintakpa JM, Olowoniyi OD, Matthew PO. *Andrographis peniculata*: Capabilities against Free Radicals, Lipid Peroxidation, Hepatotoxicity, and Nephrotoxicity. Open Access Library Journal. 2016; 3(7):1-9.
40. Adeoye BO, Oyagbemi AA, Asenuga ER, Omobowale TO, Adedapo AA. The ethanol leaf extract of *Andrographis paniculata* blunts acute renal failure in cisplatin-induced injury in rats through inhibition of Kim-1 and upregulation of Nrf2 pathway. Journal of Basic and Clinical Physiology and Pharmacology. 2018; 30(2):205-217.
41. Verma N, Vinayak M. Antioxidant action of *Andrographis paniculata* on lymphoma. Molecular Biology Reports. 2008; 35(4):535-540.
42. Adedapo AA, Adeoye BO, Sofidiya MO, Oyagbemi AA. Antioxidant, antinociceptive and anti-inflammatory properties of the aqueous and ethanolic leaf extracts of *Andrographis paniculata* in some laboratory animals. Journal of Basic and Clinical Physiology and Pharmacology. 2015; 26(4):327-334.
43. Guan SP, Tee W, Ng DS, Chan TK, Peh HY, Ho WE *et al*. Andrographolide protects against cigarette smoke-induced oxidative lung injury via augmentation of Nrf2 activity. British Journal of Pharmacology. 2013; 168(7):1707-1718.
44. Wang H, Jia Z, Sun J, Xu L, Zhao B, Yu K *et al*. Nitrooleic acid protects against cisplatin nephropathy: role of COX-2/mPGES-1/PGE2 cascade. Mediators of Inflammation. 2015, 1-8.