Journal of Entomology and Zoology Studies

Available online at www.entomoljournal.com

E-ISSN: 2320-7078
P-ISSN: 2349-6800
JEZS 2016; 4(3): 224-227

Received: 24-03-2016
Accepted: 25-04-2016

Amer M Hussin
College of Veterinary Medicine, Baghdad University, Baghdad. Iraq.

Correspondence
Amer M Hussin
College of Veterinary Medicine, Baghdad University, Baghdad. Iraq.

Histological study of prostate in adult indigenous Iraqi dogs

Amer M Hussin

Abstract
The present histological work was designed to study the histological constituents of the prostate glands in adult Iraqi dogs. For this purpose eight adult dogs were prepared, surgically sacrificed and the tissue of prostate glands were removed, prepared and fixed in 10% neutral buffered formalin. Routine histological processes were carried out. The slides were stained by H&E stain. The result found that the tissue of dog prostate was thrown clearly into two apparent zones, an outer peripheral, and an inner transitional. The outer peripheral zone occupied wider area and irrigated with high blood supply compared to the narrower inner transitional zone. The majority of the prominent glandular tissue was restricted to the outer zone that was surrounded by limited muscular and connective tissue elements. The epithelium of this zone was highly developed. On the other hand the inner zone, was restricted and consisted of fewer mucosal and sub mucosal tubuloalveolar glands that surrounded by a considerable amount of connective tissue elements including the smooth muscle fibers. This may explain why the inner zone houses benign tumor and the peripheral zone houses malignant tumor, so that the current study hypothesized that, according to the intensity of secretory activity and the cellular performance of the glandular and connective tissue, benign or malignant tumor can occur.

Keywords: Dog, Histology, Prostate, Tumor

1. Introduction
The prostate gland is a dense organ arranged in concentric layers around the urethra, below the bladder. The prostate secretes and stores a significant contribution of seminal plasma that is released at ejaculation. The structure and function of the prostate depend on the level of testosterone [12]. Carnivorous prostate is well developed, and like in horse, best formed within the body or corpus prostate, consisting of two lobes [15]. Much of the glandular parenchyma of the prostate was located within the body of the gland. Transition zone is of medical importance because it is the site at which most benign prostatic hyperplasia originates [9]. The aim of this study was to find the relation between the histomorphological nature of the prostatic tissue and the incidence of tumor.

2. Materials and methods
Eight apparently healthy adult (4 years aged) Iraqi dogs were prepared. The prostate glands were surgically removed, fixed in 10% neutral buffered formalin, dehydrated by upgraded concentrations of alcohols, cleared with xylen and embedded in paraffin wax. Sections of 5-7 um thick were cut and stained by Hematoxylin & Eosin stain. Slides were examined under high magnification of light microscope [16].

3. Results
The current results revealed that the prostate of dog was well developed organ especially the body which possessed a disseminate part. The whole prostate composed of glands embedded in a considerable dense fibromuscular stroma within the tunica muscularis (Fig.1&2). Two distinct zones could be easily recognized, the inner narrow transitional zone and the outer main narrow transitional zone. The inner zone consisted of fewer mucosal and sub mucosal tubular alveolar glands that encircled by a considerable amount of fibro muscular elements. The height of epithelium was lower, flattened or cuboidal with small flattened heterochromatic nuclei (Fig.1, 2 &3). On the other hand, the glandular tissue of the outer zone was composed of many numerous follicles, whose lining epithelium showed papillary elevations (Fig.5). The glands were overcrowded with cuboidal to tall columnar epithelial cells that were well-developed branched tubuloalveolar which surrounded by limited amount of connective tissue

Elements. The nuclei of the epithelial cells were generally spherical and basally located (Fig 5&6). The nuclei were large and most of them were of euchromatic type with prominent numerous nucleoli (Fig. 6&7). Colloidal masses were found in the lumen of the follicles and ducts, the release of this secretion leaving a small vesicles above the luminal surface of the epithelial cells (Fig, 8). The outer zone supplied with rich blood supply (Fig.9).

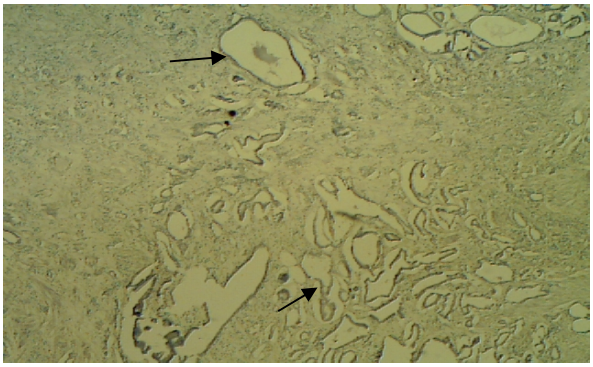

Fig 1: Inner zone of prostate gland in dog. Notice the poor developed prostatic glands (arrows) embedded in the surrounding well developed fibromuscular tissue. 100X. H&E stain.

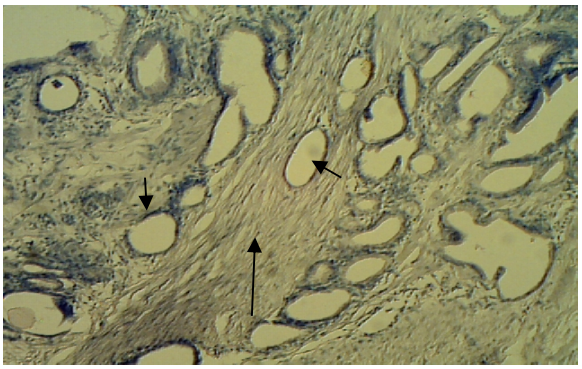

Fig 2: Inner zone of prostate in dog. Notice the small devoid-colloid follicles (small arrows) that embedded in a well-developed fibromuscular tissue (long arrow). The absence of folds and the low height epithelium. X 200. H&E stain.

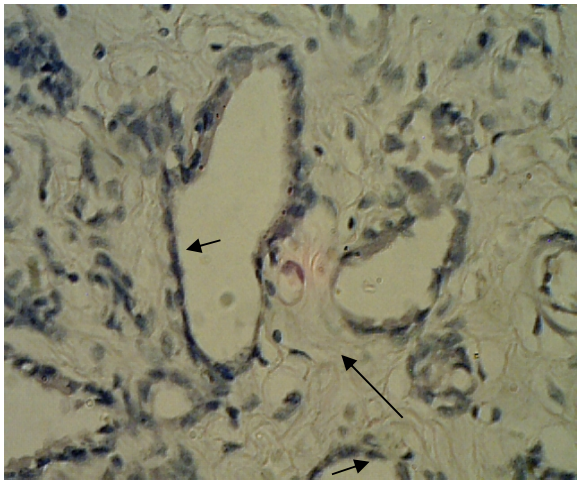

Fig 3: Inner zone of prostate gland. Note the well-developed fibromuscular connective tissue (long arrow), absence of the follicular folds, squamous to cuboidal epithelium (small arrows) and the small–sized heterochromatic nuclei. The long axis of the nuclei is not parallel to the long axis of the follicular cells. X 200. H&E stain.

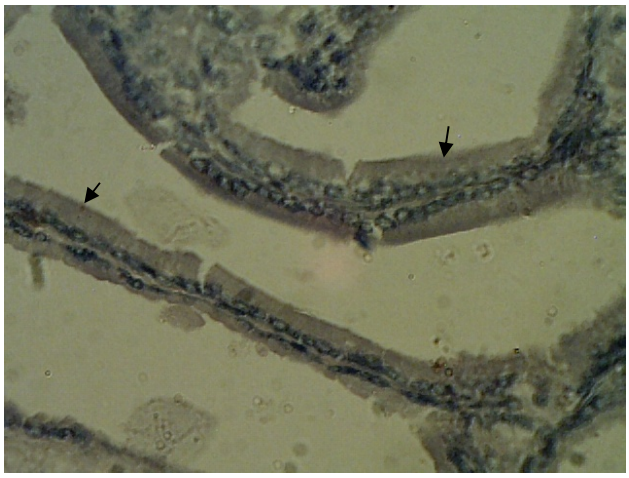

Fig 4: Outer zone of the prostate. Notice the high cellularity of the tight tall columnar epithelium, with euchromatic nuclei. The microvilli appear at the luminal surface (arrows). The long axis of the nuclei was parallel to the basement membrane. X400. H&E stain.

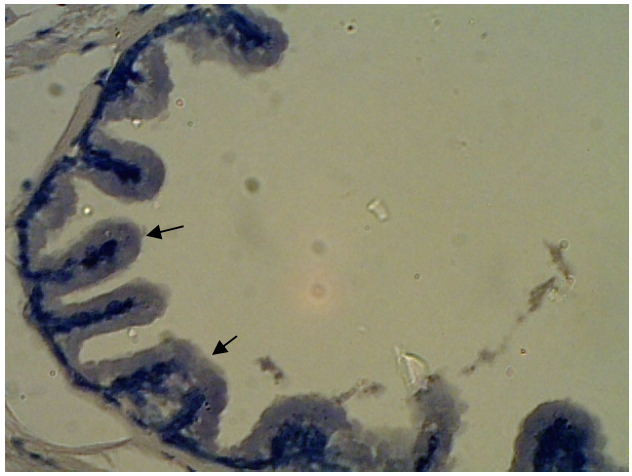

Fig 5: prostatic follicle in outer zone showing papillary elevations of the columnar epithelium (arrows).X400. H&E stain.

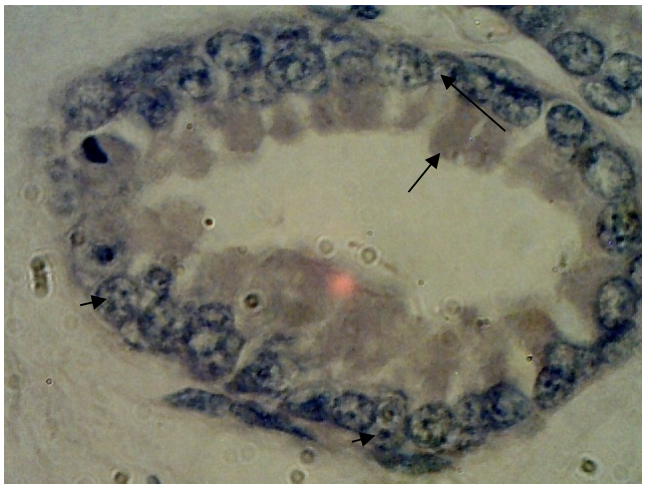

Fig 6. Prostate of the dog in outer zone showing tall columnar epithelium (long arrow) with large spherical euchromatic nuclei. Notice the prominent nucleoli (short arrows). X1000. H&E stain.

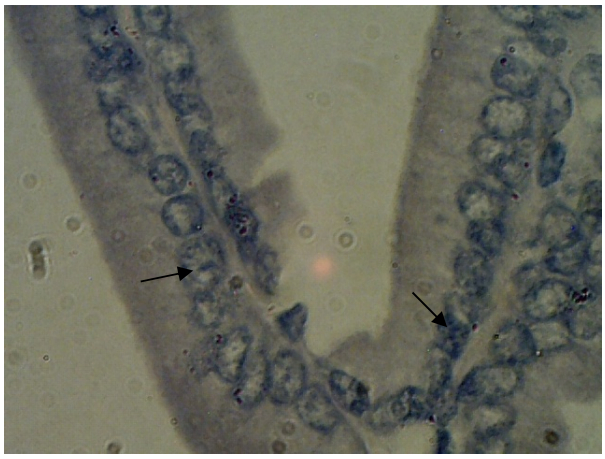

Fig 7: outer zone of prostate in dog showing high cellularity of tall columnar epithelium. Note the overcrowded euchromatic nuclei and prominent nucleoli. X1000. H&E stain.

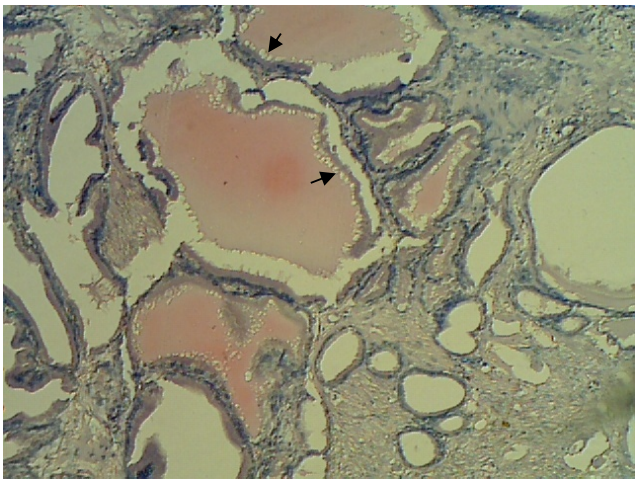

Fig 8: Prostatic follicles in the outer zone of the gland filled with colloidal materials. Note the presence of vesicles at the apical surface of the epithelial cells (arrows). X200. H&E stain.

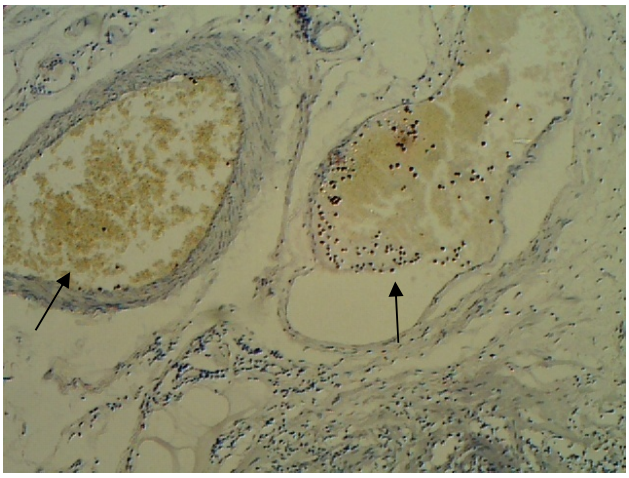

Fig 9: Two considerable blood vessels in the outer zone of prostate gland filled with blood (arrows). X400. H&E stain.

4. Discussion

The well-developed abundant glands of the peripheral zone, their folded epithelium, tall epithelial cells and high secretory activity were many factors that serve to make this zone liable to malignant tumor, on the other hand, the decrease of glandular: stroma ratio in the inner zone, and the increase of muscular tissue among the glands can lead to a benign tumor. The present result was confirmed with [3]. The above authors reported that the outer zone had adenomers (secretory acini) with wide lumen and scarce folds that surrounded by a thin layer of smooth muscle and collagen fibers. The epithelium was low cuboidal with centrally located nuclei. The authors stated also that the inner zone was the closest to the urethral duct. Their adenomers have narrow lumen surrounded by more developed fibromuscular tissue than the peripheral zone. The epithelium was cylindrical pseudostratified and formed from abundant long folds that projected into the glandular lumen. The cylindrical epithelial cells with elongated nuclei were predominant. The findings of the present study were not agreed with the results of the previous studies that mentioned above, in respect to the type of epithelium and the longitudinal folds.

The probability of incidence of prostatic cancer in the outer zone is more than in the inner zone, as the former zone occupies a considerable area within the prostate, and receives a considerable amount of blood supply. Their glandular tissue was highly developed and the epithelium was thrown in numerous papillary elevations to increase the surface area and finally to increase the structural and functional performance of the tissue. Moreover, the presence of euchromatic nuclei with numerous prominent nucleoli suggesting an active state of protein synthesis, and the presence of heterochromatic nuclei refers to high mitotic figure in the outer zone. These results were in line with [2, 4]. who referred to the presence of highly specialized secretory epithelial cells in the normal peripheral zone of the prostate gland that is lacked in the central zone of the prostate. The peripheral zone of the prostate gland accumulates the highest concentration of zinc in comparison to other soft tissues of the body. This is in accordance with the finding of [18]. who stated that the secretion of prostate contains different enzymatic proteins and zinc with a concentration 500-1000 times the concentration in blood. This is confirmed by [9] who reported that the major site of prostatic cancer was the peripheral zone. [12] Stated also that the benign prostatic hypertrophy was occurred generally in the inner zone surrounding the urethra and specially the smooth muscle cells which have high capability of undergoing mitosis. Furthermore, Zinc in turn plays a role in DNA replication and stimulates cellular proliferation [14, 11]. This may lead to high cellular proliferation in the peripheral zone of prostate.

5. Conclusion

the herein study concluded a reverse relationship between the morphological and functional status of glandular prostatic epithelium.

6. Conflict of interest

The authors declare that there is no conflict of interest regarding the publication of this paper.

7. References

1. Adamson E, de Belle I, Mittal S, Wang Y, Hayakawa J, Korkmaz K, Egr1 signaling in prostate cancer. Cancer Biol. Ther. 2003; 2(6):617-622.

2. Beck FW, Prasad AS, Butler CE, Sakr WA, Kucuk O, Sarkar FH. Differential expression of hZnT-4 in human prostate tissues. Prostate. 2004; 58(4):374-381.
3. Chaves EM, Aguilera–Merlo C, Filippa V, Mohamed F, Dominguez S, Scardapan L. Anatomical, Histological and immunohistochemical study of the reproductive system accessory glands in male viscacha (lagostomus maximus maximus) Anat. Histol. Embryol. 2011; 40(11):20.
4. Desouki MM, Geradts J, Milon B, Franklin RB, Costello LC. H. Zip 2 and hZip3 zinc transporters are down regulated in human prostate adenocarcinomatous glands. Mol. Cancer. 2007; 6(37).
5. Gallus S, Foschi R, Negri E, Talamini R, Franceschi S, Montella M. Dietary zinc and prostate cancer risk: A case-control study from Italy. Eur. Urol. 2007; 52(4)1052-1056.
6. Ganong WF. Review of medical physiology. 22 ed. Lange. McGraw Hill Company. Singapore, 2005, 424-431.
7. Herbein G, Varin A, Fulop TN F-kappa B. AP-1; zinc-deficiency and aging. Biogerontology. 2006; 7(5-6):409-419.
8. John E, Laskow TC, Buchser WJ, Pitt BR, Basse PH, Butterfield LH. Zinc in innate and adaptive tumor immunity. J Transl Med. 2010; 8:118.
9. Junqueira LC, Carneiro J. Basic histology. 11thed. mk:@MSIT Store: H:\basic %20 histology. CHM:/Basic Histology. jpg, 2009.
10. Lawson KA, Wright ME, Subar A, Mouw T, Hollenbeck A, Schatzkin A. Multivitamin use and risk of prostate cancer in the National Institutes of Health-AARP diet and health study. J Natl Cancer Inst. 2007; 99(10):754.
11. Mei X, Xu D, Xu X, Zhenq Y. Novel role of Zn (11)-Curcumin in enhancing cell proliferation and adjusting pro inflammatory cytokine-mediated oxidative damage of ethanol-induced acute gastric ulcers. 2012; 197(1):31.
12. Mesher AL. Junqueira's Basic Histology, text & atlas. 12 ed. Mc Graw Hill Company, 2010, 344-386.
13. Moyad MA. Zinc for prostate disease and other conditions: A little evidence, a lot of hype, and a significant potential problem. Urol Nurs. 2004; 24(1):52.
14. Nilson JR. How cytotoxic is Zinc a study on effects of Zinc on cell proliferation endocytosis, and fine structure of the ciliate Tetrahymena. Acta protozool. 2003; 42:19-29.
15. Samuelson DA. Text book of veterinary histology. Saunders Elsevier. China, 2007, 435-437.
16. Suvarna SK, Layton C, Bancroft JD. Bancroft's Theory and Practice of Histological Techniques. 7thed. churchill Livingstone, 2013, 173-186.
17. Uzzo RG, Crispen PL, Golovine K, Makhov P, Horwitz EM, Kolenko VM. Diverse effects of zinc on NF-kappa B and AP-1 transcription factors: Implications for prostate cancer progression. Carcinogenesis. 2006; 27(10):1980-1990.
18. Wikipedia.mhtml:file://G:\Prostate%20%20Wikipedia,%20the%20free%20encyclopedia.mhl 02/10/2011.