



E-ISSN: 2320-7078  
P-ISSN: 2349-6800  
JEZS 2017; 5(2): 189-192  
© 2017 JEZS  
Received: 26-01-2017  
Accepted: 27-02-2017

**Gautam Patra**

Department of Veterinary  
Parasitology, College of Veterinary  
Sciences and Animal Husbandry,  
Central Agricultural University,  
Selesih, Aizawl, India

**Leena Roy**

Department of Veterinary Public  
Health and Epidemiology  
College of Veterinary Sciences and  
Animal Husbandry, Central  
Agricultural University, Selesih,  
Aizawl, India

**Subhamoy Ghosh**

Department of Veterinary  
Parasitology, College of Veterinary  
Sciences and Animal Husbandry,  
Central Agricultural University,  
Selesih, Aizawl, India

**Chirom Nishita Devi**

Department of Veterinary  
Parasitology, College of Veterinary  
Sciences and Animal Husbandry,  
Central Agricultural University,  
Selesih, Aizawl, India

**SK Borthakur**

Department of Veterinary  
Parasitology, College of Veterinary  
Sciences and Animal Husbandry,  
Central Agricultural University,  
Selesih, Aizawl, India

**H Lalrinkima**

Department of Veterinary  
Parasitology, College of Veterinary  
Sciences and Animal Husbandry,  
Central Agricultural University,  
Selesih, Aizawl, India

**Hmar Lalliankimi**

Department of Livestock Production  
College of Veterinary Sciences and  
Animal Husbandry, Central  
Agricultural University, Selesih,  
Aizawl, India

**D Kathiresan**

Management: Dean; Department of  
Veterinary Gynaecology & Obstetrics,  
College of Veterinary Sciences and  
Animal Husbandry, Central  
Agricultural University, Selesih,  
Aizawl, India

**Correspondence****Gautam Patra**

Department of Veterinary  
Parasitology, College of Veterinary  
Sciences and Animal Husbandry,  
Central Agricultural University,  
Selesih, Aizawl, India

## Study on house lizard (*Hemidactylus flaviviridis*) trematode by scanning electron microscopy from different localities of Aizawl district, Mizoram, India

**Gautam Patra, Leena Roy, Subhamoy Ghosh, Chirom Nishita Devi, SK Borthakur, H Lalrinkima, Hmar Lalliankimi and D Kathiresan**

**Abstract**

A survey of helminths in house lizard (*Hemidactylus flaviviridis*) from different parts of Aizawl district of Mizoram was carried out. Interestingly one house lizard was found infected with 8 numbers of one particular species of trematode among 50 lizards examined. Light microscopy (LM) and scanning electron microscopy (SEM) revealed that the recovered parasite belongs to *Postorchigenes* sp. This paper presented the detail surface morphology of the *Postorchigenes* sp. of lizard. So far, this is the first report of such trematode from this part of India.

**Keywords:** *Hemidactylus flaviviridis*, *Postorchigenes* sp., LM, SEM, Mizoram, India.

**1. Introduction**

House lizards (*Hemidactylus flaviviridis*) are frequently found in human dwellings in tropical countries like India and thus are closely associated with human beings. The infection with different parasites plays a pivotal role in reptiles [1]. The factors like stressful life, concentration of animals and the cohabitation with their host contribute development, multiplication and spread of parasites [1]. Also these factors undermine the immune response in reptiles predisposing the opportunity for pathogenic organisms to cause infections and resultant diseases. Reptiles may carry pathogens and thereby there is chance of spreading the diseases to other animals and even to humans [1-3].

Reptiles harbor a wide range of internal parasites such as protozoans, nematodes, cestodes, pentastomids, acanthocephalans and trematodes [1, 3-4]. Kennedy *et al.* (1987) [4] repeated three digeneans from species of lizards: *Paradistomum geckonum*, *Mescoelium sociale* and *Paradistomum ovatus*. The accurate identification of reptilian parasites depends on the collection of the correct specimens, fixation, processing methods and the persons who are well trained in the identification of parasites [5-7].

The present study describes the trematode *Postorchigenes* sp. adult morphology based on LM and SEM recovered from the gut of house lizards collected in Aizawl district, Mizoram.

**2. Materials and methods****2.1 Collection of Parasites**

A total of 50 lizards (*Hemidactylus flaviviridis*) were collected from different localities of Aizawl district, Mizoram, India on different occasions. The lizards were brought to the Department of Veterinary Parasitology, College of Veterinary Sciences and Animal Husbandry, Central Agricultural University, Aizawl, Mizoram, India. The lizards were thoroughly examined for presence of any ecto-parasites before euthanizing with chloroform soaked cotton. Viscera of each lizard were separated and examined thoroughly. On examination 08 (eight) numbers of trematode were recovered from one lizard. All of them were recovered from one lizard. All of them were immediately put into 70% alcohol for further identification on the basis of key provided by Schimdt, 1986 [9].

## 2.2 Morphological Study

Before thorough study under LM and SEM, all trematode were studied under stereozoom (Euromex, Holland). One trematode was processed and permanent slide was made after proper staining. The morphological study under LM revealed that all trematode belong to the single genus *Postorchigenes*. Measurements were expressed in millimetre. For critical surface structure two trematodes were further processed for SEM.

## 2.3 Preparation of sample for SEM

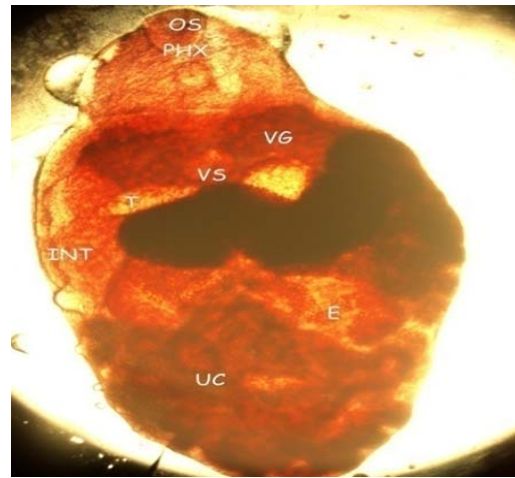
Both trematode were fixed in 3% glutaraldehyde. Before dehydration any hindrances like faecal debris, mucus, blood or other body fluids were carefully removed by washing several times with nuclease free water (NFW) several times with the help of a brush. The samples were then fixed at 4 °C for 24 hours. The fixed trematodes were washed in phosphate buffered saline (pH – 7.2) three times and then in double distilled water followed by acetone dehydration.

After acetone dehydration, the specimens were dried with liquid CO<sub>2</sub> at its critical point i.e. 31.5 °C at 1100 psi. The specimens are then dipped in tetra methyl saline (TMS) for 5-10 minutes with two changes at 4 °C. They are then brought to room temperature (25-26 °C) for drying. The samples were mounted on aluminium stubs. Finally they were gold coated in a sputter coat and finally examined under SEM [(JSM-6360-JEOL)] at the North Eastern Hill University (NEHU), Shillong, Meghalaya, India in sophisticated analytical instrument facilities (SAIF) laboratory.


## 3. Results

A total of 50 lizards were examined but only one lizard was found positive for the trematode *Postorchigenes* sp. The total length of the trematode was 2 mm and the breadth was 1.22 mm. Testes measure 0.4 mm by 0.2 mm. The oral sucker was 0.1 mm in length by 0.18 mm wide, while the ventral sucker is slightly larger (0.14 mm) but slightly narrower (0.1 mm) than the oral sucker. The total oesophagus is about 0.27 mm in length by 0.09 mm wide. Prepharynx absent, caeca extend upto posterior border of testes which were oval, and nearly symmetrical. Ovary on right side of ventral sucker. Vitelline glands occupy the space between pharynx and ventral sucker (Figure 1). Eggs are small and numerous.


The outer surface of the representative specimens of *Postorchigenes* was studied by SEM. Special emphasis was given on the distribution and morphology of the spines. The tegument of trematode was composed of three layers: a tegumental outer membrane, a matrix and a basal tegumental membrane. The tegumental surface is often interrupted with ornamentations such as spines, papillae, pits and ridges [9]. The rim of both oral and ventral sucker of the present species showed sensory papillae with varied morphology and distribution. Fig. 2-4 shows characteristics of the tegument of the oral and ventral suckers of *Postorchigenes* sp. The tegument of the present trematode also shows spines with variation of morphology and distribution. Figures 5-7 show the shape and distribution of spines found in the tegument of *Postorchigenes* species of lizard.



**Fig 1:** Gross specimen of *Postorchigenes* sp. under light microscope  
OS – oral sucker, PHX – Pharynx,  
VG – Vitelline Gland, VS – Ventral Sucker,  
T – Testes, E – Eggs, UC – Uterine Coil,  
INT – Intestinal caecum



**Fig 2:** Rim of oral sucker with the presence of sensory papillae



**Fig 3:** Oral and ventral sucker




Fig 4: Rim of ventral sucker with spines

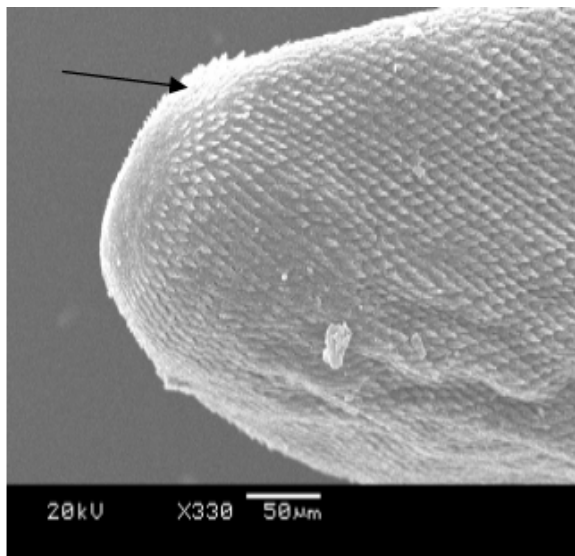


Fig 5: Posterior end showing the presence of the spines




Fig 6: Outer surface of the mid part of the body




Fig 7: Spines over the body surface

#### 4. Discussion

For systematic classifications, all morphological aspects of helminthes must be studied under the light microscope. Some morphological features in the case of trematode include the position of oral and ventral suckers, position of testes and ovary, distribution of vitelline glands, cuticular structure/s, reproductive structures and others. All these are of taxonomic importance.

The SEM study of the tegument of helminths could be useful for intraspecific variation of different geographical location [8]. Similarly, variations due to wide range of phylogenetically unrelated hosts such as age of the host or diet, previous exposure to the parasite, presence of another parasite etc could also detect intraspecific variation. The present species of *Postorchigenes* was found shorter in length than earlier report by Saehoong and Woongsawad (1997) [9], otherwise the other characteristics are consistent with this report.

Various workers have reported digenetic trematodes and helminth parasites in different lizards [10-11]. Kennedy *et al* [12] described three species of digenetic trematodes from lizards and found that prevalence and intensity of two trematodes namely; *Postorchigenes geckonum* and *P. ovatus* were similar in males and females of each host species. The present finding also did not find any significant variation of infection rate between male and female house lizard. In the present SEM study the general body tegument was observed spinous and agreed with the observation of previous workers [13].

The study of parasitic helminthes by SEM began in 1970s and stressed mainly those parasites that caused diseases in humans and livestock, as well as parasites of crops [14]. The study cannot correlate the surface topography of present specimens which were studied by SEM because of lack of bibliographic information. The study found that the entire body of the fluke was covered with conical shaped spines. However, the spines around oral and ventral suckers were attenuated. Few sensory papillae around openings are observed and the entire tegument had a porous sponge structure, which may be secretory in nature [17].

This study was intended to provide baseline morphology carried out by LM and SEM of *Postorchigenes* sp. which was recovered from the gut of a house lizard in Mizoram, India. This may be the first time that such kind of work has been carried out in India. It is still unclear whether other species of lizards are refractory or susceptible, and there might be ecological or evolutionary reasons for this host.

## 5. Conflict of interest statement

Authors declare no conflict of interest.

## 6. Acknowledgements

The authors are thankful to the Dean, College of Veterinary Sciences and Animal Husbandry, Central Agricultural University, Selesih, Aizawl, India for providing necessary facilities for conducting the experiment.

## 7. References

1. Rataj AV, Lindtner-Knific R, Vlahovic K, Mavri U, Dovic A. Parasites in pet reptiles. Acta Veterinaria Scandinavica. 2011; 53:33.
2. Mihalca AD, Gherman C, Ghira I, Cozma V. Helminth parasites of reptiles (Reptilia in Romania. Parasitology Research. 2007; 101:491-492.
3. Papini R, Manetti C, Mancianti F. Coprological survey in pet reptiles in Italy. Veterinary Record 2011; 169:207.
4. Kennedy MJ, Killick LM, Beverley, Burton M. The prevalence of *Pardismostomum geckonum*, *Mesocoelium sociale* and *Postorchigenes ovatus* (Digenea) in lizards. (Sauria) from Indonesia. Canadian Journal of Zoology. 1987; 65:1292-1294.
5. Zajac AM, Conboy GA. Faecal Examination for the Diagnosis of Parasitism. In: Veterinary Clinical Parasitology. 8<sup>th</sup> edition. Chichester: Willey-Blackwell, 2012, 3-164.
6. Schimdt GD. Handbook of Tapeworm identification. Florida: CRC Press, Boca Ralton, 1986, 675.
7. Pasmans F, Blahak S, martel A, Pantchev N. Introducing Reptiles into a captive collection: the role of the veterinarian. Veterinary Journal. 2008; 175:53-68.
8. Kennedy J. Geographical variation in some representatives of *Haematoloechus* Looss, 1899 (trematoda: haematolochidae) from Canada and United State. Canadian Journal of Zoology, 1980; 58:1151-1167.
9. Saehoong P, Wongsawad C. Helminths in House Lizards (Reptilia : Gekkonidae). Southeast Asian Journal of Tropical Medicine and Public Health. 1997; 28(Suppl 1):184-9.
10. Didyk AS, canaries AG, Kinsella JM. Intestinal helminthes of the spotted sand piper, *Actitis macularius* (L), during fall migration in New Brunswick, Canada, with a checklist of helminthes reported from their host. Comparative Parasitology. 2007; 74:359-363.
11. Yildirimbani HS, Bursey RC, Naci Altund. Helminth parasites of the Broken green lizard. *Lacerata trilineata* Bedriaga, 1986, from Bursa, Turkey. Turkey Journal of Zoology. 2011; 35(3):1-17.
12. Kennedy MJ, Killick LM, Beverley-Burton M. The prevalence of *Paradistomum geckonum*, *Mesocoelium sociale* and *Postorchigenes ovatus* (Digenea) in lizards (Sauria) from Indonesia. Canadian Journal of Zoology, 1987; 65:1292-4.
13. Ferrer JR, Gracenea M, Trullols M, Gonzalez- Moreno O. Ultra structural observations of the tegument of *Postorchigenes gymnesicus* (Digenea Leciths dendriidae). Journal of Helminthology 1996; 70(1):13-9.
14. Halton D. Microscopy and the Helminth Parasite. Micron, ISSN 0968-4328, 2004; 35(5):361-390.