



E-ISSN: 2320-7078
P-ISSN: 2349-6800
 JEZS 2017; 5(2): 1784-1787
 © 2017 JEZS
 Received: 19-01-2017
 Accepted: 20-02-2017

Amayour A

(A). Laboratory of Agro-Physiology, Biotechnology, Environment and Quality, Faculty of Sciences, University Ibn Tofail, P.O.BOX 133, Zip Code 14000, Kenitra, Morocco
 (B). Hunting office of the Provincial Directorate of Water and Forests and the fight against desertification in Meknes El Hajeb, Morocco

El Alaoui Z

(A). Laboratory of Agro-Physiology, Biotechnology, Environment and Quality, Faculty of Sciences, University Ibn Tofail, P.O.BOX 133, Zip Code 14000, Kenitra, Morocco
 (B). Ain Defali health center, Sidi Kacem Province, Morocco

Alkhali A

(A). Laboratory of Agro-Physiology, Biotechnology, Environment and Quality, Faculty of Sciences, University Ibn Tofail, P.O.BOX 133, Zip Code 14000, Kenitra, Morocco
 (B). Medical laboratory, Althawra Hospital, Sana'a, Yemen

Hassouni T

(A). Laboratory of Agro-Physiology, Biotechnology, Environment and Quality, Faculty of Sciences, University Ibn Tofail, P.O.BOX 133, Zip Code 14000, Kenitra, Morocco
 (B). Regional Center of Education and Training, Meknes, Morocco

Elkharrim K

Laboratory of Agro-Physiology, Biotechnology, Environment and Quality, Faculty of Sciences, University Ibn Tofail, P.O.BOX 133, Zip Code 14000, Kenitra, Morocco

Belghyti D

Laboratory of Agro-Physiology, Biotechnology, Environment and Quality, Faculty of Sciences, University Ibn Tofail, P.O.BOX 133, Zip Code 14000, Kenitra, Morocco

Correspondence**Amayour A**

(A). Laboratory of Agro-Physiology, Biotechnology, Environment and Quality, Faculty of Sciences, University Ibn Tofail, P.O.BOX 133, Zip Code 14000, Kenitra, Morocco
 (B). Hunting office of the Provincial Directorate of Water and Forests and the fight against desertification in Meknes El Hajeb, Morocco

Presence of very high prevalence of *Macracanthorhynchus hirudinaceus* infection in Wild Boars (*Sus Scrofa Barbarus*) in El Hajeb province, Middle Atlas, Morocco

Amayour A, El Alaoui Z, Alkhali A, Hassouni T, Elkharrim K and Belghyti D

Abstract

The study was aimed to evaluate the prevalence of *M. hirudinaceus* in wild boars (n = 33) in the El Hajeb province, Middle Atlas region of Morocco from October 2014 to March 2015. The entire intestinal tract of each wild boar was divided into anatomical parts; the intestines were opened longitudinally and the wall was examined for the presence of worms and any pathogenic lesions. The collected acanthocephalans were removed and placed in distilled water for three hours for relaxation, before transferring them to another vial containing fixative (10% formalin). The results revealed that from the 33 boars, 14 (42%) were male and 19 (58%) were female. Prevalence of *M. hirudinaceus* was found to be 81.81%. Male boars constituted 78.57% of the infected animals while females constituted 84.21%. The findings of this study show the highest prevalence so far of *M. hirudinaceus* infection in wild boars. Such high rates of infection of wild boars may lead to higher risk of infection for farmers and residents of rural areas.

Keywords: *Macracanthorhynchus hirudinaceus*, epidemiology, wild boar, El Hajeb Province, Morocco

1. Introduction

Wild boars (*Sus Scrofa*) have wide distribution all around the world. The species of wild boars (*Sus Scrofa Barbarus*) live in condensed populations in northern Morocco, mainly in the forested mountainous regions. Their distribution extends from the Rif to the Anti-Atlas Mountains [2, 1]. Forests are their natural habitat, in particular forests with dense undergrowth, which offer them shelter, protection and food. However, they can also inhabit other environments due to their adaptive capacity. For example, populations of wild boar are found from the Alfa's highlands to the Saharan oases in the south of the country [13]. The wild boar is an omnivore. Its diet includes a wide variety of species, including small animals, such as snails, earthworms and larvae, as well as larger animals, such as hedgehogs and rabbits. Plant material favoured by wild boar, includes roots, bulbs, rhizomes, mushrooms and various forest fruits, especially acorns [14]. Nevertheless, wild boars often roam freely throughout villages and farms. Alongside with the social and economic concerns about wild boar causing damage to farms, they could play an important role in spreading epidemics of several types of zoonotic helminths by acting as reservoir hosts and maintaining the helminths in sylvatic cycles of the parasite, regardless of the domestic cycles [10]. In rural communities, wild boars (*Sus Scrofa Barbarus*) are in narrow contact with farmers and can pose a potential risk of transmission of zoonotic diseases. *Macracanthorhynchus hirudinaceus* is a thorny-headed worm belonging to the Acanthocephalan's phylum [9]. These cosmopolitan species live in the small intestine of wild boars and may transmit to humans by accidental ingestion of its intermediate host. This thorny-headed worm has an indirect cycle using dung beetles as an intermediate host [17, 7]. It causes serious damage to the intestinal mucosa of their definitive host, through penetrating deep into its gut wall with its proboscis. Heavy infestations may induce catarrhal enteritis and, rarely, perforation of the guts wall, which can result in fatal peritonitis [7]. As no parasitological data on wild boar in Morocco are available, the aim of the present study were to determine the prevalence and intensity of infection of wild boar populations in the El Hajeb province with *M. hirudinaceus*; assess the possible effect of age and sex of wild boars on the

intensity of infection; and to evaluate the effect of external factors related to the living habitat of wild boars.

2. Material and Methods

2.1 Study area

The study region, illustrated in Fig. 1, is at the crossroads of the rich plain of Saïs and the foothills of the middle Atlas, El

Hajeb province (study area), which is located 30 km south of the city of Meknes (33° 41' 45" N, 5° 22' 00"). It has an altitude of about 1000 m and it's characterized by a temperate climate. The winter seasons are quite cold with many freezing days. Despite the high altitude, summers are hot.

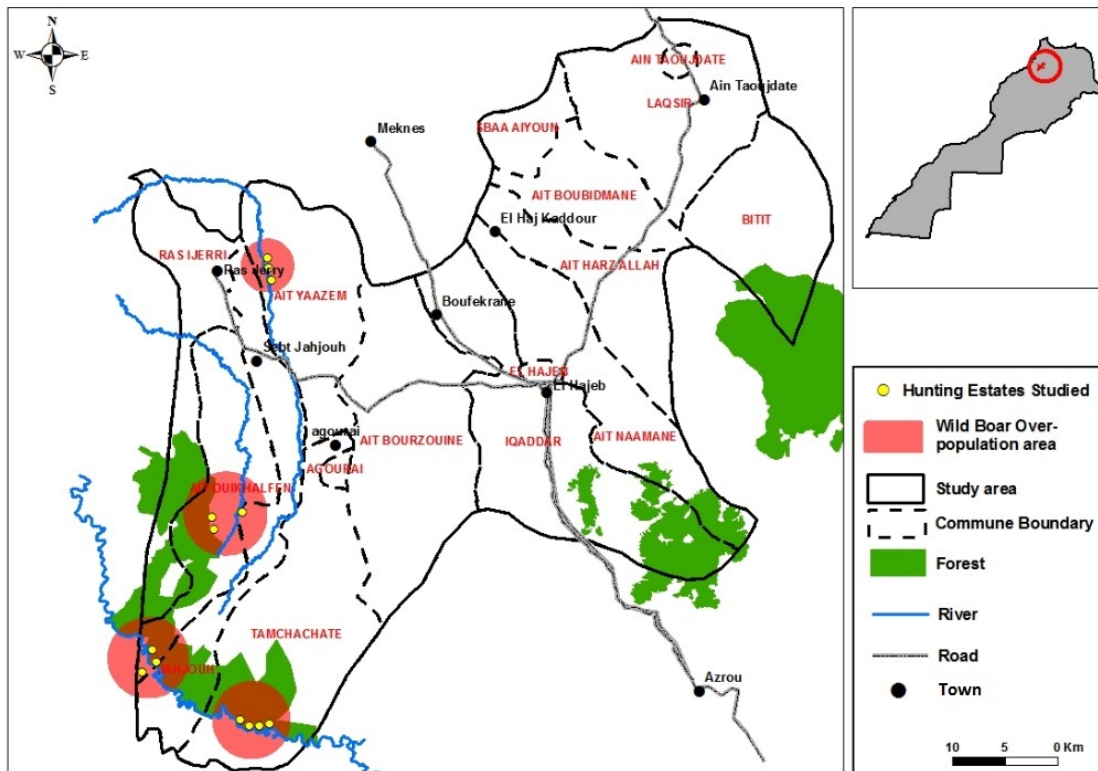


Fig 1: Mapping of the study area in the El Hajeb province (Middle Atlas).

The survey on prevalence of *M. hirudinaceus* was carried out on 33 wild boars (*Sus Scrofa Barbarus*) (19 females and 14 males) from the four areas of El Hajeb province (Middle Atlas), which were hunted officially for wildlife damage control in the period from October 2014 to March 2015. 13 there of originated from the cultivated area and 20 from the rangelands and forest. Autopsy was performed immediately after the death of each wild boar. The thoracic and abdominal viscera were isolated, removed, placed in plastic bags, labelled and taken to the laboratory. Data recorded at sampling time included the location of shooting, sex and age of wild boars. The host age was estimated according to Boitani and Mattei (1992). Age was determined on the basis of tooth development, using four age categories: <1 year old, 1 to 2 years old, 2 to 3 years old and 3 > years old.

Stool samples were taken directly from the rectum, stored in plastic vials filled with formalin (10%) and refrigerated at 4 °C temperature. After applying the formalin-ethyl acetate sedimentation technique, the samples were inspected carefully under microscope for detection of helminths.

The entire intestinal tract was divided into anatomical parts, the intestines were opened longitudinally and the gut wall was examined for the presence of worms and any pathogenic lesions. The collected acanthocephalans were removed and

placed in distilled water for three hours for relaxation. After that, worms were transferred to another vial containing fixative (10% formalin). To confirm the species, the total length and width, as well as the number and arrangement of the hooks on the proboscis of the acanthocephalan were measured and analysed.

2.2 Data analysis

Quantitative Parasitology 3.0 [18] was used to analyse and detect any association between *M. hirudinaceus* infection and wild boar shooting site, sex, and age group.

3. Results

The prevalence of acanthocephalan among the 33 boars examined was 81.81%. A total of 112 helminths (74 females and 38 males) were collected from the intestines of 27 infected wild boars. The formalin-ethyl acetate sedimentation technique detected the presence of Acanthocephalan eggs (fig. 2 E) in 11 of the 27 (40.74%) infected boars. The sex ratio of the worm was 1.0: 1.94 (males: females). The results of the average measurements of the distinctive characteristics of a sample of the *Macracanthorhynchus hirudinaceus* found are presented in Table 1.

Table 1: Extreme values and mean measures of distinctive features (in mm) of 22 females and 8 males *Macracanthorhynchus hirudinaceus* found in wild boars.

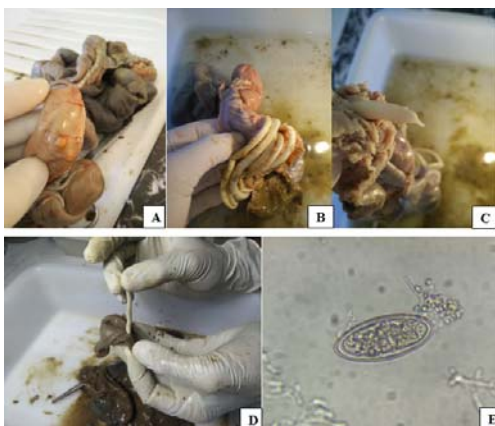
Measurements	Males		Females	
	min - max	mean	min - max	mean
Total body length	40 - 117	72.1	82 - 480	246.9
Width at mid-body	2.00 - 4.00	2.85	3.00 - 6.50	4.31
Proboscis length	0.56 - 0.76	0.63	0.59 - 1.10	0.79
Proboscis row No	5 - 7	5.5	5 - 7	5.3
Hook No per row	6 - 7	6.5	6 - 9	7.4
Hook length	0.124 - 0.179	0.157	0.129 - 0.245	0.176

The results of the study presented in Table 2 showed the relationship between infection with *Macracanthorhynchus hirudinaceus*, site of the shooting, age and sex of wild boars. It appeared that infection levels tend to increase with the age of wild boars. The intensity of infection varied from 1 to 13 mean (4.18) (Table 2).

Table 2: Prevalence and intensity of infection of *Macracanthorhynchus hirudinaceus* in relation to the age and sex of wild boars and the site of shooting

Wild boars data	N	<i>M. hirudinaceus</i>	
		Prevalence (%)	Intensity
Host age			
<1	17	64.70%	1.36 (1 - 2)
1 - 2	8	100%	4.5 (3 - 7)
2 - 3	5	100%	9.5 (3 - 13)
>3	3	100%	7 (6 - 8)
Host sex			
Males	14	78.57%	4.54 (1 - 8)
Females	19	84.21%	3.87 (1 - 13)
Shooting site			
Cultivate area	13	69.23%	5 (1 - 9)
Rangelands and forest	20	90%	3.72 (1 - 13)
Total	33	81.81%	4.18 (1 - 13)

The presence of worms was obvious in all infected boars either by their apparent movement inside the intestinal lumen; the volume of the intestines where at least several worms were present (Fig. 2 B); the white-reddish nodules observed on the external surface of the gut wall, indicating the spot invaded by the worm's proboscis (Fig. 2 A). Due to the absence of registered studies in Morocco on wild boar parasitology so far, we compared our results with studies in other regions. Our findings are discussed below.

**Fig 2:** Lesions provoked by *M. hirudinaceus*: **A** a fibrotic nodule caused by the attachment of worm proboscis to the intestinal wall, visible from serosal surface, **B** intestine with a heavy worm burden, **C** head of adult worm release its hold, **D** adult worm embedded in the intestine wall, **E** egg of *M. hirudinaceus* detected in stool.

4. Discussion

Macracanthorhynchus hirudinaceus is a widely distributed acanthocephalan parasite, which lives in the intestines of wild boars and other suids, and very occasionally in humans or dogs. It causes enteritis, gastritis or peritonitis. It is known as, "Giant Thorny-Headed Worm"^[5]. This zoonosis is not rare in countries where beetles are included in the human diet for gastronomic or medical purposes, such as China^[20, 7] and Thailand^[8, 15]. One of the objectives of the present study was to determine the prevalence of *M. hirudinaceus* in wild boar in the province of El Hajeb in Morocco. When we compared the results of this study with the prevalence determined in other regions through similar studies: 2.1% in Croatia^[16]; 21% in Spain^[4]; 61.25% in Corsica^[6]; and 64% Iran^[12], we found that the total prevalence of 81.81% detected in this study is the highest observed so far for *M. hirudinaceus*. However, since this is the first study on *M. hirudinaceus* in wild boar in Morocco, there is a possibility that the very high prevalence in the province of El Hajeb may reflect a very high contamination occurring only in the study area, notably in forests (Table 2) because of overpopulation of wild boar in this area. Moreover, we should take into consideration that *M. hirudinaceus* eggs showed an important resistance, remaining infective in soil for up to 1.2 – 3 years and tolerating both desiccation and very cold temperatures below 0 °C^[11].

No correlations were found between *M. hirudinaceus* infection and gender of the animals or shooting site in this study. However, a light correlation was found with age. We observed that boars younger than one year were less infected than adult animals. If infected, despite the very high prevalence, the intensity of the detected infection did not appear to be high (Table 2).

This acanthocephalan cause serious damage to the intestinal mucosa, primarily traumatic and accompanied by great pain, by penetration of the proboscis, and is compounded by the tendency of the worm to release its hold occasionally and reattach at another place^[12]. Heavy worm burden may cause mechanical obstruction, which may lead to mortality, especially in piglets^[9]. Severe infection may cause slow growth or emaciation, lower weight gain^[19, 9] and occasional damage of the intestine, causing mortal peritonitis.

5. Conclusion

Despite that pig husbandry and pig meat consumption are prohibited in Morocco, in accordance with Islamic instructions and traditions, and no human infection has been reported so far, it is evident that the very high relative prevalence and contamination with *M. hirudinaceus* of wild boars in the El Hajeb province poses a serious risk for human infection to farmers and residents of rural communities, in particular children, for instance through the accidental ingestion of infected intermediate hosts. Similarly, reeler who consume wild boar meat may be exposed to infection.

7. References

1. Amayour A, El Alaoui Z, Alkhali A, Hassouni T, El Kharrim K, Belghyti D. Lung parasites of the genus *Metastrongylus* Molin, 1861 (Nematoda: Metastrongilidae) in wild boar (*Sus Scrofa Barbarus*) in Middle Atlas Region of Morocco: an epidemiological study, *Journal of Research in Biology* 2016; 6(3):2020-2025.
2. Aulagnier S, Thévenot M. Catalogue des Mammifères sauvages du Maroc. Institut Scientifique. 1986; (41):163.
3. Boitani L, Mattei L. Aging Wild boar (*Sus scrofa*) by tooth eruption. In *Ongulés/Ungulates* 1992; 91:413-417.
4. De-La-Muela N, Hernandez-De-Lujan S, Ferre I. Helminths of wild boar in Spain. *J Wildl Dis.* 2001; 37:840-843.
5. Eslami A, Farsad-Hamdi S. Helminth parasites of wild boar, *Sus Scrofa*, in Iran. *J Wildl Dis* 1992; 28:316-318.
6. Foata J, Culioli JL, Marchand B. Helminth fauna of wild boar in Corsica. *Acta Parasitol.* 2005; 50:168-170.
7. Gassó D, Serrano E, Castillo-Contreras R, Aguilar XF, Cadena AC, Velarde R *et al.* Coprological tests underestimate *Macracanthorhynchus hirudinaceus* burden in wild boar. *Parasitol Res.* 2016; 115(5):2103-5. doi: 10.1007/s00436-016-4976-7.
8. Hemsrichart V, Pichyangkura C, Chitchang S, Vutichamnong U. Eosinophilic enteritis due to *Macracanthorhynchus hirudinaceus* infection: report of 3 cases. *J Med. Ass. Thailand.* 1983; 66:303-310.
9. Litty M, Sajitha IS, Ajith JG, Reghu R. *Macracanthorhynchus hirudinaceus* in a Wild Boar of Wayanad, Kerala *Indian Vet. J.* 2013; 90(11):54-56.
10. Mansouri M, Sarkari B, MOWLAVI GR. Helminth Parasites of Wild Boars, *Sus Scrofa*, in Bushehr Province, Southwestern Iran, *Iran J Parasitol:* 2016; 11(3):377-382.
11. Marquardt WC, Demaree RS, Grieve RB. *Parasitology and Vector Biology*, 2nd Edition. Academic Press, London, 2000.
12. Mowlavi GR, Massoud J, Mobedi I, Solaymani-Mohammadi S, Gharagozlou MJ, Mas-Coma S. Very highly prevalent *Macracanthorhynchus hirudinaceus* infection of wild boar *Sus scrofa* in Khuzestan province, south-western Iran. *Helminthologia.* 2006 ; 43:86-91.
13. Alaoui MY. La chasse au Maroc éditions du Cèdre (Maroc) 2008, 62.
14. Mhirit O, Blérot P. Le grand livre de la forêt marocaine Éditions Mardaga, 1999, 242.
15. Radomyos P, Chobchuanom A, Tungtrongchitr A. Intestinal perforation due to *Macracanthorhynchus hirudinaceus* infection in Thailand. *Trop Med Parasitol.* 1989; 40:476-477.
16. Rajkovic-Janje R, Bosnic S, Zagreb, Rimac D, Dragicevic P, Osijek *et al.* Prevalence of helminths in wild boar from hunting grounds in eastern Croatia *Z. Jagdwiss.* (2002) 48, 261-270.
17. Pavlović IN, Kulišić ZB, Tambur ŽŽ, Protiž NM. Scarabidae intermediate host for *Macracanthorhynchus hirudinaceus*. *Zbornik Matice Srpske Za Prirodne Nauke.* 2010; 119:89-95.
18. Rózsa L, Reiczigel J, Majoros G. Quantifying parasites in samples of hosts. *Jouranl of Parasitology.* 2000; 86(2):228-232.
19. Tarczyński S. Parasitic worms of swine and wild boars in Poland. *Acta Parasitol Pol* 1956; 4:663-780.
20. Zhong HL, Feng LB, Wang CX, Kang B, Wang ZZ, Zhou GH *et al.* Human infection with *Macracanthorhynchus hirudinaceus* causing serious complications in China. *Chin Med J-Peking* 1983; 96:661-668.