Journal of Entomology and Zoology Studies

Available online at www.entomoljournal.com

E-ISSN: 2320-7078
P-ISSN: 2349-6800
JEZS 2017; 5(3): 441-447

Received: 05-03-2017
Accepted: 06-04-2017

Duygu Fevziye Vural
Ankara University, Faculty of Science, Department of Biology, Tandogan, Ankara, Turkey

Suna Cebesoy
Ankara University, Faculty of Science, Department of Biology, Tandogan, Ankara, Turkey

Dilşad Ozerkan
Kastamonu University, Faculty of Engineering and Architecture, Department of Genetics and Bioengineering, 37100 Kastamonu, Turkey

Hatice Mutlu Eyison
Ankara University, Faculty of Science, Department of Biology, Tandogan, Ankara, Turkey

Correspondence
Duygu Fevziye Vural
Ankara University, Faculty of Science, Department of Biology, Tandogan, Ankara, Turkey

The effect of melatonine on rats gastrocnemius muscle applied with carbon tetrachloride (CCl_4)

Duygu Fevziye Vural, Suna Cebesoy, Dilşad Ozerkan and Hatice Mutlu Eyison

Abstract
In this study, it is purposed that the protective effect of the melatonine (MEL) is examined against the toxic effect of the CCl_4 to the gastrocnemius muscle. The rats were separated into 4 groups that were control groups (Group 1, Group 2), CCl_4 (Group 3) and CCl_4 + MEL (Group 4). The tissues were processed the routine preparation processing for the light microscope. The tissues were stained respectively with hematoxylin-eosin, Masson-trichrome and Periodic Acid- Schiff. When the tissues were stained with histological stains whole of the control groups was regular. When the tissues were stained with hematoxylin-eosin; and in the group (group 3), in the muscle fibers there were fusion in places, hypertrophy and orientation disorder. In the group (Group 4) was observed that the muscles were close to the control group. When the tissues were stained with the Masson-trichrome, in the group 3, it was observed that the collagen fibers were increased in the connective tissue. In the CCl_4 group which was applied the melatonine, it was observed that in the collagen fibers there were decreased. In addition to these, in PAS staining all groups were seen PAS positive.

Keywords: Gastrocnemius, fibrosis, histological stains, melatonin, carbon tetrachloride

1. Introduction

CCl_4 (carbon tetrachloride) is a colorless, non-inflammable, volatile, aromatic and intensive liquid. Although the CCl_4 is naturally available, it is not produced as chemical. Due to the stable form of the CCl_4, it disintegrates too slowly also its atmospheric half-life is approximately 30-100 years [1].

CCl_4 and other liquid halogenated hydrocarbons are used in paint and solvents, extinguishers, also used as oil repellents (detergent) as well as dry cleaning for long times [2, 3]. In addition to this, it is applied for the parasitary struggle in the veterinary medicine against the helminthes [4, 5]. The carbon tetrachloride (CCl_4) which can be taken via respiratory tract, gastrointestinal tract and transcutaneal in the body, separates to the tissues like notably river, brain, kidney, muscle, lungs and testis [6, 7]. It is indicated that this effect of it is ridden on free oxygen radicals [8]. Xenobiotic which can form the cellular damage with CCl_4 free radical production, can cause to hepatoxicity for human and animals [9-11]. CCl_4 causes to increase the lipid peroxidation production and to decrease the protective enzymes against these products. These effects are resulted in that CCl_4 is changed into the trichloromethyl and the trichloromethyl peroxide ($CCl/-CCl_3O_2$) or N-acetyl-p-benzoquinone (NAPQI) free radicals which they are most toxic with cytochrome P450 (CYP) enzyme [12]. The effects of the antioxidants are quite a few for being minimized the damage which the free radicals form in the body [13]. The melatonine which is the hormone of the pineal gland [14], its basic cell is pinealosit [15], is a strong antioxidant and sweeps up the superoxide radicals, other radical oxygen sorts (ROS) and radical nitrogen sorts. In the APUD (precursor uptake and decarboxylation) cells which are accepted that they are in the diffuse neuroendocrine, it was seen that the melatonine is synthesized. These cells take place in the retina, lachrymal glands, the other parts of brain; and bronchus, river, kidney, adrenal glands, gastrointestinal system, thymus, placenta, over, testis and endometrium. In addition to this, the mast cell synthesizes the melatonine in the leucocytes and natural killer cells [16]. Likewise, the melatonine supports the expression of the antioxidantive enzyme genes in a roundabout way; and inhibits the expression of the prooxidant gene [17]. The melatonine, also, has an impact on the activation of the antioxidantive enzymes in a roundabout way, like superoxide dismutase (SOD), catalase (CAT) and glutathione peroxidase [18, 19].

This activation is taken shape in a result of synthesizing the antioxidantive enzymes mRNA and finally by being stimulating the enzyme [20-22].

The melatonine has an amphophilic feature higher up; also, it quickly mixes with blood and body fluids without being stored in the body [23, 24]. Because of its feature, it can reach to all organelles of the cell including the nucleus; and for this reason, it more effective than the vitamin and mineral antioxidants [17]; as a result, this situation overtops to the melatonine for protecting the DNA and the cells against the oxidative damage [25-27].

Skeletal muscles include the soleus, gastrocnemius and extensor digitorum longus. The skeletal muscles can be classified as fast convulsion fibers and slow convulsion fibers, based on energy metabolisms and the characters of the fibers' spasm [28]. The gastrocnemius muscle is a thick muscle [29] which takes place in the backside of the leg that has both the fast and slow convulsive fibers [30]. The skeletal muscle fibrils of the vertebrate are three types when basing on the morphological, histochemical and functional situations; these are red, white and recess fibrils [31, 32]. The red fibrils are described as type I and slow oxidative; the white fibrils are called type IIB and fast glycolytic; the recess fibrils are called type IIA and fast oxidative [28]. The type I (red muscle) carries myoglobin which colors pink to the muscle. When the type I muscle is cramping, its speed is 17 mm per a second; and the cramping of the type II is 42 mm per a second [33]. In the type I, the blood vessels are more than the type II and they activate longer time than the type II. They are thinner than the type II and they carry mitochondria a lot. The type II fibrils cramp fast and they have bigger diameter than the others but they get tired quickly. The glycolytic enzymes of the type II are more and they carry plenty of glycogen. Because of the fact that in the type II fibrils, the oxidative metabolism is back seat, there is less mitochondria. In addition this, the type I fibrils have a great number of mitochondria in order to support the higher up oxidative metabolism [34]. Soleus has the fibers which cramp slow; the gastrocnemius has cramped fibers which are both slow and fast [30].

Fibroblasts play a significant role for healing by secreting the extracellular matrix proteins which include the collagen and growth factor for repairing when the tissues are damaged [35-37]. The skeletal muscle fibrosis is that the collagen and the other extracellular matrix proteins are produced by the muscle fibroblasts and are stored in the tissues [38]. In these researches which were studied with the carbon tetrachloride and the melatonine, it was used more river, kidney and lung. It was not histologically reached the researches about the CCl_4 and the melatonine. In this study, it was histologically examined not only the negative effect of the CCl_4 to the gastrocnemius muscle but the healing and the protective effect of the melatonine.

2. Material and Method

2.1 Laboratory Animals

In our study, 24 Wistar albino male rats taken from Gazi University Laboratory Animals Research Center and weigh in between 200-220 gr were used. The experiments were carried out at GUDAM and experiments were done from January 2013 to January 2015. Therats were fed with the Standard pellet feed in their Standard rat cages under optimal conditions. The lights were adjusted in a way to allow that there was 12 hours day and 12 hours night. Therats were weighed before starting the ten-week long study and 24 rats of 200-220 gr were randomly divided into 4 groups involving 6 in each group.

1. Group 1 (Control 1, Corn oil) The corn oil which is CCl_4 solvent was applied to the rats, in this group, for 1,5ml/kg during 4 weeks subcutaneously two times per a week for 10 weeks.
2. Group 2 (Control group, ethanol+PBS) The ethanol which is the melatonine solvent was given subcutaneously every day to this group for 1% ethanol+PBS during 10 weeks.
3. Group 3 (CCl_4) 1,5ml/kg melatonine was subcutaneously given two times per a week from the sterile CCl_4 injection, which was dissolved in the corn oil at the rate of 1:1.
4. Group 4 (CCl_4+Melatonine) since starting the CCl_4 injection, 10 mg/kg dose of the melatoine was subcutaneously given every day.

At the end of tenth week, from the all experiment groups the muscle tissues were taken out by taking intracardiac blood under ketamine/rompun anesthesia.

2.2 Histochemical examination

Some part of the striated muscle tissue was determined by being put into 10% of formol. After the determined tissues were processed the routine histological operations, they were embedded to the paraffin and the thicknesses of 5µm sections were taken out. For the histological examination the tissues were stained with the hematoxylin-eosin (HE). The fibrosis (Type I collagen) formation was shown by the Masson-Trikrom staining and the glycogen particles were shown by Periodic Acid Shift (PAS) staining.

3. Results

3.1 Hematoxylin & Eosin

When the gastrocnemius muscle tissue sections of the control group (Group 1, 2) rats were examined, it was seen that the morphological structure of the muscle cells were regular (Fig. 1a, Fig. 1b).

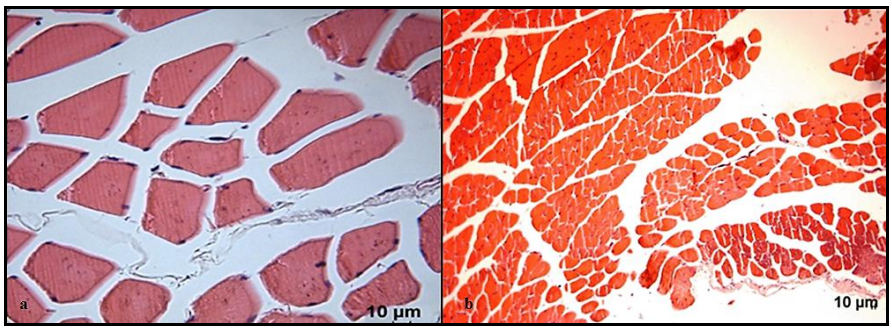

Fig 1a: The histological structure of the gastrocnemius muscle of the control group (corn oil) rat. H&E, **b.** The histological structure of the gastrocnemius muscle of the control group (PBS+ ethanol) rat. H&E

When the gastrocnemius muscle of the CCl_4 group's rats was examined, it was seen that in the muscle fibrils there was melting in places and protein loss, in the muscle tissue there was malformation and in the muscle cells there was hypertrophy (Fig. 2a, Fig. 2b, Fig. 2c)
.

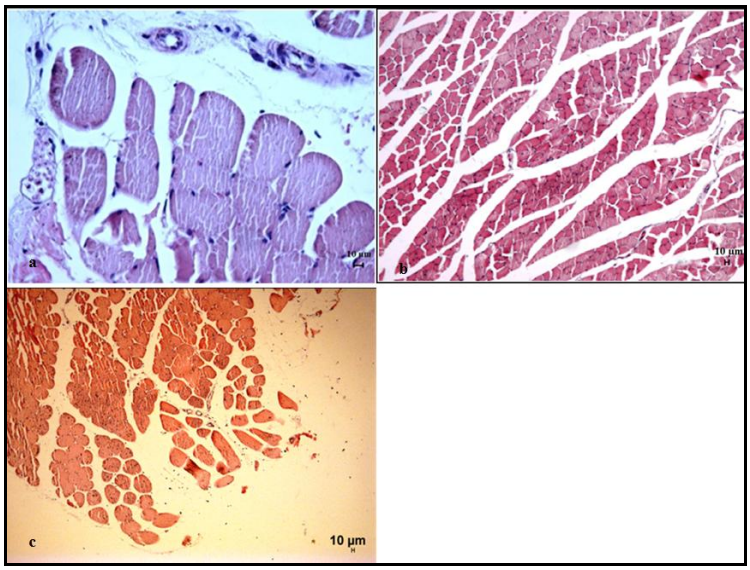

Fig 2a: Hypertrophy in the gastrocnemius muscle of the CCl_4 group rats and the melting in the fibrils. H&E. **b.** Melting (star) in the gastrocnemius muscle cells of the CCl_4 group rats and disruption in the morphological character. H&E. **c.** Hypertrophy in the gastrocnemius muscle cells of the CCl_4 group rats. H&E

When the CCl_4 groups which were applied the melatonine, were examined, it was determined that the tissue integrity was partly maintained according to the CCl_4 group, and the morphological structure of the cells was near normal (Fig. 3)

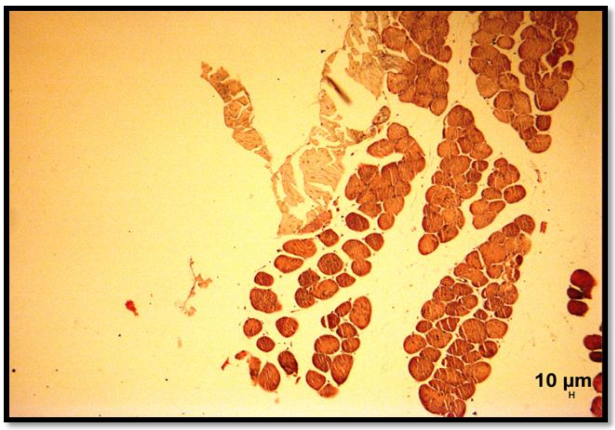

Fig 3: The gastrocnemius muscle cells of the applied melatonine to the CCl_4 group rats follow an outlook near normal.

3.2 Masson-Trikrom

The muscle cell nucleus was black, which was stained with the Masson-Trikrom, the collagen fibers were stained with blue. In the control group, the collagen fibers were at the normal level (Fig. 4a, Fig. 4b).

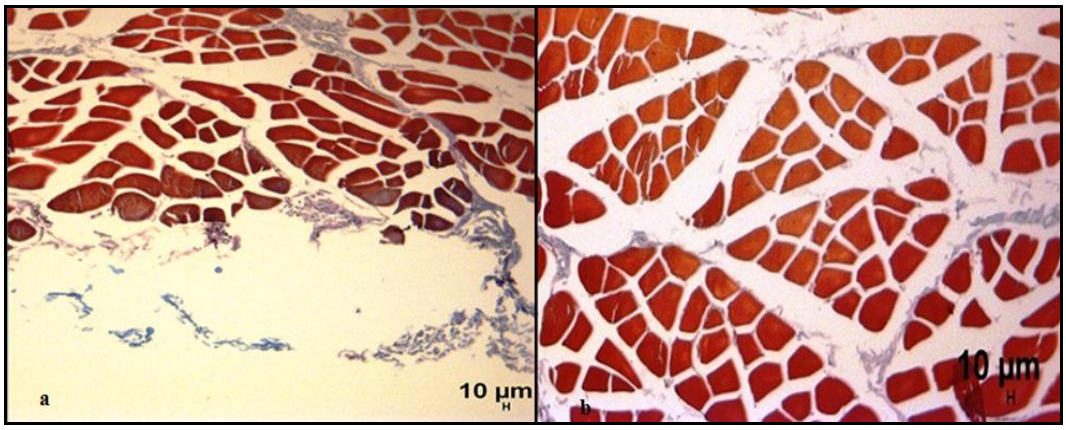

Fig 4 a: Connective tissue in the gastrocnemius muscle of the control group (corn oil) rat. Masson-Trikrom, **b.** Connective tissue in the gastrocnemius muscle of the control group (PBS+ ethanol) rat. Masson-Trikrom

It was seen that in the group which was applied the CCl_4, the fibrosis was around the nerve plexus, in the muscle cells there were orientation disorder and the hypertrophy (Fig. 5a, Fig. 5b).

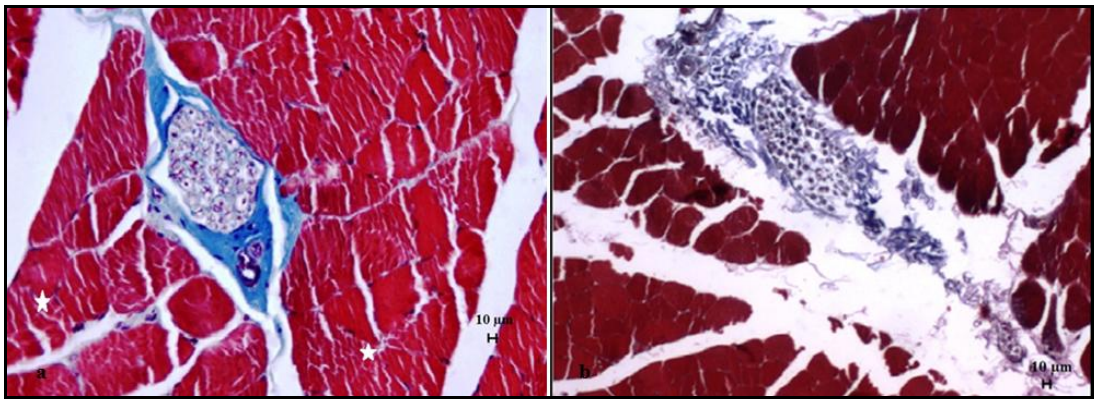

Fig 5 a: The fibrosis around the nerve plexus in the gastrocnemius muscle of the CCl_4 group rat, the orientation disorder and the contractile protein loss (star). Masso-Trikrom **b.** The fibrosis around the nerve plexus in the gastrocnemius muscle of the CCl_4 group rat, the orientation disorder and the melting in the fibrils. Masso-Trikrom

When the CCl_4 groups which were applied the melatonine, were examined, it was determined that the tissue integrity was partly maintained according to the CCl_4 group, and decreasing in the collagen fiber and decreasing around the blood vessel in the fibrosis (Fig. 6a, Fig. 6b).

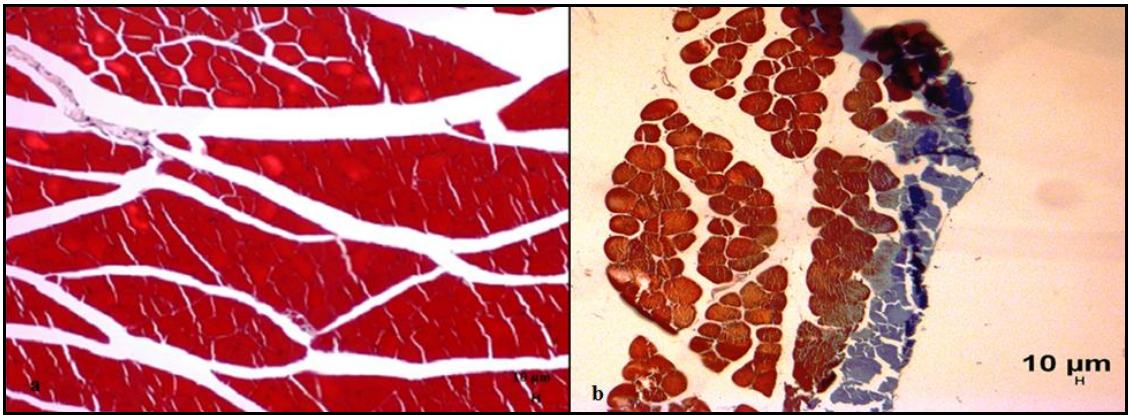

Fig 6 a: Gastrocnemius muscle belonging to CCl_4+melatonine. Masson – Trikrom **b.** Decreasing of the collagen fiber in the CCl_4 group rat's gastrocnemius muscle in the applied melatonine and the view of tissue near normal. Masson–Trikrom

3.3 Periodic Acid-Schiff (PAS)

It was observed that all groups reacted PAS positive when the gastrocnemius muscle tissue of the rats were examined in the control groups (Group 1, 2). In the control groups, it was seen that the connective tissue was at normal level; the cores were more than one and in near; the cells were at normal size and the tissue integrity occurred (Fig. 7a, Fig. 7b).

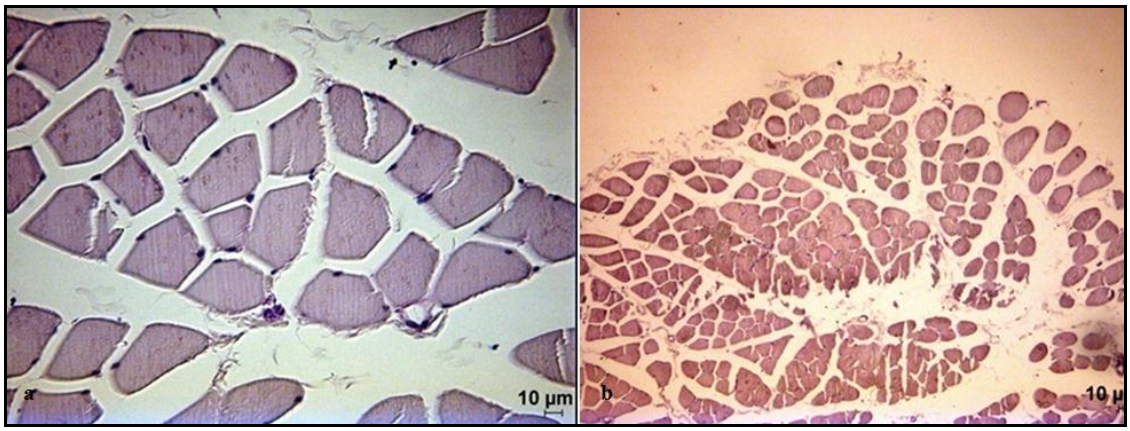

Fig 7a: Control group (corn oil) rat's gastrocnemius muscle is PAS positive. PAS **b.** Control group (PBS+ ethanol) rat's gastrocnemius muscle is PAS positive. PAS

When the groups which were applied the CCl_4 were examined it reacted PAS positive; nevertheless it was observed that in the muscle fibrils there were melting in places and hypertrophy (Fig. 8a, Fig. 8b).

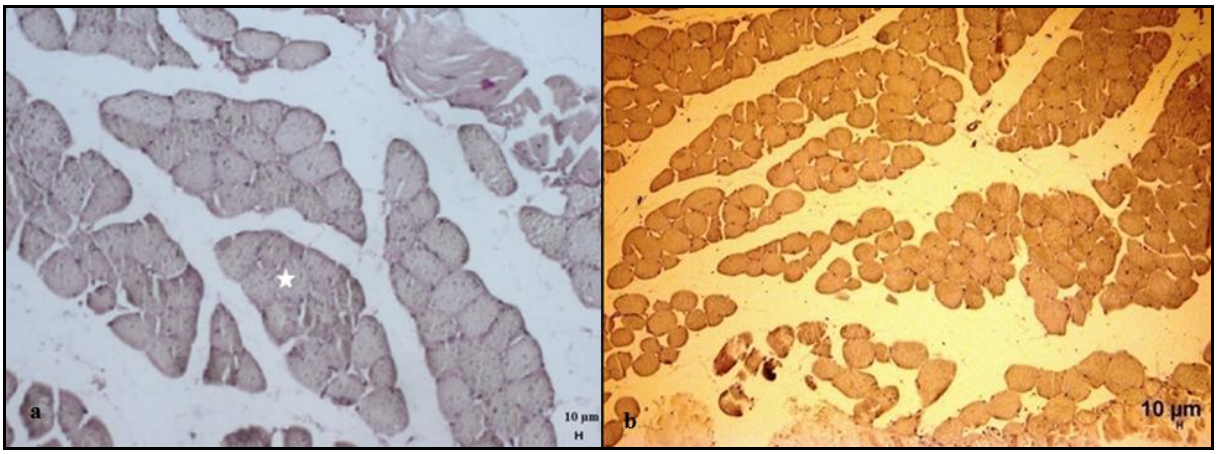

Fig 8 a: Rat's gatsrocnemius muscle applied to the CCl_4 is PAS positive and the melting in muscle fibrils (star). PAS **b** Rat's gastrocnemius muscle applied to the CCl_4. PAS

When the CCl_4 groups which were applied to the melatonine were examined, they were reacted Pas positive. It was observed the decreasing in the collagen fiber and the near normal scene in the muscle fibrils as far as the group with the CCl_4 (Fig. (17), Fig. (18).

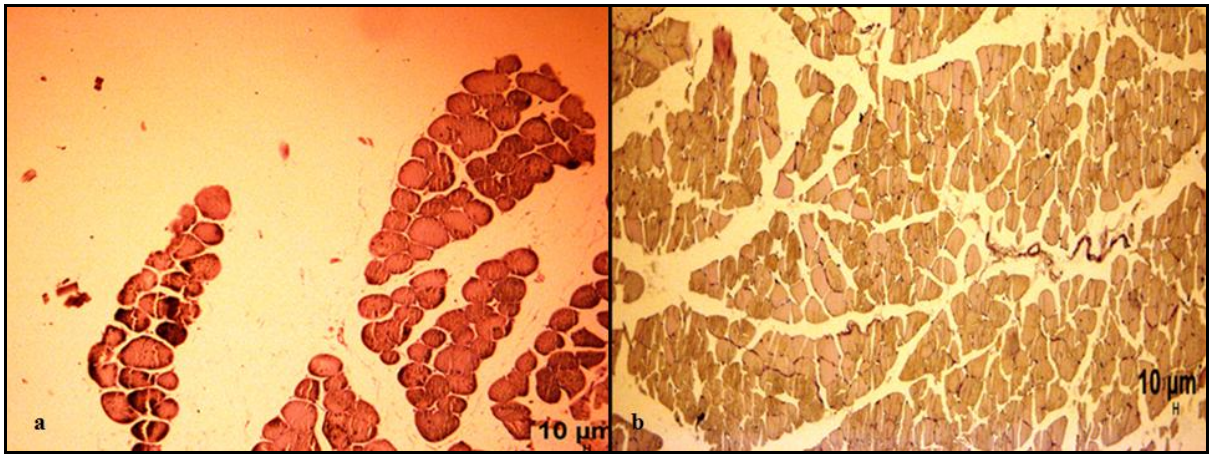

Fig 9 a: Partly recovery in the gastrocnemius muscle belonging to the CCl_4+melatonine group, near normal scene. PAS **b.** Decreasing in the collagen fiber in the gastrocnemius muscle belonging to the CCl_4+melatonine group, near normal scene. PAS

4. Discussion

CCl_4, which is frequently used in the industry and agriculture, is a chemical that is well known its hepatoxicity and nephrotoxicity [6].

The reactive oxygen products, which are appeared during "oxidative stress" cause that the cellular proteins release and these proteins escape to the vein surface by making way the deterioration, degeneration, necrosis of the muscle fibrils' spasm and organization; the vascular endothelium cell swelling; and the increasing of the micro vascular permeability [39, 40]. Cetin and Cetin [41] did oxidative damage to the rats with CCl_4 in their brains and kidneys; and they observed the increasing of MDA and NO levels in these tissues, and the decreasing in the SOD and CAT activities; in addition to these, they did not observe any noticeable change in the GPx activity.

Miyazaki *et al*., [42] applied the CCl_4 to the rats during 10 weeks and took blood tissue, brain tissue, liver tissue and skeletal muscle tissue of these rats; and researched the effect of the CCl_4. They also observed that CCl_4 created the fibrosis in these tissues. Differently from our study, they showed the muscle analyses as biochemical.

Vural *et al*., [43] applied the CCl_4 to the Wistar albino rats during 12 weeks and took their soleus muscles at the end of 12 weeks and they histologically examined these. As a result of these, they observed the hypertrophy in the muscles, the orientation disorder and the fibrosis in the muscles cells. In analogy to these studies, in comparison to the control groups, it was observed the hypertrophy in the muscle, the orientation disorder in the muscle cells and the increasing of the collagen fibers around the nerve plexus in our study. Moreover, it was seen the melting in the fibrils.

The melatonine which is a pineal gland hormone that is a neuroendocrine organ, [44] is a strong and effective endogen radical collector.

Kus and his friends reported that the damage was decreased which occurred in the kidney and the liver after the intoxication created from CCl_4 as a result of the studies with the melatonine. Erdem *et al*., [45] histologically and biologically researched the antioxidant protective effect of the melatonine on the skeletal muscles of the Wistar albino rats which created the acut ischemia-reperfusion (I/R) injury. As a consequence, they emphasized the protective effect of the melatonine.

Karaca *et al*., [46], in their study with Wistar-Albino major male rats, applied the CCl_4 to this group and applied the CCl_4+melatonine to the other group during one month. Consequently, it was seen an intensive coloration which showed the heat shock protein 70 (hsp70) immunoreactions in the liver as a result of CCl_4 toxicity. The researchers determined that the detrimental effect, occurred in the liver as a result of the CCl_4 exposition was prevented by the

melatonine hormone thereby being confirmed the minimal hsp70 coloration in the river tissue sections belonging to the rats injected the melatonine with the CCl_4 exposition.

Vural *et al*., [43] applied the CCl_4 and the melatonine to the Wistar albino rats during 12 weeks and at the end of 12 weeks, took the soleus muscles and histologically examined these muscles. As a consequence, in comparison to the applied the CCl_4 group, it was observed that the tissue integrity was maintained and the collagen fibers around the blood vessel were decreased. The researchers emphasized the damage inhibitor effect as well the protective effect of the melatonine. In comparably our study, in the group which was applied the melatonine, it was observed the decrease in the collagen fibers and the tissue integrity near the control group. It was succeeded a scene which was near the normal with decreasing in melting occurred in the muscle fibrils.

Vural *et al*., [43] studied the CCl_4 effect to the soleus muscle. As is known, the soleus is a slow-twitch muscle. If it is compared to this study, we can say that the gastrocnemius muscle is more affected from the CCl_4 than soleus muscle. Accordingly, it can be said that the healing effect of the melatonine in the soleus is more than the gastrocnemius.

5. Declarations

Acknowledgements

We would like to thank Prof. Dr.K.Gonca AKBULUT and Doç. Dr. Şevin Güney Department of physiology Faculty of Science-Gazi University, for experimenting this study.

Competing interests

The authors declare that they have no competing interests.

Ethics approval and consent to participate

This study was carried out at Gazi University Faculty of Medicine Department of Physiology with the decision of ethical committee dated 17.01.2012 and coded G.Ü ET-12.010.

Funding

The authors declare that there is no funding for this research.

6. References

1. Pope AM, Rall DP. Institute of Medicine. (Eds.) Environmental Medicine. National Academy Press, Washington D.C. USA, 1995.
2. Maianskii DN, Kutina SN. Characteristics of the development of acute hepatitis in rats stimulated with prodigiozan. Biull Eksp Biol Med. 1979; 87:622-624.
3. Çınar A, Yörük M, Meral İ, Kalp D, Koç A, Ertekin A. Karbon tetraklorür (CCl4) ile tavşanlarda deneysel olarak oluşturulan akut ve kronik intoksikasyonun karaciğerin histolojik yapısına, bazı hematolojik değerlere ve elektrokardiyogram üzerine etkileri. Turk J Vet Anim Sci. 1999; 23:235-242.
4. Adams HR. Veterinary Pharmacology and Therapeuties. 7th Edition. Iowa State University Press/AMES, 1995.
5. Kaneko T, Wang PY, Sato A. Relationship between blood/air partition coefficients of lipophilic organic solvent and blood triglyceride levels. Toxicol. 2000; 143:203-208.
6. Abraham P, Wilfred G, Cathrine SP. Oxidative damage to the lipids and proteins pf the lungs, testis and kidney of rats during carbon tetrachloride intoxication. Clin Chim Acta. 1999; 289:177-179.
7. Tirkey N, Pilkhwal S, Kuhad A, Chopra K. Hesperidin, a citrus bioflavonoid, decreases the oxidative stres produced by carbontetrachloride in rat liver and kidney. BMC Pharmacol Toxicol. 2005; 5:2.
8. Ogeturk M, Kus I, Colakoglu N, Zararsiz I, Ilhan N, Sarsilmaz M. Caffeic acid phenethyl ester protects kidneys against carbon tetrachloride toxicity in rats. J Ethnopharmacol. 2005; 97:273-280.
9. Leon OS, Menendez S, Merino N, Castillo R, Sam S, Perez L *et al*. Ozone Oxidative Precontioning a Protection Cellular Damage by Free Radicals. Mediators Inflamm. 1998; 7:289.
10. Mansour MA. Protective Effects of Thymoquinone and desferrioxamine against hepatotoxicity of carbon tetrachloride in mice. Life Sci. 2000; 66(26):2583-2591.
11. Kuş I, Çolakoğlu N, Pekmez H, Seçkin D, Öğeturk M, Sarsılmaz M. Protective effects of caffeic acid phenethly ester (CAPE) on carbon tetrachloride induced hepatotoxicity in rats, Acta Histochem. 2004; 106:289-297.
12. Ogeturk M, Kus I, Kavakli A, Oner J, Kukner A, Sarsilmaz M. Reduction of carbon tetrachloride-induced nephropathy by melatonin administration. Cell Biochem. Funct. 2005; 23:85-92.
13. Valko M, Rhodes CJ, Moncol J, Izakovic M, Mazur M. Free radicals, metals and antioxidants in oxidative stress-induced cancer. Chem Biol Interact. 2006; 160:1-40.
14. Lerner AB, Case JD, Takahashi Y, Lee TH, Mori W. Isolation of melatonin, the pineal gland factor that lightens melanocytes. J American Chem Soc. 1958; 80:2587.
15. Arendt J. The Pineal Gland: Basic Physiology and Clinical Implications. In: DeGROOT LJ, eds. Endocrinology. 3rd. ed. Philadelphia: W.B. Saunders. 1995, 433-42.
16. Altun A, Vardar A, Altun BU. Melatonin ve Kardiyovasküler Sistem. Anatol J Cardiol. 2001; 1:283-288.
17. Reiter RJ, Calvo JR, Karbownik M, QI W Tan DX. Melatonin and its relation to the immune system and inflammation. Ann. N. Y. Acad. Sci. 2000; 917:376-386.
18. Barlow-Walden LR, Reiter RJ, Abe M, Pablos M, Menendez-Pelaez A, Chen LD *et al*. Melatonin stimulates brain glutathione peroxidase activity. Neurochem. Int. 1995; 26:497-502.
19. Antolin I, Rodriguez C, Sainz RM, Mayo JC, Uría H, Kotler ML *et al*. Neurohormone melatonin prevents cell damage: effect on gene expression for antioxidant enzymes. FASEB J. 1996; 10:882-890.
20. Pablos MI, Reiter RJ, Ortiz GG, Guerrero JM, Agapito MT, Chuang JI *et al*. Rhythms of glutathione peroxidase and glutathione reductase in brain of chick and their inhibition by light. Neurochem. Int. 1998; 32:69-75.
21. Mayo JC, Sainz RM, Antolin I, Herrera F, Martin V, Rodriguez C. Melatonin regulation of antioxidant enzyme gene expression. Cell. Mol. Life Sci. 2002; 59:1706-1713.
22. Coto-Montes A, Tomas-Zapico C, Escames G, León J, Tolivia D, JosefaRodríguez-Colunga M *et al*. Characterization of melatonin high-affinity binding sites in purified cell nuclei of the hamster (Mesocricetus auratus) Harderian gland. J Pineal Res. 2003; 34:202-207.
23. Brzezinski A. Melatonin in humans. N. Engl. J Med. 1997; 336:186-95.
24. Reiter RJ. Melatonin. The chemical expression of

darkness. Mol. Cell. Endocrinol. 1991; 79:153-158.
25. Guerrero JM, Reiter RJ. A brief survey of pineal glandimmune system interrelationships. Endocrine res. 1992; 18:91-113.
26. Arendt J. Melatonin. Clin. Endocrinol. 1988; 29:205-209.
27. Kuş İ, Sarsılmaz M. Pineal bezin morfolojik yapısı ve fonksiyonları. Türkiye Klinikleri Tıp Bilimleri Dergisi. 2002; 22:221-226.
28. Brooke MH, Kaiser KK. Three myosin adenosine triphosphatase' system: the nature of their pH liability and sulfhydryl dependence. J histochem & cytochem. 1970; 18:670-2.
29. Dursun N. Veneriner Anatomi I. Metisan yayınevi. Ankara. 10. Edition. 2006, 276.
30. Suwa M, Miyazaki T, Nakamura T, Sasaki S, Ohmori H, Katsuta S. Hereditary dominance of fast-twitch fibers in skeletal muscles and relation of thyroid hormone under physiological conditions in Rats. Acta anat. 1998; 162:40-5.
31. Lawrie RA. The activity of the cytochrome system in muscle and its relation to myoglobin. The Biochem journal. 1953a; 55(2):298-305.
32. Lawrie RA. The relation of energy-rich phosphate in muscle to myoglobin and to cytochrome-oxidase activity. The Biochem journal. 1953b; 55(2):305-309.
33. Noyan A. Kas fizyolojisi. Fizyoloji. 6. Edition. 1989, 384-419.
34. Guyton AC, Hall JE. Textbook of Medical physiology. 9. Ed. W. B. Saunders. London, 1966.
35. Bischoff R. In Myology (Engel, A. G., and Franzini-Armstrong, C., eds) 2nd Ed., McGraw-Hill, New York, 1994, 97-118.
36. Kääriäinen M, Järvinen T, Järvinen M, Rantanen J, Kalimo H. Relation between myofibers and connective tissue during muscle injury repair. Scand J Med Sci Sports. 2000; 10:332-337.
37. Huard J, Li Y, Fu FH. Muscle injuries and repair: current trends in research. J Bone Joint Surg. 2002; 84:822-832.
38. Li ZB, Kollias HD, Wagner KR. Myostatin directly regulates skeletal muscle fibrosis. J biol chem. 2008; 283(28):19371-19378.
39. Erkanli K, Kayalar N, Erkanli G, Ercan F, Sener G, Kirali K. Melatonin protects against ischemia/reperfusion injury in skeletal muscle. J Pineal Res. 2005; 39:238-42.
40. Ozyurt H, Ozyurt B, Koca K, Ozgocmen S. Caffeic acid phenethyl ester (CAPE) protects rat skeletal muscle against ischemia-reperfusion-induced oxidative stress. Vascul Pharmacol. 2007; 47:108-12.
41. Çetin E, Çetin N. Sıçanlarda Karbon Tetraklorür ile Oluşturulan Oksidatif Beyin ve Böbrek Hasarına Karşı Grelinin Koruyucu Etkisi. Atatürk Üniversitesi Vet. Bil. Derg 2011; 6(3):195-200.
42. Miyazaki T, Matsuzaki Y, Ikegami T, Miyakawa S, Doy M, Tanaka N *et al*. The harmful effect of exercise on reducing taurine concentration in the tissues of rats treated with CCl_4 administration. J gastroenterol. 2004; 39(6):557-62.
43. Vural F, Ozerkan D, Cebesoy, Ozsoy N, Elmubarak S. Karbontetraklorür uygulanmış sıçan soleus kası üzerine melatoninin etkisi. 1. Zooloji Kongresi 28-31 Ağustos, Nevşehir Üniversitesi, Bildiri Özetleri Kitabı, Nevşehir, 2013; 37,
44. Erlich SS, Apuzzo MLJ. The pineal gland: anatomy, physiology and clinical significance. J Neurol. 1985; 63:321-341.
45. Erdem M, Bostan B, Güneş T, Özkan F, Şen C, Özyurt H *et al*. Melatonin iskelet kası iskemi- reperfüzyon yaralanması üzerine koruyucu etkisi. Joint Diseases and Related Surgery 2010; 21(3):166-171.
46. Karaca Ö, Pekmez H, Kuş MA, Akpolat N, Ögetürk M, Kuş İ. Deneysel Karbon Tetraklorür Toksisitesi Sonucu Karaciğerdeki IŞP70 İmmunoreaksiyon Artışı Üzerine Melatonin Hormonunun Etkisi. F.Ü.Sağ. Bil.Tıp Derg. 2011; 25(2):73-76.