



E-ISSN: 2320-7078

P-ISSN: 2349-6800

JEZS 2017; 5(4): 1420-1423

© 2017 JEZS

Received: 11-05-2017

Accepted: 12-06-2017

Koushik Kakoty

Senior Research Fellow, Division of Animal Health, ICAR-RC for NEH Region, Umiam, Meghalaya, India.

Poznur Hussain

Assistant Professor, Department of Veterinary Public Health, College of Veterinary Science, Khanapara, Assam, India

Saidul Islam

Professor, Department of Parasitology, College of Veterinary Science, Khanapara, Assam, India

Razibuddin Ahmed Hazarika

Assistant Professor, Department of Veterinary Public Health, College of Veterinary Science, Khanapara, Assam, India

Gouranga Mahato

Professor, Department of Preventive Medicine and Epidemiology, College of Veterinary Science, Khanapara, Assam, India

Manoj Kumar Kalita

Senior Research Fellow, Division of Animal Health, ICAR-RC for NEH Region, Umiam, Meghalaya, India.

Correspondence**Koushik Kakoty**

Senior Research Fellow, Division of Animal Health, ICAR-RC for NEH Region, Umiam, Meghalaya, India.

Detection of *Cysticercus cellulosae* in slaughtered pigs through meat inspection and confirmation by PCR assay

Koushik Kakoty, Poznur Hussain, Saidul Islam, Razibuddin Ahmed Hazarika, Gouranga Mahato and Manoj Kumar Kalita

Abstract

A total of 316 pig carcasses were examined through meat inspection in different market places of Sivasagar district of Assam, India for a period of one year from April 2015 to May 2016. Out of which, 4 (1.27%) were found positive for porcine cysticercosis with visible cysts. The highest density of *Cysticercus cellulosae* was found $(11.40 \pm 0.67) \times (4.8 \pm 0.58)$ mm in skeletal muscles. Polymerase chain reaction (PCR) assay was performed to confirm *Cysticercus cellulosae* and to validate the results of meat inspection. Oligonucleotide primers targeting against the large subunit rRNA gene (TBR primers) of *Taenia solium* were used in this study. On reactivity in PCR test, the TBR primers yielded products of 286bp in cysticercosis positive cases.

Keywords: Pig, *Cysticercus cellulosae*, PCR, *Taenia solium*

1. Introduction

Porcine cysticercosis, the metacestode (*Cysticercus cellulosae*) stage of *Taenia solium* is a neglected^[1] and an underrated zoonotic disease involving man and pig. In the transmission and maintenance of human taeniosis and cysticercosis, porcine cysticercosis plays a crucial role^[2]. In Indian context, culture, traditions, customs and taboos influence meat consumption to a great extent especially in the rural societies. Pork is considered as a traditional food item in north eastern states of India^[3]. North East India has much higher pork consumption than the rest of the country. The demand for pork was increasing along with prices in both Assam and Nagaland according to the traders. Thus, accurate inspection of pork is very important^[4].

Although the pork consumption is highest in North East India but the scientific procedure of meat inspection is still lacking. While meat inspection is the preferred diagnostic tool to detect heavily infected carcasses but it is not reliable in detecting lightly infected carcasses^[5]. Moreover, meat inspection requires expertise of the meat inspector; otherwise cysticerci may be confused with *T. hydatigena* cysticerci^[6], hydatid cysts^[7] and left over of muscle fasciae^[8]. To overcome such type of difficulties application of molecular tools like Polymerase chain reaction (PCR) can be effective in validation of meat inspection results^[9].

So considering the public health significance of the disease, the present study aimed at estimating the prevalence of porcine cysticercosis in slaughtered pig through meat inspection and PCR for validation of results.

2. Materials and methods

2.1 Study area: A study on prevalence of porcine cysticercosis was conducted for a period of one year from April 2015 to May 2016 in different market places of Sivasagar district of Assam, India.

2.2 Sample collection: A total of 316 pig carcasses were examined as per the standard method^[10] for the presence of *Cysticercus cellulosae* from different market places of Sivasagar district. Fifty gram (g) of tissue each from brain, tongue, liver and skeletal muscles of infected pig carcasses were brought to the laboratory in ice-box to study the density of cyst.

A total of 5 numbers of cysts from each of brain, tongue, liver and skeletal muscles from 6 infected pig carcasses were taken; their length and breadth were measured and recorded to study the dimension of the cyst.

2.3 Extraction of DNA from samples

Extraction of DNA from cysts/suspected lesion was made possible using a commercially available QIAamp tissue kit (QIAGEN, Hilden, Germany) according to the manufacturer's instructions [11]. Briefly, 200 µl of cyst/lesion homogenate, 20 µl of proteinase K stock solution, and 200 µl of lysing buffer were pipetted into 1.5 ml eppendorf tube. The mixture was incubated at 37 °C for 1 h and then at 70 °C for 30 min before the addition of 200 µl of absolute alcohol and mixing by vortexing. The mixture was then transferred to the QIAamp spin column placed in a clean 2 ml collection tube and centrifuged at 8000 RPM in MiniSpin centrifuge (Eppendorf, Wesseling-Berzdorf, Germany) for 1 min at room temperature. The QIAamp spin column was washed twice with 500 µl of the washing buffers by spinning for 1 min. The QIAamp spin column was placed in a clean 1.5 ml eppendorf tube and the DNA was eluted with 100 µl of elution buffer preheated at 70 °C. Maximum DNA yield was obtained by spinning at 12,000 rpm for 1 min at room temperature. From the suspended nucleic acid 5 µl was used in the PCR amplification. The extracted DNA was quantified using spectrophotometer at 260 nm wave length.

2.4 Oligonucleotide primers

The oligonucleotide primers specific to *T. solium* were adopted from already published sequences. The primers TBR-3 (5'-GGC TTG TTT GAATGG TTT GAC G-3) and TBR-6 (5'-GCT ACTACA CCT AAA TTC TAA CC-3) against large subunit rRNA gene [12].

2.5 PCR amplification and detection of PCR product

The PCR reaction was performed in a thermal cycler (Eppendorf, Hamburg, Germany) in 20 µL volume containing 2 µl DNA sample (100 ng/ µl), 1 µl (10 pmol) of each forward and reverse primer, 10 µL of DreamTaq Green PCR Master Mix (2X) (Thermo Scientific™, USA) and 7 µL of nuclease free water (Thermo Scientific™, USA). A total of 40 PCR cycles were run with the following conditions: one initial denaturation cycle at 94°C for 3 min, followed by 40 repeated cycles with temperatures at 94°C for 30 s (denaturation), 59°C for 30 s (annealing, specific for primers) and 72°C for 1 min. After the final cycle, the preparations were kept at 72°C for 5 min for final elongation, and the PCR products were stored at 4°C in thermal cycler for further use [9]. Five microliters of PCR amplicons was analyzed on ethidium bromide stained 2% agarose gel (In Genius Gel documentation system, Syngene, UK). The sizes and quantities of PCR products were verified by comparison with a 100 bp plus quantitative ladder (Thermo Scientific™, USA).

2.6 Statistical Analysis

The Statistical Analysis of data was done using SAS System (version 4.2)

3. Results

All the 316 pigs inspected at slaughter were from different parts of Sivasagar district of Assam, India. Cysts from 4 cysticercosis positive carcasses (identified by visual meat inspection) were collected. Density of *C. cellulosae* per 50 g of tissue each from brain, tongue, liver and skeletal muscles of 4 infected pig carcasses was recorded. Highest density (25.25±5.25) of cyst was found in skeletal muscle and lowest (6.5±2.50) in tongue.

The genomic DNA from all samples (n=6) were subjected for PCR assay targeting large subunit rRNA gene with a

molecular sizes of 286 bp. All DNA samples extracted from 4 cysticercosis positive pigs, identified as viable cysts at meat inspection were also confirmed as *C. cellulosae* by PCR assay.

4. Discussion

The present study was undertaken to assess the prevalence of porcine cysticercosis in slaughtered pigs. The study revealed overall 1.26% (4/316) prevalence of porcine cysticercosis in the district which is however in contrast to the previous authors. Prevalence of porcine cysticercosis was previously recorded 20.80% and 11.90% from Assam by Deka *et al.* [13] and Plain [14]. Thereafter, Borkataki *et al.* [15] studied the prevalence of porcine cysticercosis in Nagaon, Morigaon and Karbi Anglong district of Assam for a period of one year from March 2002 to February 2003 and recorded 7.55%, 8.20% and 13.70% infection, respectively. The lower prevalence rate of porcine cysticercosis might be due to better managerial practices under which pigs are being reared and awareness of the people about the disease entity.

In the present study, density of the cysts per 50g of tissue each from brain, liver, tongue and skeletal muscles of 4 infected pig carcasses were recorded. The highest Mean ± SE of cyst was found in skeletal muscles (25.25±5.25) and lowest in tongue (6.5±2.50). Similar observations were made by other workers [16-18]. This might be attributed to ecology of the parasite, particularly in skeletal muscle they get more surface area to proliferate compared to the other organs.

The prevalence of porcine cysticercosis is either under estimated due to poor efficiency of visual meat inspection or overestimated through misdiagnosis of other morphological alterations in affected muscles, as the meat safety system is based only on conventional post-mortem inspection at slaughterhouse. Therefore, molecular diagnostics have been considered for validation of macroscopic diagnosis of ambiguous lesions as these tests were reported to be highly specific and sensitive [19-21]. Identification of *T. solium* cysticerci from the infected pig carcasses and suspected carcasses was based on amplification of large subunit rRNA gene (TBR) gene with a product size of 286 bp. All the positive cases show positive amplification of TRB gene. Dalmaso *et al.* [22] extracted DNA from degenerated and calcified cysts/lesions and found positive amplification for TRB gene. Lino Junior [23] also reported the importance of PCR test with TBR primers as a reliable method for detection of cysticerci in tissues from human autopsies that are in advanced evolutive stages.



Fig 1: Selling of *Cysticercus cellulosae* infected pig carcass in a local market of Sivasagar district

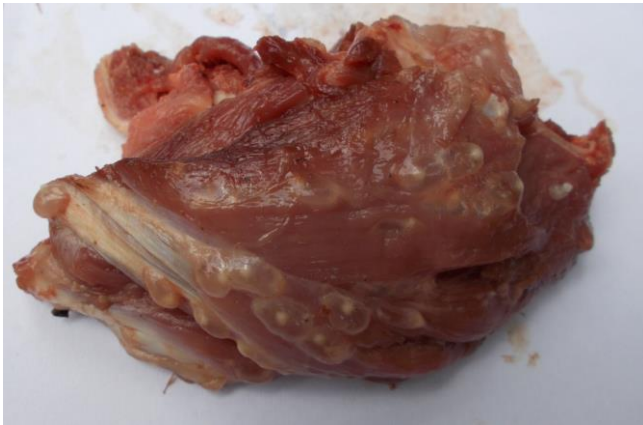

Fig 2: Cysts of *Cysticercus cellulosae* in skeletal muscle of thoracic region of pig carcass

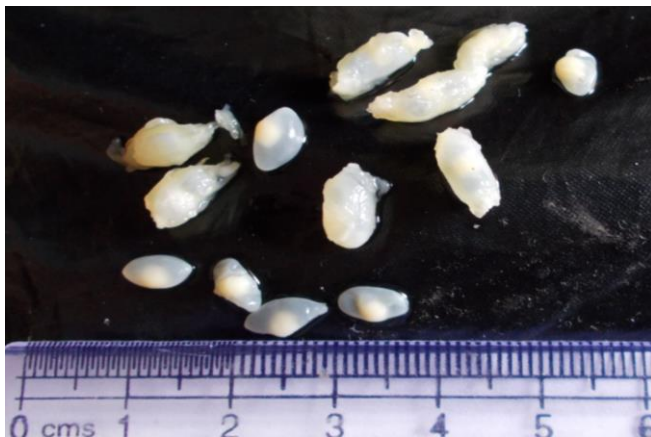

Fig 3: Cysts of *Cysticercus cellulosae* collected from tissue samples

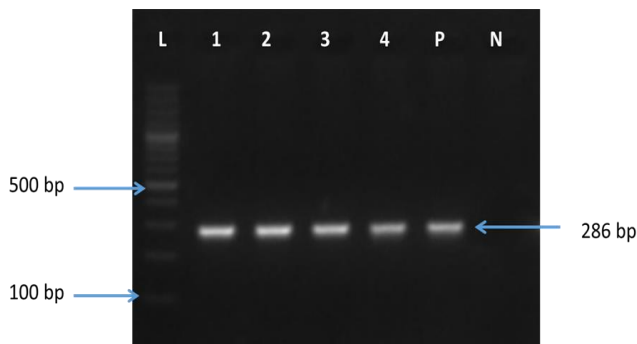


Fig 4: PCR assay with TBR primers to detect *Cysticercus cellulosae* from pig carcasses. Lane L: 100-bp DNA ladder; Lane 1 to 4: DNA samples extracted from cysticercosis positive pigs. Lane P: Positive control and Lane N: Negative control

5. Conclusion

In the present study, the prevalence of porcine cysticercosis in slaughtered pigs was recorded 1.26%. To control transmission and maintenance of human taeniosis and cysticercosis detection of porcine cysticercosis plays a crucial role. Along with the visual meat inspection, PCR assay is proved to be a successful tool for confirmation of postmortem diagnosis of porcine cysticercosis.

6. Acknowledgments

Authors acknowledge the Division of Animal Health, ICAR-RC for NEH Region, Umiam, Meghalaya, India for providing all their facilities.

7. Reference

1. Willingham III AL, Harrison LJ, Fevre EM, Parkhouse

ME. Inaugural meeting of the cysticercosis working group in Europe. *EID J Home*. 2008; 14(12).

2. Pinto PSA, Vaz AJ, Germano PML, Nakamura PM. ELISA test for the diagnosis of cysticercosis in pigs using antigens of *Taenia solium* and *Taenia crassiceps* cysticerci. *Revista do Instituto de Medicina Tropical de Sao Paulo*. 2000; 42(2):71-79.

3. Anonymous. 2012 Pork meat in India. [www.g-e-f.a.de/fileadmin/termine.../ PORK_MEAT_IN_INDIA_-_Report.pdf](http://www.g-e-f.a.de/fileadmin/termine.../PORK_MEAT_IN_INDIA_-_Report.pdf).

4. García HH, Gonzalez AE, Evans CAW, Gilman RH. *Taenia solium* cysticercosis. *Lancet*. 2003; 362(9383):547-556.

5. Cai XP, Zheng YD, Luo XN, Jing ZZ, Hu ZM, Lu CP. Immunodiagnosis of cysticercosis in China. *The Journal of Applied Research*. 2006; 6(1):69-76.

6. Kedra AH, Tkach VV, Swiderski Z, Pawowski Z. Intraspecific variability among NADH dehydrogenase subunit I sequences of *Taenia hydatigena*. *Parasitology International*. 2001; 50:145-148.

7. Deplazes P, Grimm F, Sydler T, Tanner I, Kapel CMO. Experimental alveolar echinococcosis in pigs, lesion development and serological follow up. *Veterinary Parasitology*. 2005; 130:213-222.

8. Geysen D, Kanobana K, Victor B, Rodriguez-Hidalgo R, De Borchgrave J, Brandt J *et al.* Validation of meat inspection results for *Taenia saginata* cysticercosis by PCR restriction fragment length polymorphism. *Journal of Food Protection*. 2007; 70(1):236-240.

9. Sreedevi C, Hafeez M, Kumar PA, Rayulu VC, Subramanyam KV, Sudhakar K. PCR test for detecting *Taenia solium* cysticercosis in pig carcasses. *Tropical Animal Health Production*. 2012; 44:95-99.

10. Thorton H, Gracey JF. *Textbook of Meat Hygiene*. 6th ed. London, Bailliere and Tindall, 1974.

11. Kolesarova M, Herich R, Levkut Jr M, Curlik J, Levkut M. Suitability of different tissue fixatives for subsequent PCR analysis of *Cysticercus ovis*. *Helminthologia*. 2012; 49(2):67-70.

12. Jardim EAGV, Linhares GFC, Torres FAG, Araujo JLB, Barbosa SM. Diferenciação específica entre *Taenia saginata* e *Taenia solium* por ensaio de PCR e duplex-PCR. *Ciencia Rural*, Santa Maria. 2006; 36(1):166-172.

13. Deka DK, Borkakoty MR, Lahkar BC. Cysticercosis in domestic animals in North Eastern region of India. *Indian Journal of Parasitology*. 1985; 9:83-85.

14. Plain B. Studies on the incidence of cysticercosis in pig and cattle with special reference to taeniasis in human being in Assam and Meghalaya. M.V.Sc, Assam Agricultural University, Assam, India, 1991.

15. Borkakati S, Islam S, Borkakati MR, Goswami P Deka DK. Prevalence of porcine cysticercosis in Nagaon, Morigaon and Karbianglong district of Assam, India. *Veterinary World*. 2012; 5:86-90.

16. Boa ME, Kassuku AA, Willingham AL, Keyyu JD, Phiri IK, Nansen P. Distribution and density of cysticerci of *Taenia solium* by muscle groups and organs in naturally infected local finished pigs in Tanzania. *Veterinary Parasitology*. 2002; 106:155-164.

17. Sharma R, Sharma DK, Juyal PD, Rani A, Sharma JK. Seroprevalence of swine cysticercosis in Ludhiana. *Journal of Veterinary Parasitology*. 2005; 19:143-145.

18. Biu AA, Ijudai J. Prevalence and morphometric studies

- on porcine cysticercosis in Adamawa State, Nigeria. Sokoto Journal of Veterinary Sciences. 2012; 10(1):28-42.
19. Gonzalez AE, Villalobos N, Montero E, Morales J, Alamo Sanz R, Muro A *et al.* Differential molecular identification of *Taeniid spp.* and *Sarcocystis spp.* cysts isolated from infected pigs and cattle. Veterinary Parasitology. 2006; 142:95-101.
 20. Sato MO, Cavalcante TV, Sako Y, Nakao M, Yamasaki H, Yatsuda AP *et al.* Evidence and potential for transmission of human and swine *Taenia solium* cysticercosis in the Piracuruca region, Piaui, Brazil. American Journal of Tropical Medicine and Hygiene. 2006; 75(5):933-935.
 21. Chiesa F, Dalmaso A, Bellio A, Martinetti M, Gili S, Civera T. Development of a Biomolecular Assay for Postmortem Diagnosis of *Taenia saginata* Cysticercosis. Food borne Pathogens and Disease. 2010; 7(10):1171-1175.
 22. Dalmaso A, Fontanella E, Piatti P, Civera T, Rosati S, Bottero MT. A multiplex PCR assay for the identification of animal species in feedstuffs. Molecular and Cellular Probes. 2004; 18:81-87.
 23. Lino Junior RS. Cysticercosis diagnostic methods in autopsies. Revista do Instituto de Medicina Tropical de Sao Paulo 2004; 46(3):138.