



E-ISSN: 2320-7078

P-ISSN: 2349-6800

JEZS 2017; 5(5): 887-893

© 2017 JEZS

Received: 27-07-2017

Accepted: 28-08-2017

**Imtithal Ali Mohammed**Department of Physiology and  
Pharmacology /College of  
Veterinary Medicine/ University  
of Baghdad**Baraa Najim Al-Okaily**Department of Physiology and  
Pharmacology /College of  
Veterinary Medicine/ University  
of Baghdad

## Effect of sodium fluoride on liver functions of rats and amelioration by CoQ10

**Imtithal Ali Mohammed and Baraa Najim Al-Okaily**

### Abstract

The present study was aimed to explore the protective role of Co enzyme Q (Co Q10) an antioxidant on hepatic dysfunction induced by sodium fluoride (SF) in adult male Wister rats. Twenty adult male rats were randomly assigned into four equal groups (five animals in each groups) and treated for 42 days daily as follows: first group was drenched drinking tap water, serving as control (group C), second group (group G<sub>1</sub>) received sodium nitrate 100ppm in drinking tap water to induce of liver toxicity along the experiment, third group (group G<sub>2</sub>) received sodium nitrate 100ppm in drinking tap water and was ameliorated with CoQ10 (10 mg /Kg. B.W) orally, while fourth group (group G<sub>3</sub>) were administered orally with CoQ10 at dose of 10 mg /Kg. B.W only. Fasting blood samples were collected at 0, 21, and 42 days of the experiment from orbital sinus to assess serum concentrations of total serum protein (TSP), albumin, globulin and total bilirubin (TB), as well as, aspartate aminotransferase (AST), alanine aminotransferase (ALT), and alkaline phosphatase (ALP) activities. At the end of the experiment sections from the liver were obtained for histopathological study. The results revealed that rats received sodium fluoride (G<sub>1</sub>) caused significant decrease in total serum protein and albumin concentrations, whereas significant increase in ALT, AST, ALP and total TB concentrations accompanied with histopathological changes in liver tissue sections as compared to control and other treated groups. On the other hand, the protective role of CoQ10 was clarified in groups G<sub>2</sub> including correction of above mentioned liver function testes and histopathological changes. In conclusion, the results of this study confirmed the protective role of CoQ10 as antioxidant against hepatotoxicity induced by sodium fluoride in adult rats.

**Keywords:** CoQ10, sodium fluoride, liver dysfunction, rats

### Introduction

Fluoride anions are present in water sources, ground water and drinking water as they are released from the run of fluoride- containing rocks and soils and filtered into water, thus the consumption of such water is typically instrumental to daily fluoride intake <sup>[1, 2]</sup>. Inorganic fluorine are used in aluminium production and as a flux in the steel, glass fiber industries and wood preservatives <sup>[3]</sup>, besides, it is commonly used in pesticides, fungicides and insecticides, various types of adhesives, glues and as a preservative <sup>[4]</sup>. Sodium fluoride compounds are used in the form of fluorinated water, tooth paste, mouth washes and fluoride tablets for prevention of dental caries <sup>[5, 6]</sup>, therefore, the exposure of populations to fluoride compounds has become significant <sup>[2]</sup>. ten Cte, (2013) <sup>[7]</sup> reported that fluoride reduces the decay of teeth enamel via reduce the rate of tooth enamel demineralization and an increase in the rate of remineralization of teeth.

Anjum *et al.*, <sup>[8]</sup> revealed that the fluoride caused impairment liver function, causing decrease in metabolic activities such as glycolysis, oxidative phosphorylation and lipid peroxidation, increased serum indices of liver function tests, inhibit certain antioxidant enzymes and molecules <sup>[9]</sup>. It also increase intracellular levels of the superoxide radical <sup>[10]</sup> disturbed of lipid profile <sup>[11]</sup>. Hens treated with sodium fluoride in ration showed mild or severe enlargement of their liver <sup>[12]</sup>. Some studies have shown that exposure to sodium fluoride caused a reduction in the protein content in the serum and liver <sup>[13, 14, 15]</sup>. Domestic animals consumption contaminated food and water with superphosphate fertilizer were suffering from signs of dental discoloration, difficulty in mastication and weakness <sup>[1, 16]</sup>.

Coenzyme Q10 is a fat soluble vitamin-like substance found in highest concentrations in heart, liver, kidney, pancreas and brain, while the lowest concentrations are found in the lungs and it is required for the proper functioning of many organs and chemical reactions in the body <sup>[17]</sup>. As well as CoQ10 is present in all cell membranes of endoplasmic reticulum, peroxisomes,

### Correspondence

**Baraa Najim Al-Okaily**Department of Physiology and  
Pharmacology /College of  
Veterinary Medicine/ University  
of Baghdad

lysosomes, and the inner membrane of mitochondria [18]. It is a component of the electron transport chain and participates in aerobic cellular respiration, generating high percentage of energy in the form of ATP. Furthermore, CoQ10 can be synthesized in the laboratory and is used both as a medicine and as a food supplement. Thus CoQ10 considered as the third most sold dietary supplement in the United States after omega-3 fatty acids and multivitamins [19]. CoQ10 has gained considerable attention as a dietary supplement capable of influencing cellular bioenergetics and counteracting some of the damage caused by free radicals [20, 21]. Some researches demonstrated the protective effects of CoQ10 in various models of oxidative and inflammatory tissue damage against the deleterious effects of inflammatory and reactive oxygen species (ROS) tissues damage via its antioxidant properties [22-26]. Considering the protective effects of Co Q 10 as antioxidant. The current experiment was aimed to investigate the role of CoQ10 to alleviating the sodium fluoride- induced alterations on liver functions in adult male rats.

### Materials and Methods

Adult male Swiss albino rats (190–250 g body weight) were housed in cages with good ventilation and illumination in the animal house of the College of Veterinary Medicine - University of Baghdad and had free access to water and standard rodent chow. They were left for two weeks for acclimatization with the experimental conditions.

Twenty rats were divided randomly into four equal groups (5 rats /group) and were handled daily as follows for 42 weeks :group C, rats in this group received dimethylsulfoxid (DMSO) 1% and served as control ; group G1, rats were administered sodium fluoride (SF) in tap water 100 ppm; group G2, rats in this group were intubated daily CoQ10 at dose of 10 mg/kg BW and administered sodium fluoride (SF) in tap water 100 ppm, Group g3, rats in this group were intubated CoQ10 at dose of 10 mg/kg BW only. Fasting blood samples were collected using gel-tube at 21 and 42 days of the experimental periods from anesthetized, (by i/m injection of Ketamine 90mg/kg B.W. and Xylazine 40mg/kg B.W.), using retro-orbital Sinus technique [27]. Then samples were centrifugation for 15 minutes at 3000 rpm. and sera were isolated and frozen at -18 °C until analysis. Then, the following parameters was estimated, using kits (product of Bio Systems, Agappy- Switzerland), including: total serum protein (TSP) was determined according to Henry *et al.*, (1974) [28], albumin as described by Doumas *et al.*, (1971) [29], globulin was calculating by subtracting serum albumin from total serum protein and total bilirubin(TB) according to Walters and Gerarde, (1970) [30] concentration, as well as, aspartate aminotransferase (AST) and alanine aminotransferase activity (ALT) activities was estimated as described by Ritman and Frankel,(1957) [31] and alkaline phosphatase activity (ALP) level was determined according to Henry,(1964) [32]. At the end of the experiment the animals were sacrificed and sections from the liver were obtained for histopathological study. Statistical analysis of data was done using SPSS software version 9.1. using Two-Way Analysis of Variance (ANOVA) followed by post hoc least significant difference (LSD) test. Results were expressed as mean  $\pm$  SE (standard error). For all analysis, the level of statistical significance was set at  $P < 0.05$  [33].

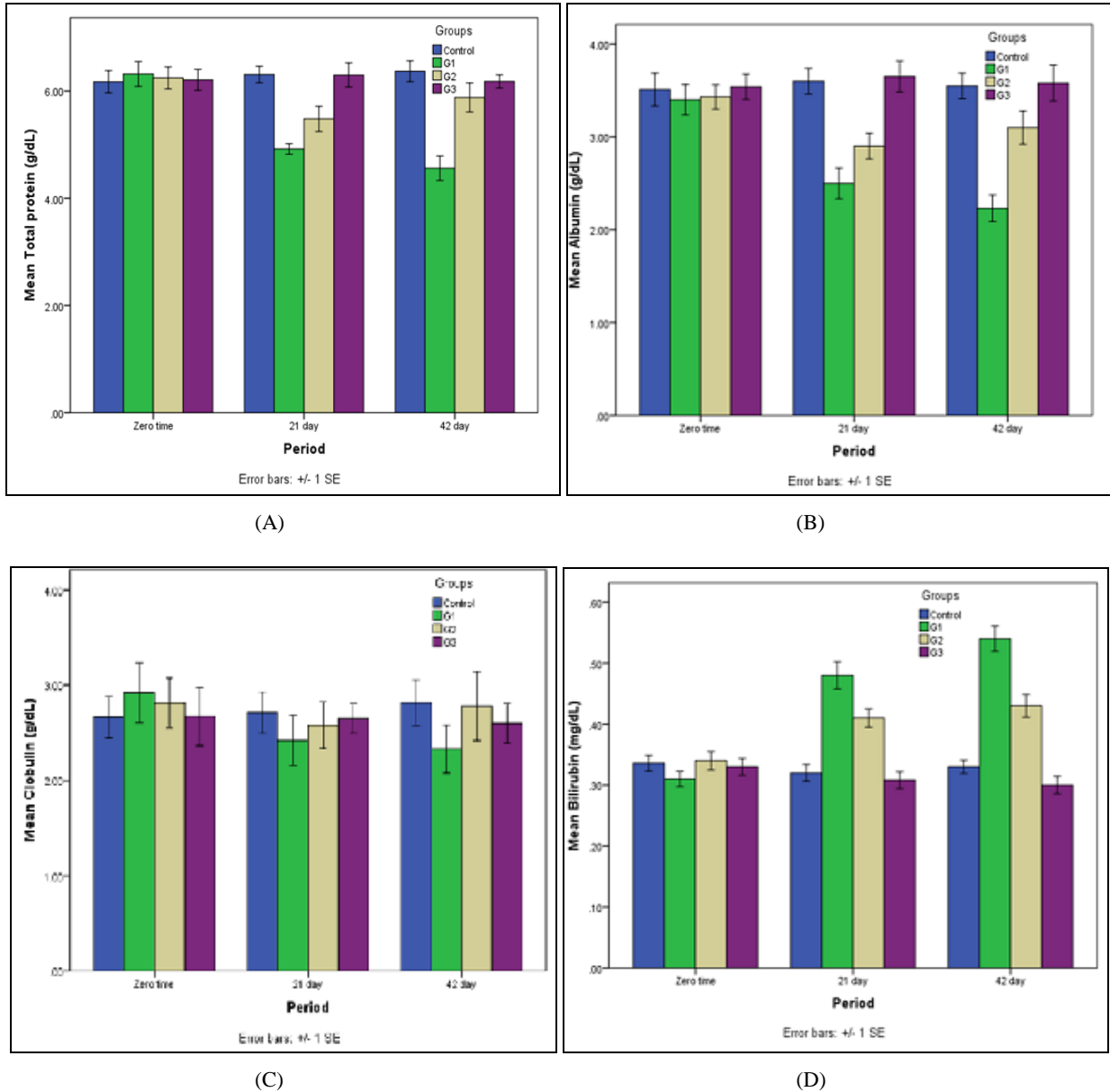
### Results

The results showed a significant ( $P < 0.05$ ) decrease in total serum protein concentration at 21 and 42 days of the experiment in groups G1 and G2 compared with control and G3 groups (figure-1) Meanwhile, combination of sodium fluoride and CoQ10 (group G2) caused significant ( $P < 0.05$ ) increase in TSP concentration at the end of the experiment comparing to group G1. Within the time, a significant ( $P < 0.05$ ) decrease in TSP were observed in G1 at 21, 42 days and in G2 at 21 days comparing to zero time. Statistical analysis of the mean values of serum albumin concentration illustrate a significant ( $P < 0.05$ ) decrease in this parameter in G1(SF) and G2 (SF plus CoQ10) treated groups at 21 and 42 days, comparing to control and G3 (figure-2). The other hand, exposure of rats to SF in combination with CoQ10 (G2 group) caused significant ( $P < 0.05$ ) increase in serum albumin concentration at 42 days comparing to SF treated group Within the time a significant ( $P < 0.05$ ) decrease in this parameters was observed in G1 group to the value in zero time. Figure-3 clarified that there was no significant ( $P > 0.05$ ) differences in globulin concentration between experimental groups at all periods of treatment.

After 21 days of administration of SF concurrently with CoQ10 there was a significant ( $P < 0.05$ ) increase in serum bilirubin concentration compared to control and G3 groups. The results showed a significant ( $P < 0.05$ ) elevation in this parameter in G1 and G2 groups and continued to day 42 of the experiment compared to control and G3 groups (figure-4). Furthermore, a significant ( $P < 0.05$ ) decrease was observed in G2 group at two experimental periods (21 and 42 day) compared to G1 group, whereas no significant ( $P > 0.05$ ) differences was recorded between G3 and control groups at the same periods.

Figures 5, 6 and 7 illustrated a significant ( $P < 0.05$ ) increase in serum activity of AST, ALT and ALP enzymes in groups G1 and G2 at two treated periods of the experiment as compared to control. Whereas, at the end of the experiment rats received SF in drinking water concurrently with CoQ10 (group G2) manifested a significant ( $P < 0.05$ ) decrease in values of these enzymes comparing to the values in G1 treated group. With exception of G3, the results recorded a significant differences ( $P < 0.05$ ) in values of these enzymes at two experimental periods as compared to pretreatment period (zero day).

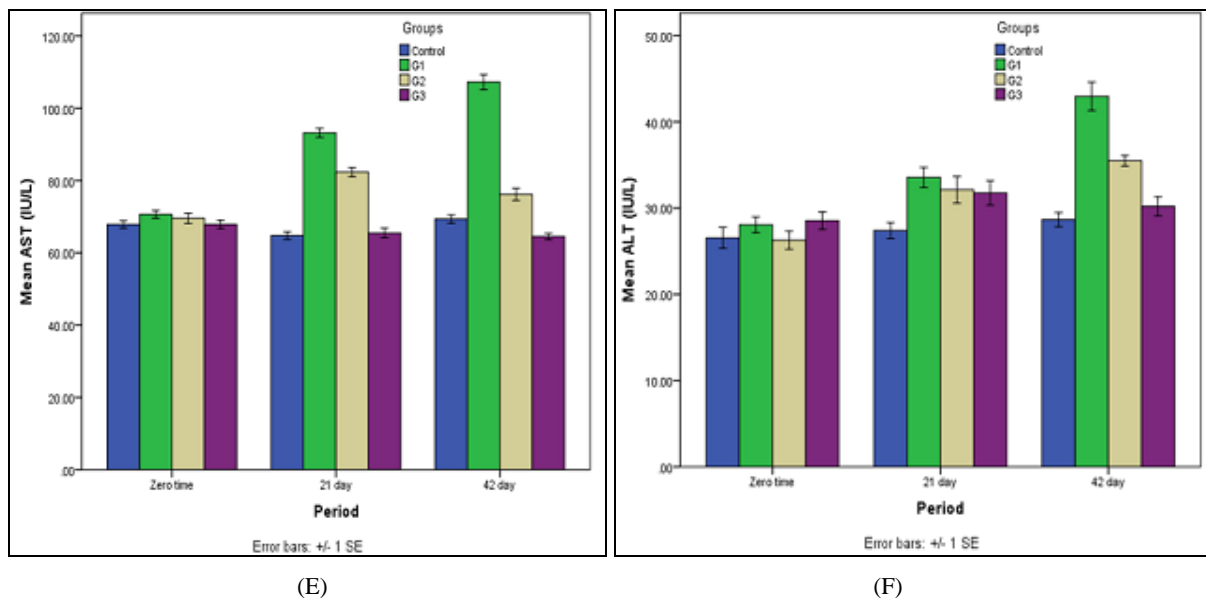
Microscopic examination of sections of liver of control group (figure- 3) and CoQ10 treated rats (group G3) (figure- 6) showed normal structure of hepatic tissue, the central vein was surrounded with polyhydral shape of hepatocytes and few nuclei of eosinophils. Meanwhile, rat liver sections of sodium fluoride treated group (G<sub>1</sub>) revealed noticeable uncommon changes including multifocal infiltration of mononuclear cells (MNCs) around the bile duct in the parenchyma associated with congestion of blood vessels, perivascular leukocytes, sever degenerative lesion in the with vaculation and/or necrosis of surrounding hepatocyte (figure-4) as compared to control (figure-3). Otherwise, liver sections of rats of group G2 manifested that CoQ10 attenuated the alterations induced by sodium fluoride and remodeling the histological aspects of liver (figure-5).

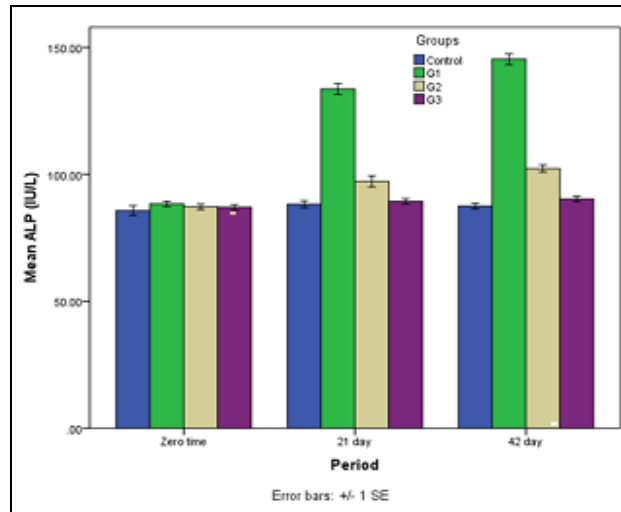


**Fig 1:** Effect of sodium fluoride and CoQ10 on serum (A) total serum protein (B) albumin (C) globulin (D) bilirubin concentration in adult male rats.

The values represents as mean  $\pm$ SE. n=5/group. Different small letters denotes the presence of significant differences ( $P<0.05$ ) between periods.

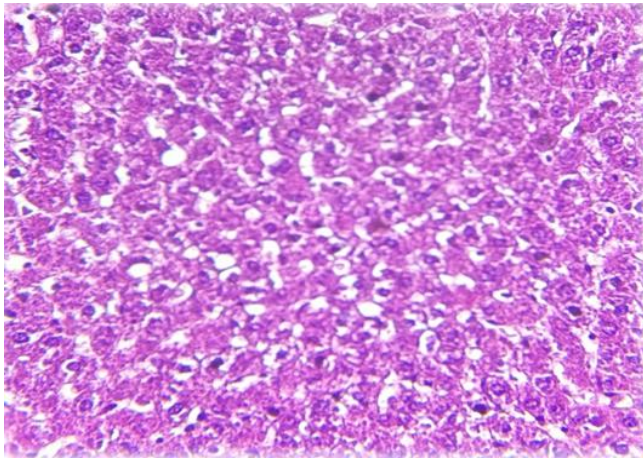
Different capital letters denotes the presence of significant differences ( $P<0.05$ ) between periods. Control: rats received tap water. G1: rats received tap water contain sodium fluoride 100 ppm. G2: rats received tap water contain sodium fluoride 100 ppm Plus orally garaged CoQ10 (10 mg/kg B.W). G3: rats orally garaged CoQ10 (10 mg /kg B.W).



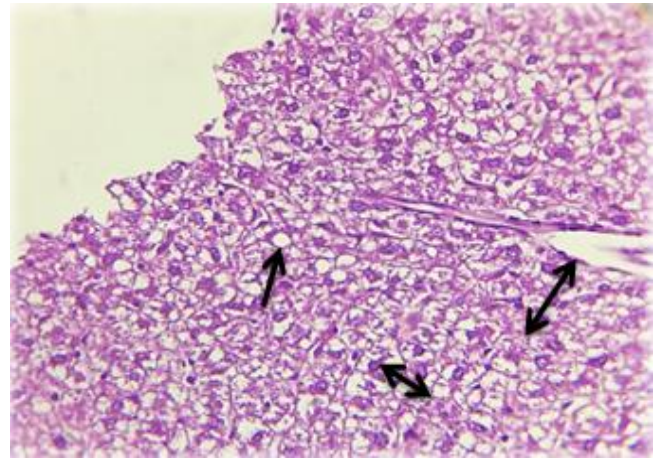


(G)

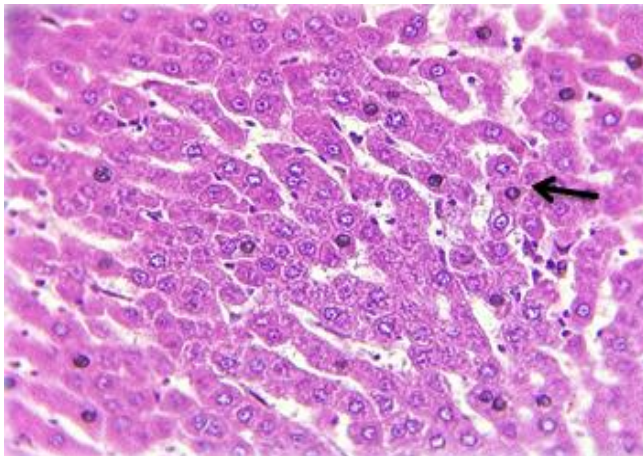
**Fig 2:** Effect of sodium fluoride and CoQ10 on serum (E) AST (F) ALT (G) ALP activity in adult male rats. The values represents as mean  $\pm$ SE. n=5/group. Different small letters denotes the presence of significant differences ( $P < 0.05$ ) between periods. Different capital letters denotes the presence of significant differences ( $P < 0.05$ ) between periods. Control: rats received tap water. G1: rats received tap water contain sodium fluoride 100 ppm. G2: rats received tap water contain sodium fluoride 100 ppm Plus orally garaged CoQ10 (10 mg/kg B.W). G3: rats orally garaged CoQ10 (10 mg /kg B.W).



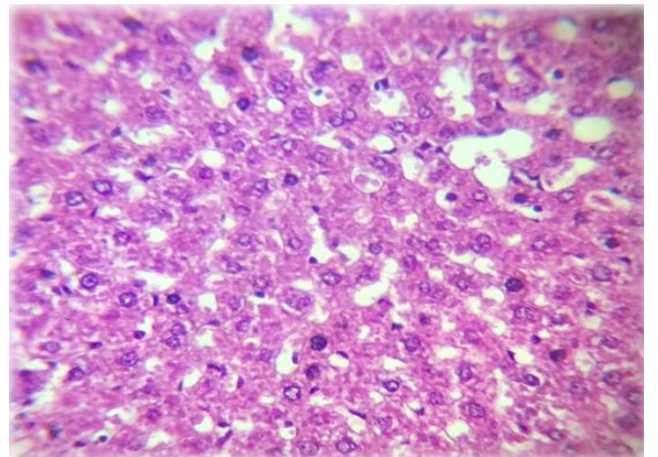
**Fig 3:** Cross section of rat liver of control group rats. Note: normal characteristic feature of the liver tissue (H & E stain 40X).



**Fig 5:** Cross section of rat liver of administration of Sodium fluoride and CoQ10 (group G2). Note: proliferation of kupffer cells accompanied with mild of fatty change  $\longleftrightarrow$  in certain area of hepatocyte few MNCs  $\longleftrightarrow$  proliferation in the dilated central vein (H & E stain 40X).



**Fig 4:** Cross section of rat liver received Sodium fluoride (group G1). Note: multifocal infiltration of mononuclear cells (MNCs) around the bile duct in the parenchyma associated with congestion of blood vessels (H & E stain 40X)



**Fig 6:** Cross section of rat liver received CoQ10(G3) rat. Note: normal characteristic feature of the liver (H & E stain 40X).

## Discussion

It is known that the liver plays a pivotal role in regulating a wide range of metabolic pathway [34, 35]. The results showed that rats received sodium fluoride in drinking water (group G1) caused a significant decrease in total serum protein (TSP) and albumin concentrations compared to control and G2 groups, indicating that SF could induced damage and/or oxidative stress in hepatic cells and the liver become unable to perform its functions [36, 37]. The results of the current study are in agreement with the results of other researchers [13, 15]. Bouasla *et al.*, [37] explained that sodium fluoride caused disturbance of protein synthesizing systems due to suppression of Na-K-ATPase activity with inhibited incorporation of amino acids into protein. As well, a reduction in total protein may be due to SF-induced either decrease protein synthesis or increased proteolysis, osmotic imbalance caused by lipid peroxidation [38] and caused depletion of both calcium and magnesium ions might be the reason for a decrease in synthesis of DNA, RNA and then protein synthesis [13, 39].

It is well known that ROS play an important role in the pathogenesis of various liver disorders included hepatic cirrhosis [40], liver inflammation [41, 42] and hepatic ischemia-reperfusion injury [43]. Accordingly, it could be suggested that SF induced oxidative stress mediated the development of hepatic inflammation and injury. Diesen and Kuo, [44] explained that activation of hepatic stellate cells (HSCs) by KCs caused release of ROS, leading to an increase proliferation and synthesis of extracellular matrix, which could be contributing to fibrosis and cirrhosis. Thus, oxidative stress associated with inflammation causes destruction of hepatocytes and architectural disarray [42]. While, the present study showed a significant increase in TSP and albumin concentrations in rats received SF concurrently with CoQ10 (group G2) compared to SF treated group. These results are agreement with Ali *et al.*, (2010) [22] it can be concluded that Co Q10 an antioxidant caused an improvement of hepatotoxicity-induced by sodium fluoride in adult rats.

In accordance with these results, Sumimoto *et al.* [45] found that treatment with CoQ<sub>10</sub> caused an elevation in levels of total protein to the normal range in ischemially damaged liver. Therefore, coenzyme Q10 have a prophylactic effects against liver damage induced by many toxicant agents attributed to its antioxidant activity [46, 47].

The results revealed that total serum bilirubin (TSB) concentration significantly increase in group G1 as compared to control and G2 groups indicating liver dysfunction accompanied with alteration in antioxidant enzymes and increase in MDA level [48-50], as well as, histological alterations of liver cells in G1 group observed in this study may lead to hyper bilirubinemia, however, the exact mechanisms(s) by SF caused an increase in serum bilirubin is remain to be elucidated. Meanwhile, a significant decrease in serum TB in G2 group (received SF plus CoQ10) as compared to group G1, might reflect the antioxidant properties of CoQ10. These results are in agreement with other researches using CoQ10 as hepatoprotective and anti-inflammatory [51-53]. Supplementation of enzyme CoQ10 could mitigated hepatic toxicity induced by SF as reflected by improvement of the measured liver function markers suggesting a potential protective effect of Co Q<sub>10</sub> against liver damage. Therefore, it could be concluded that CoQ10 has a hepatoprotective effects as antioxidant against SF via decreasing the production of ROS and attenuated the LPO leading to stabilize the integrity of the cellular membranes

and in turn decreasing the leakage of bilirubin from liver tissue [9, 54].

The current results of liver function tests in sodium fluoride intoxicated rats (group G1) showed an increase in the activities of ALT and AST and ALP enzymes. Such change in liver enzymes activity may be accompanied with a change in oxidant/antioxidant status. These results are supported by previous study [11, 15, 55]. Acute exposure to toxic dose of SF caused hepatocellular injury with an elevation of serum ALT and AST and ALP activities into the blood are important indicators as biomarkers of liver dysfunction in clinic findings [56]. Similar of these observations was reported in rats, pigs and broiler chickens [57-59]. Because of fluoride caused oxidative damage by increasing ROS, cytotoxicity, and LPO of the cell membrane [60] with significantly increased apoptosis/necrosis rate [61], consequently lead to leakage of the enzymes from the liver cells. Also release of cytochrome C from mitochondria and the activation pathway of cell death have been seen in SF exposure [62], which was accompanied with a decrease in the antioxidant status of liver [63] with alterations in liver functions. Besides, these results documented by histological changes observed in liver sections of group G1. Whereas, group G2 showed a significant decreased of serum AST, ALT and ALP activities as compared to G1. These findings suggest that coenzyme Q10 exert beneficial prophylactic effects on liver enzymes activity [22, 64, 65] against fluoride-induced hepatotoxicity [26]. For these reasons, it could be suggested that CoQ10 protects hepatocyte from the deleterious effect of SF and decreases leakage of liver enzymes into the circulation by enhancing antioxidant capacity. It can be concluded that Co Q10 an antioxidant caused an improvement of hepatotoxicity-induced by sodium fluoride in adult rats.

## References

1. National Research Council (NRC). Fluoride in drinking water: A Scientific Review of EPA's Standards. Washington, DC: National Academies Press, 2006.
2. ATSDR (Agency for Toxic Substances and Disease Registry). Medical management guidelines for hydrogen fluoride (HF). Atlanta, GA: U.S. Department of Health and Human Services, Public Health Service, 2014.
3. Mueller WH. Fluoride compounds, inorganic, sodium. Encyclopedia of chemical technology. John Wiley and Sons, Inc, 2001.
4. Budavari S. The Merck index: an encyclopedia of chemicals, drugs, and biological. 11<sup>th</sup>ed.. Merck Co., Rahway, N.J. 1989, 8565.
5. Dabrowska E, Letko R, Baluonowska M. Effect of sodium fluoride on the morphological picture of the rat liver exposed to NaF in drinking water. *Advances in Medical Sciences*. 2006; 51(1):91- 95.
6. Whitford GM. Acute toxicity of ingested fluoride. *Monographs in Oral Science*. 2011; 22:66-80.
7. ten Cate FM. Contemporary perspective on the use of fluoride products in caries prevention. *British Dental Journal*. 2013; 214:161-167.
8. Anjum KM, Mughal MS, Sayyed U, Yaqub A, Khalique A, Rashid MA *et al.* Influence of increasing fluoride dose rates on selected liver and kidney enzymes profile in domestic chicken (*Gallus domesticus*). *Journal of Animal Plant Science*. 2014; 24(1):77-80.
9. Abdel-Wahab WM. Protective effect of thymoquinone on sodium fluoride-induced hepatotoxicity and oxidative stress in rats. *The Journal of Basic and Applied Zoology*,

- 2013; 66:263-270.
10. Vani ML, Reddy KP. Effect of fluoride accumulation on some enzymes on brain and gastrocnemius muscle of mice. *Fluoride*. 2000; 33:17-26.
  11. Hassan HA, Yousef MI. Mitigating effects of antioxidant properties of black berry juice on sodium fluoride induced hepatotoxicity and oxidative stress in rats. *Food and Chemical Toxicology*. 2009; 47(9):2332-2337.
  12. Mohammed AS, Ali HY, Mehadi SK. The effect of sodium fluoride at different concentration on some organs (the liver, spleen and female reproductive system) of Newhampshire hens. Gross – pathological study. Technical Institute / kufa. 2012; 4(1).
  13. Jha A, SHAH K, VERMA R. Effects of sodium fluoride on DNA, RNA and protein contents in liver of mice and its amelioration by *Camellia Sinensis*. *Acta Poloniae Pharmaceutica-Drug Research*. 2012; 69(3):551-555.
  14. Mathur M. Sodium fluoride induced toxic effect on tumor protein 53 forming gene in swiss albino mice. *Cibtech Journal of Zoology*. 2013; 2(1):24-29.
  15. Ali EH, Al-Okaily BN. The protective role of Pomegranate seeds oil (Pometone) on serum protein in sodium fluoride treated rats. *IJVM*. 2016; 40(1):61-68.
  16. Patra RC, Dwived SK, Bhardwaj B, Swarup D. Industrial fluorosis in cattle and buffalo around Udaipur, India. *Science of the Total Environment*. 2000; 253(1-3):145-150.
  17. Kapoor P, Kapoor AK. Coenzyme Q10 – A novel molecule. *Journal Indian Academic of Clinical Medicine*. 2013; 14(1):37-45.
  18. Butler MG, Dasouki M, Bittel D, Hunter S, Naini A, DiMauro S. Coenzyme Q10 levels in Prader-Willi syndrome: comparison with obese and non-obese subjects. *American Journal of Medical Genetics Part A*. 2003; 119(2):168-171.
  19. Acton A. *Enzymes and Coenzymes – Advances in Research and Application*. Scholarly Edition, 2013.
  20. Linnane AW, Kopsidas G, Zhang C, Yarovaya N, Kovalenko S, Papakostopoulos P *et al.*, Cellular redox activity of coenzyme Q10: effect of CoQ10 supplementation on human skeletal muscle. *Free Radical Research*. 2002; 36(4):445-453.
  21. Schmelzer C, Lorenz G, Lindner I, Rimbach G, Niklowitz P, Menke T *et al.* Effects of Coenzyme Q10 on TNF-alpha secretion in chromium and cadmium ions. *Biofactors*. 2007; 31:35-41.
  22. Ali SA, Faddah L, Abedel-Baky A, Bayoumi A. Protective effect of L-carnitine and coenzyme Q10 on CCl4-induced liver injury in rats. *Scientia Pharmaceutica*. 2010; 78:881-896.
  23. Ekin S, Bayramogluo M. Cytoprotective effects of boric acid and coenzyme Q10 therapy on induced pulmonary fibrosis in response to intratracheal administration of bleomycin in rats. *Fresenius Environmental Bulletin*. 2013; 22(8):2428-2434.
  24. Mirmalek SA, Boushehrinejad AG, Yavari H, Kardeh B, Parsa Y, Salimi-Tabatabaee SA *et al.* Antioxidant and anti-inflammatory effects of Coenzyme Q10 on L-arginine-induced acute pancreatitis in rat. *Oxidative Medicine and Cellular Longevity*. 2016, 5818479.
  25. Thanh HN, Minh HPT, Duc LV, Thanh TB. Protective effect of Coenzyme Q10 on methamphetamine-induced neurotoxicity in the mouse brain. *Trends in Medical Research*. 2016; 11:1-10.
  26. Ulla A, Mohamed MK, Sikder b, Rahman AFMT, Sumi FA, Hossain *et al.*, Coenzyme Q10 prevents oxidative stress and fibrosis in isoprenaline induced cardiac remodeling in aged rats. *BMC Pharmacology and Toxicology*. 2017; 18:29.
  27. Para suraman S, Raveendran R, Kesavan R. Blood sample collection in small laboratory animals. *Journal of Pharmacology & Pharmacotherapeutics*. 2010; 1(12):87-93.
  28. Henry RJ, Cannon DC, Winkelman JW. *Clinical Chemistry: Principles and Technics*. Determination of Total Protein by a Direct Colorimetric Method, second edition. New York: Harper & Row, 1974.
  29. Doumas BT, Watson WA, Biggs HG. Albumin standards and the measurement of serum albumin with bromocresol green. *Clin Chim Acta*. 1971; 31:87-96.
  30. Walters M, Gerarde H. Ultramicromethod for the determination of conjugated and total bilirubin in serum or plasma. *Microchemical Journal*. 1970; 15:231-236.
  31. Reitman S, Frankel S. A colorimetric method for the determination of serum glutamic oxaloacetic and glutamic pyruvic transaminases. *American Journal of Clinical Pathology*. 1957; 28:53-56.
  32. Henry RJ. *Clinical Chemistry: Principles and Technics*. Determination of Alkaline Phosphatase by a Direct Colorimetric Method. New York: Harper and Row, 1964.
  33. Snedecor GW, Cochran W. *Statistical Methods*. 6th ed. The Iowa State University Press, 1973, 238-248.
  34. Karakus E, Karadeniz A, Simsek N, Can I, Kara A, Yildirim S *et al.* Protective effect of panax ginseng against serum biochemical change and apoptosis in liver of rats treated with carbon tetrachloride (CCl4). *Journal of Hazardous Materials*. 2011; 195:208-213.
  35. Robin S, Sunil K, Rana AC, Nidhi S. Different models of hepatotoxicity and related liver diseases. *IRJP*, 2012; 3(7):86-95.
  36. Shashi YM, Shivashankara AR. Brain lipid peroxidation and antioxidant systems of young rats in chronic fluoride intoxication. *Fluoride* 2002; 35(3):197.
  37. Bouasla A, Bouasl aI, Boumendjel A, Elfeki A, Messarah M. Hepatoprotective role of gallic acid on sodium fluoride –induced liver injury in rats. *International Journal of Pharmaceutical Sciences Review and Research*. 2014; 29(2):14-18.
  38. Yamaguti PY, Simões A, Ganzerla E, Souza DN, Nogueira FN, Nicolau J. Effects of single exposure of sodium fluoride on lipid peroxidation and antioxidant enzymes in salivary glands of rats. *Oxidative Medicine and Cell Longevity*. 2013; 674593.
  39. Sauerheber R. Physiological conditions affect toxicity of ingested industrial fluoride. *Journal of Environmental and Public Health*. Article ID 439490, 2013, 13.
  40. Sánchez-Valle V, Chávez-Tapia NC, Uribe M, Méndez-Sánchez N. Role of oxidative stress and molecular changes in liver fibrosis: a review. *Curr. Med. Chem*. 2012; 19:4850-4860.
  41. de Andrade KQ, Moura FA, dos Santos JM, de Araujo ORP, Santos JCD, Goulart MOF. Oxidative stress and inflammation in hepatic diseases: therapeutic possibilities of N-Acetylcysteine. *International Journal of Molecular Sciences*. *International Journal of Molecular Sciences*. 2015; 16(12):30269-30308.
  42. Chatterjee RN, Mitra A. An overview of effective therapies and recent advances in biomarkers for chronic liver diseases and associated liver cancer. *International Immunopharmacology*. 2015; 24:335-345.

43. Papadopoulos D, Siempis T, Theodorakou E, Tsoulfas G. Hepatic ischemia and reperfusion injury and trauma: Current Concepts. Archives of Trauma Research., 2013; 2(2):63-70.
44. Diesen DL, Kuo PC. Nitric oxide and redox regulation in the liver: Part II. Redox biology in pathologic hepatocytes and implications for intervention. Journal of Surgical Research. 2011; 167:96-112.
45. Sumimoto K, Inagaki K, Ito H, Marubayashi S, Yamada K, Kawasaki T *et al*. Ischemic damage prevention by coenzyme Q10 treatment of the donor before orthotopic liver transplantation: Biochemical and histological findings. Surgery. 1987; 102:821-827.
46. Wang FR, Ai H, Chen XM, Lei CL. Hepatoprotective effect of a protein-enriched fraction from the Maggots (*Musca Domestica*) against CCl<sub>4</sub>-induced hepatic damage in rats. Biotechnology Letters. 2007; 29:853-858.
47. Navar VJ, Senior JR. Drug-related hepatotoxicity. The New England Journal of Medicine. 2006; 354:731-739.
48. Al-Harbi MS, Hamza RZ, Daway AA. Ameliorative effect and curcumin on sodium fluoride induced hepatotoxicity and oxidative stress in male mice. Journal of Chemical and Pharmaceutical Research. 2014; 6(4):984-998.
49. Bulle F, Mavier P, Zafrani ES, Preaux AM, Siegrist MCL. Mechanism of gamma-glutamyl transpeptidase release in serum during intrahepatic and extrahepatic cholestasis in the rat: a histochemical, biochemical and molecular approach. Hepatology. 1990; 11:545-550.
50. Sharma A, Chinoy NJ. Role of free radical in fluoride-induced toxicity in liver and kidney of mice and its reversal. Fluoride. 1998; 31:S26.
51. Fouad AA, Jresat I. Hepatoprotective effect of coenzyme Q10 in rats with acetaminophen toxicity. Environmental Toxicology and Pharmacology. 2012; 33(2):158-67.
52. Vasiliev AV, Martinova EA, Sharanova NV, Gapparov MM. Effects of coenzyme Q10 on rat liver cells under conditions of metabolic stress. Bulletin of Experimental Biology and Medicine. 2011; 150(4):416-419.
53. Lee B, Tseng Y, Yen C, Ping-Ting Lin P. Effects of coenzyme Q10 supplementation (300 mg/day) on antioxidation and anti-inflammation in coronary artery disease patients during statins therapy: a randomized, placebo-controlled trial. Nutrition Journal. 2013; 12:142.
54. Esfahani SA, Esmaeilzadeh E, Bagheri F, Emami Y, Farjam M. The effect of co-enzyme Q10 on acute liver damage in rats, a biochemical and pathological study. Hepatitis Monthly. 2013; 13(8):e13685
55. Nabavi SM, Nabavi SF, Eslami S, Moghaddam AH. *In vivo* protective effects of quercetin against sodium fluoride-induced oxidative stress in the hepatic tissue. Food Chemistry. 2012; 132:931-935.
56. Giannini EG, Testa R, Vincenzo Savarino V. Liver enzyme alteration: a guide for clinicians Canadian Medical Association Journal. 2005; 172(3):367-379.
57. Shanthakumari D, Srinivasalu S, Subramanian S. Effect of fluoride intoxication on lipid peroxidation and antioxidant status in experimental rats. Toxicology. 2004; 204:219-228.
58. Tao X, Xu ZR, Wang YZ. Effects of dietary fluoride levels on growth, serum indexes and antioxidant systems in growing pigs. The Turkish Journal of Veterinary and Animal Sciences. 2006; 30:65-70.
59. Deng YB, Cui HM, Peng X, Fang J, Zuo ZC, Deng JL *et al.*, Effects of high dietary fluoride on serum biochemistry and oxidative stress parameters in broiler chickens. Health. 2014; 6:1840-1848.
60. Nehru B, Anand P. Oxidative damage following chronic aluminum exposure in adult and pup rat brains. Journal of Trace Elements in Medicine and Biology., 2005; 19:203-208.
61. Yilmaza BO, Erkana M. Effect of vitamin C on sodium fluoride -induced oxidative damage in Sertoli cells. Fluoride. 2015; 48(3):241-251.
62. Barbier O, Mendoza LA, DelRazo LM. Molecular mechanisms of fluoride toxicity. Chemico-Biological Interactions. 2010; 188:319-333.
63. Atmaca N, Atmaca HT, Kanici A, Antepioglu T. Protective effect of reveratol on sodium fluoride-induced oxidative stress, hepatotoxicity and neurotoxicity in rats. Food and Chemical Toxicology. 2014; 70:191-197.
64. Ahmadvand H, Ghasemi-Dehnoo M. Antiatherogenic, hepatoprotective, and hypolipidemic effects of coenzyme Q10 in alloxan-induced type 1 diabetic rats. ARYA Atheroscler. 2014; 10(4):192-198.
65. Ashkani-Esfahani S, Bagheri F, Emami Y, Esmaeilzadeh E, Azarpira N, Hassanabadi N *et al*. Protective effects of co-enzyme Q10 on thioacetamide-induced acute liver damage and its correlation with behavioral, biochemical, and pathological factors. Iranian Red Crescent Medical Journal. 2016; 18(8):e29166.