Journal of Entomology and Zoology Studies

Available online at www.entomoljournal.com

E-ISSN: 2320-7078
P-ISSN: 2349-6800
JEZS 2017; 5(5): 1698-1700

Received: 04-07-2017
Accepted: 05-08-2017

S Yogeshpriya
Department of Veterinary Medicine, Veterinary College and Research Institute, Orathanadu, Thanjavur, Tamil Nadu, India

M Sivakumar
Department of Veterinary Medicine, Veterinary College and Research Institute, Orathanadu, Thanjavur, Tamil Nadu, India

P Selvaraj
Department of Veterinary Medicine, Veterinary College and Research Institute, Orathanadu, Thanjavur, Tamil Nadu, India

M Veeraselvam
Department of Veterinary Medicine, Veterinary College and Research Institute, Orathanadu, Thanjavur, Tamil Nadu, India

M Saravanan
Teaching Veterinary Clinical Complex, Veterinary College and Research Institute, Orathanadu, Thanjavur, Tamil Nadu, India.

M Venkatesan
Department of Veterinary Medicine, Veterinary College and Research Institute, Orathanadu, Thanjavur, Tamil Nadu, India

T Arulkumar
Tamil Nadu Veterinary and Animal Sciences University, Tamil Nadu, India

Correspondence
S Yogeshpriya
Department of Veterinary Medicine, Veterinary College and Research Institute, Orathanadu, Thanjavur, Tamil Nadu, India

Efficacy of amitraz plus Miconazole for the treatment of juvenile generalized demodicosis associated with dermatophytosis in a Pug

S Yogeshpriya, M Sivakumar, P Selvaraj, M Veeraselvam, M Saravanan, M Venkatesan and T Arulkumar

Abstract
A six month old female Pug was presented to Teaching Veterinary Clinical Complex (TVCC), Veterinary College and Research Institute, Orathanadu, Thanjavur for dermatological examination in June 2017 with a history of itching, alopecia, crust formation, hemorrhage, pus and thickening of the skin on all over the body for past one month. Clinical examination of the dog revealed blackening of skin and musty odor. On laboratory examination of skin scraping and acetate tape impression this case was diagnosed as a concurrent infection of juvenile generalized demodicosis and dermatophytosis. The dog was treated with Ivermectin, amitraz, and antifungal, along with supportive therapy. The dog showed uneventful recovery after one and half month's treatment.

Keywords: Demodicosis, dermatophytosis, concurrent infection, amitraz

Introduction
Canine Demodicosis also known as demodectic mange, red mange or follicular mange usually found in young dogs, especially the short haired breeds is one of the well-known skin diseases encountered in veterinary practice [1]. The disease is caused by *Demodex canis*, it is a normal inhabitant of the dogs [2] and is acquired from the dam during nursing [3]. Natural infestation has apparently been acquired neonatally through contact with the nursing
bitch when the adult and motile mites invade the hair follicles of dog [4]**.** The infection can only be seen in the immunodeficient animals, old dogs and young puppies of about 3 months to a year. Immunosuppression or any defect in the skin immune system favors proliferation of mites in hair follicles and results in clinical demodicosis [5]. Alterations in the cutaneous microenvironment and/or in host defense mechanisms in canine skin may have influenced the mite development, dermatophytes and bacterial overgrowth thus leading to the appearance of skin lesions.
Dermatophytes are common causes of cutaneous fungal infection in dog and cats. The most common causative fungi of dermatophytosis in animals are caused either by *Microsporum canis*, *Microsporum gypseum*, and *Trichophyton mentagrophytes*. Juvenile-onset localized demodectic mange resolves without treatment in 90% of cases, whereas in some patients the administration of topical or oral antibiotics is needed in order to control the secondary bacterial skin infections [6]. Conversely, generalized demodectic mange is a serious condition requiring a prolonged pharmacological treatment, which is often considered difficult and potentially life-threatening [7]. Present paper describes the successful management of Concurrent Infection of Juvenile Generalized Demodicosis associated with Dermatophytosis in a Pug.

Materials and Methods
On April 2017, a 6 month old female Pug puppy weighing 7 kg was presented to Teaching Veterinary Clinical Complex (TVCC), Veterinary College and Research Institute, Orathanadu, Thanjavur with a history of itching, alopecia, crust formation for the one month. On presentation, puppy was active, alert, conjunctival mucus membrane pink and moist, temperature 39.3 ˚C with heart rate 146/ min and respiratory rate 35/min was observed. Dermatological examination revealed patchy alopecia with erythema, erythematous papules, serohemorrhagic crusts and moderate amounts of white scale on the ventral chest/ sternum, and on the neck and proximal forelimbs (Figs 1) deeply erythematous papules coalescing into

plaques on the ventral abdomen and diffuse pustules on the ventral abdomen and proximal limbs. Deep skin scrapings from the skin of affected areas taken with proper sample collection technique and examined under microscopically. The acetate adhesive tape was also applied to area of skin lesions whish was stained with lactophenol cotton blue stain and examined microscopically. Blood samples were collected for complete haematological studies and biochemical studies.

Results and Discussion

Microscopic examination of deep skin scraping revealed the presence of a cigar shaped *Demodex canis* and on acetate tape impression stained with lactophenol cotton blue showed the presence of spindle or boat shaped macroconidium of *Microsporum canis*, respectively (Fig.2&3). Finding more than one mite is strongly suggestive of clinical Demodicosis [6]. Based on the initial dermatological evaluation and diagnostic tests, the dog was diagnosed with generalized demodicosis and dermatophytosis. It is assumed that immunosuppression or a defect in the skin immune system allows for mites to proliferate in hair follicles, resulting in clinical signs [8]. The dogs with environmental exposure, such as hunting dogs or immunosuppressed dogs, can develop opportunistic infections also due to the zoonotic potential, an accurate and rapid diagnosis of dermatophytosis is imperative in suspected cases [8, 9]. There is no gold standard for the diagnosis of dermatophytosis, although multiple diagnostic tests are available for confirmation and identification of dermatophytic disease, including trichogram, cytology, Wood's lamp examination, culture and histopathology [10]. Combination therapy, with both oral and topical antifungal treatments, is often used for more widespread infections; treatment of focal lesionscan be accomplished with direct topical therapy alone [10, 11].

The puppy was initially treated with Ivermectin @ 0.2 mg/ kg body weight orally at alternative days. The owner was advised to bath the dog with benzoyl peroxide shampoo (Petben^{R}) twice weekly removal of crusts and debris, followed by topical application of 0.05% Amitraz solution [12]. Micodin shampoo was used two times in a week to counteract the fungal infection and also given tablet cephalexin @ 25mg/kg also given daily for 10 days twice daily for to treat concurrent bacterial infection. Multivitamin and immune stimulator were also given along with adequate nutrition during the treatment period. Treatment was continued until complete recovery of the animal (Fig.4). Two consecutive negative skins scrapping which was in agreement to findings of the previous studies [5, 6].

Fig 1: Dog affected with generalized demodicosis

Fig 2: *Demodex canis* under 40x

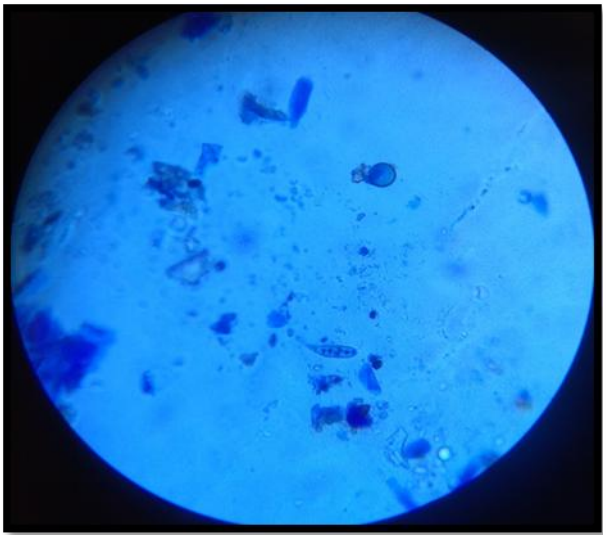

Fig 3: *M. canis* macroconidium under 40x

Fig 4: After recovery

Table 1: Haematological parameters of the dog with Juvenile Generalized Demodicosis associated with Dermatophytosis

Hematology		
Parameters	Before treatment	After treatment
Hemoglobin (g/dl)	**8.4**	12.42
PCV (%)	30	41
RBC ($10^{6/}$µl)	4.85	4.71
WBC ($10^{3/}$µl)	15.6	16.57
Neutrophils (%)	67	60
Lymphocytes (%)	30	34
Monocytes (%)	2	3
Eosinophils (%)	1	3
Basophils (%)	0	0

Table 2: Biochemical parameters of Juvenile Generalized Demodicosis associated with Dermatophytosis in a Pug

Biochemical analysis		
Parameters	Before treatment	After treatment
BUN (mg/dl)	32	28
Creatinine (mg/dl)	0.62	0.68
Glucose (mg/dl)	72	75
Total protein (g/dl)	6.41	6.02
Albumin (g/dl)	2.68	2.85
Globulin (g/dl)	3.73	3.17

Conclusion

The dog was negative for both demodex mange and M. *canis* at 45 days post treatment, coinciding with improved general clinical conditions, recovering skin lesions and no further signs of pruritus. These results show that Miconazole plus amitraz associated with the antibiotic therapy is highly effective for treating generalized demodectic mange and could also be effective towards controlling M. *canis* opportunistic infections. The presence of *Microsporum canis* infection in the dog having a greater risk of transmitting to veterinarian, veterinary health worker and their pet owners. So, proper handling measures need to prevent the acquiring of disease for dogs.

In conclusion, it is extremely important to critically evaluate dermatological disease during each examination with the proper baseline diagnostic testing. It is also essential to understand the risks, benefits and possible side effects of all therapies administered when creating a long-term treatment plan.

Acknowledgement

The authors acknowledge The Dean, Veterinary College and Research Institute, Orathanadu, Tamilnadu, India to carry out the study successfully.

References

1. Sivajothi S, Reddy BS, Rayulu VC. Demodicosis caused by Demodex canis and Demodex cornei in dogs. Journal of parasitic diseases. 2015; 39(4):673-676.
2. Ravera I, Altet L, Francino O, Sanchez A, Roldan W, Villanueva S *et al*. Small Demodex populations colonize most parts of the skin of healthy dogs. Vet. dermatol. 2013; 24:168-173.
3. Greve JH, Gaafar SM. Natural transmission of Demodex canis in dogs. J. Am. Vet. Med. Assoc. 1966; 148:1043-1045.
4. Horne KL. Canine demodicosis. Veterinary Technician, March. 2010; E1-E6.
5. Mueller RS, Bensignor E, Ferrer L, Holm B, Lemarie S, Paradis M *et al*. Treatment of demodicosis in dogs: 2011 clinical practice guidelines. Veterinary Dermatology. 2012; 23(2):86.
6. Singh SK, Kumar M, Jadhav RK, Saxena SK. An update on therapeutic management of canine demodicosis. Veterinary World. 2011; 4(1):41-44.
7. Scott DW, Miller WH, Griffin CE. Dermatologic therapy. In: Mueller and Kirk's small animal dermatology. 6th ed. Philadelphia, Pa: WBanimal dermatology. 6th ed. Philadelphia, Pa: WB Saunders. 2001, 207-273.
8. Stephen JE, Edward CF. Textbook of Veterinary Internal Medicine: Diseases of the Dog and Cat, Canine Demodicosis Catherine A. Outerbridge St.7th Edition. Louis, Mo.: Elsevier Saunders. 1999; 2:138
9. Greene C. Infectious diseases of dog and cat. 4th Edition. Saunders. 2011, 119-132.
10. Miller WH, Griffin CE, Campbell KL. Muller & Kirk's Small Animal Dermatology, seventh ed. Elsevier, St. Louis, MO. 2013, 81-84,91-92
11. Moriello KA. Treatment of dermatophytosis in dogs and cats: review of published studies. Veterinary Dermatology. 2004; 15:99-107.
12. Gortel K. Update on canine demodicosis. Veterinary Clinics: Small Animal Practice. 2006; 36(1):229-241.