Journal of Entomology and Zoology Studies

Available online at www.entomoljournal.com

E-ISSN: 2320-7078
P-ISSN: 2349-6800
JEZS 2017; 5(6): 2200-2205

Received: 15-09-2017
Accepted: 23-10-2017

Mohammed S Dawood
Department of Anatomy and Histology /College of Veterinary Medicine, University of Baghdad, Baghdad- Iraq

Mustafa J Khamas
Department of Anatomy and Histology /College of Veterinary Medicine, University of Baghdad, Baghdad- Iraq

Correspondence
Mohammed S Dawood
Department of Anatomy and Histology /College of Veterinary Medicine, University of Baghdad, Baghdad- Iraq

Anatomical features of the liver, gallbladder and biliary duct system of Indigenous Gazelle (*Gazella subgutturosa*)

Mohammed S Dawood and Mustafa J Khamas

Abstract
The study was carried out to investigate the anatomical structure of the liver and gall bladder in Indigenous gazelle in a college of veterinary medicine at university of Baghdad during October 2016 – March 2017. Six adult gazelles were used. The result indicated that the liver was dark brown color, rectangular shape and on the right side of the thoracic part of the abdomen. It measured 19cm, 11cm, 2.5cm in length, width, depth respectively, and weight 275.40±0.21g. It was divided into left, right, caudate and quadrate lobes in addition to caudate and papillary processes. It was supplied by the hepatic artery, which branched into right, left and middle branches. The gallbladder was narrow, elongated pear shaped attached to the cystic fossa of the liver. The biliary system consisted of right and left hepatic ducts, common hepatic duct, cystic duct and common bile duct. The present study concluded that in Gazella liver is similar to that of small ruminants and different in blood supply.

Keywords: Liver, biliary duct system, gall bladder, gazella

1. Introduction
The liver is the largest body gland and is both endocrine and exocrine function which involves production, collection and concentration of bile in the gall bladder prior to being drained into the duodenum [1]. The liver relative weight in carnivores is 3%-4% [2], 2% in omnivores [3], 1%-1.5% in herbivores [4]. A macroscopic structure of liver location is in the visceral face of the diaphragm and the body right midline [5] in deer, [6] in goat, [7] in camels,[8] in Jebeer gazelle. It consisted of two faces and four edges; visceral parietal faces, dorsal, ventral, right and left edges. The parietal is convex and the visceral is concave. In general, liver have four main lobes, right, left, quadrate and caudate lobe, with a several supporting ligaments [9]. The gallbladder is a small pear-shaped sacs that clutch greenish yellow sticky bile [10]. The left and right hepatic ducts facilitate bile flows outside the liver, these two ducts come together to figure the common hepatic duct, which is joined with the gallbladder through the cystic duct, then the extension of the hepatic bile duct is the common bile duct which enters the small intestine [11,12]. *Gazella subgutturosa* is one wild species which separated in a part of Iraq, Iran, southwestern Pakistan, southeastern Turkey, northern Azerbaijan, eastern Georgia, Afghanistan, and Uzbekistan [13, 14]. In Iraq, the gazelle is distributed in the southern and part of southern regions Gazella and has domesticated in many nature reserves in many governorates and close Baghdad. The study was aimed to investigate the anatomical structure and the blood supply of the liver and gall bladder in Indigenous gazelle.

2. Materials and Methods
Six healthy adult males weighted 16.60±0.51kg were used. The animals were obtained from (AL-Madaen Animal Reservoir) in Baghdad-Iraq. A study was conducted in laboratory of Department of anatomy and histology at College of Veterinary Medicine-University of Baghdad, during a period extended from October 2016 – March 2017. The animals were scarified by slaughter, then abdominal wall was opened to view the abdominal viscera, the liver was pointed out and the organs location and relationship with other adjacent organs was photographed in situ. The topography and shape of the organs was studied and documented by a digital vernia, electron balance and digital camera. Entire livers with part of the duodenum and diaphragm were collected immediately from the animals, checked from any disease or illness that may appear. Macroscopic measurements of the liver and gallbladder such as relative weight, length, depth diameter were measured. For studying of blood supply, the

animal was injected with red paint slick-milky latex by a 23G needle and syringe through the carotid artery [15], after that the specimens were dissected carefully for the blood vessels supplying of the liver and gallbladder. Two dimensions length and diameter of gall bladder and extra hepatic ducts (left and right hepatic ducts, common hepatic duct and common bile ducts) using vernier and a ruler. Three dimensions cast for gall bladder, intra and extra hepatic ducts was occurring. The resin cannulated through the common hepatic duct from the duodenal opening. The injection was done by manual push using syringe of 20 ml. The maceration was applied by using 40% KOH [16] for 7 days. The radiography was done by using a contrast media as a biligrafin, injected through the common bile duct.

2.1 Statistical analysis

Statistical analysis has been achieved with SPSS version (16) to analyze the estimated results; the results were expressed by Means and Standard Error (M±SE).

3. Results and Discussion

The present study revealed that the liver was positioned in the thoracic part of the abdomen, immediately in the wake of the diaphragm. Its was observed on the right side and the most cranial part of the abdominal cavity from 8th thoracic vertebra to the level of 1st lumbar vertebra (Fig.1). These results were agreeing with the results of [8] in Jebeer Gazelle, [17, 18] in pig, [19] in carnivores, while in camel [20] who referred an opposite observation "the extension of the liver started from the 5th rib to the 11thrib. On the other hand [5] also revealed dissimilarity with the present result in deer and stated that the extension of liver was from 7th to the last rib, [9, 21] in equine, except in dog [2] who referred to the central position of the liver. The mean weight of the liver was 275.40±0.21, relative weight was 1.7%, and had dark brown color and a rectangular shape. The liver was measured 19cm, 11cm and 2.5cm in length, width and depth respectively, dissimilar results was mentioned by [22,23,7] in camel who mentioned that the liver had irregular prismatic shape except the color mentioned and the other unrelated values were believed from [5] in deer, [24] in human, [25] in chinchillas and [26] in dog who explained it as heart valentine shape, whereas [27, 28] remember defferent data about the relative weight in equine. The liver had two fissured surfaces, concave and convex, the convex towards the diaphragm, and concave was toward the abdomen. The meeting of the two surfaces was giving the sharp-edged border ventro-lateral and blunt border dorsally (Fig.2&3). The hepatic portal area was marked on the visceral surface throughout which the bile duct, portal vein and hepatic vessels enter or leave the liver, these results were agreed with [7] in camel [17] in pig,[19] in carnivores, [27, 28] in equine. The liver was divided into four main lobes; left, right, caudate and quadrate lobes in addition to caudate process and papillary process. The visceral surface has impressed down by the stomach, pancreas, duodenum, and the right kidney, whereas the dorsal edge of the left part has carried the esophageal notch (Fig.3), similar observations were reported by [7] in camel, except the quadrate and left lobe, which are divided onto medial and lateral, [19] in carnivores excluding the liver lobulation which was divided into six lobes, [21, 9, 27, 28] in equine, meanwhile [29, 22] noticed the special information about the number of the liver lobe. There were many ligaments that rigid the liver into adjacent organs; round, falciform, hepatoduodenal and hepatogastric ligaments (Fig.4). The other ligaments of the liver were left triangular ligament, right triangular ligament and coronary ligaments (Fig.5).The triangular ligament extended between the dorsal part of the liver on each side and the diaphragm, whereas the coronary surrounded the caudal vena cava during its short passage from the liver to the diaphragm, such results were seen by [7] in camels, while [22] in camels [2] in canine [30] in ruminants mentioned that the hepatorenal and lesser omentum instead of the hepatoduodenal and hepatogastric. The present result showed that the liver receives blood supply via the hepatic artery and the portal vein. The hepatic artery was a subdivision of the celiac artery which was branched from the coelico mesenteric trunk that divided from the abdominal aorta. Hepatic artery enters the liver together with the portal vein at the hepatic porta on the visceral surface of the organ (Fig.6). Then the hepatic artery subdivided into dorsal and ventral left, right and middle lobular artery that supplies the lobes (Fig.7). The cystic artery was a branching of the right hepatic artery passing down to reach the gall bladder (Fig.8), these results were in contrast with [31, 32, 7] in camels who said that the hepatic artery grow as one of the three primary branches of the celiac artery. The opposite results of the hepatic artery have been shown that the celiac artery divided into right dorsal, right ventral and left, while [12] defined the division of the hepatic artery in the pig as right and left only, while authors like, [30] in ruminants,[33] in sheep, [34] in small ruminants,[35] in guinea pig, [36] in dog [37, 12] in pig are agree with us. The present result revealed that the gallbladder was narrow, elongated blind pear shape with dark green color attached to the cystic fossa on the visceral face of the liver flanked by the right and quadrate lobes (Fig.3&8). The fossa was long shallow, measured 3 cm in length and 2 cm in width, its length was about 3cm, the diameter of the neck, fundus and the body were (10 mm, 16 mm,20 mm),respectively. The fundus was a wide round blind pole downward away from the ventral hepatic border, while the body occupied the middle portion and form the most of the gallbladder and continuous with the funnel shape neck, directed upward and slender to become cystic duct, the cystic duct have length and diameter (2cm- 2mm) respectively, the gall bladder neck sustained by the cystic duct to join the right hepatic duct. The left and right hepatic ducts were joining together to form the common hepatic duct, which come into the duodenum (Fig. 9), these results were agreeing with [10]. Authors like [11] who noticed same as information about common bile duct creation in ruminants, carnivores and human, but [37] stated categories as in porcine. In addition to that [26] explained the pear shape gallbladder with rounded fundus and narrow body and neck in carnivores, this like the present study. On the other hand [38, 36] have a details the origination of the dog gallbladder that created from 3-4 major collecting ducts and two separated cystic ducts. Opposite as we see Nowak [25] in chinchillas described the thin wall elongated gallbladder was located on the visceral surface at the gallbladder fossa of the liver. Its mean length and diameter were (12.4mm, 5.4mm). AL-Mayahi [34] and Al-Rekabi [39] investigations in small ruminants and buffalo the data were obtained of the gallbladder and cystic duct revealed a deference's in all measurements with the present result, except the shape of the gallbladder and the creation of the duct system. While there are many researchers denoted that these animals missing gall bladder like [29, 22, 31, 32, 7] in camels and [5] in deer, [21, 9] in equine. The result of the radiographics and casts were illustrated the intra hepatic biliary tree visibly to the 5thstage of intra hepatic ducts which were consisted of left and right hepatic duct, primary, secondary, tertiary, inter and intra lobar duct (Fig.10). The

primary lobar duct subdivided into secondary and tertiary ducts, then ramified in the left and quadrate hepatic lobes. The short right hepatic duct branched into four primary dorsal and ventral ducts, the 1st one branched into the right and caudate lobe, the second, third and fourth ramified into caudate lobe and caudate process. Both right and left hepatic ducts receive tributaries on its dorsal surface of the caudate lobe some tributaries on its ventral surface coming from quadrate lobe (Fig.10, 11 & 12). The gall bladder connects the ventral primary lobar duct of the right hepatic duct via small narrow cystic duct. The present result was accords with the result of [34, 39], while dissimilarities were too noticed by [40] in human.

4. Conclusion

The study concluded that the liver of gazelle was similar to that of small ruminants in its position as well as the ligamentaion, color, shape of the surface, while the shape was different in addition the blood supply which consisted of right, dorsal and ventral left as well as middle with the small ruminants. The resin cast and radiography unlike with that of small ruminants that associated with separation of the biliary duct system. The prospective of the present study suggests investigation of the histochemical structure of the liver and gall bladder in the same species.

5. Acknowledgement

The authors acknowledges all technical staff and assistances in department Of Anatomy, Histology &Embryology-College of veterinary Medicine at University Of Baghdad.

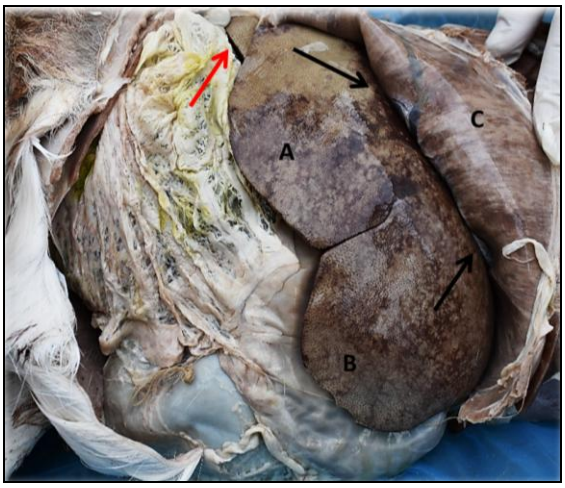

Fig 1: Liver position in situ shows: Right lobe (A), left lobe (B):- Diaphragm (C), left & right triangular ligaments (Black arrows) & caudate lobe (Red arrow)

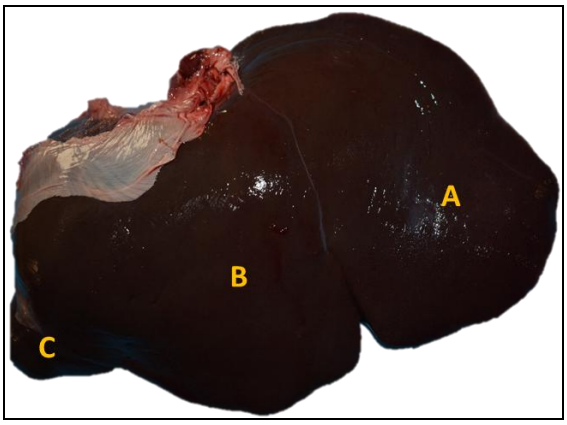

Fig 2: shows the concave parietal surface of the liver:-left lobe (A), Right lobe (B) & caudate lobe (C)

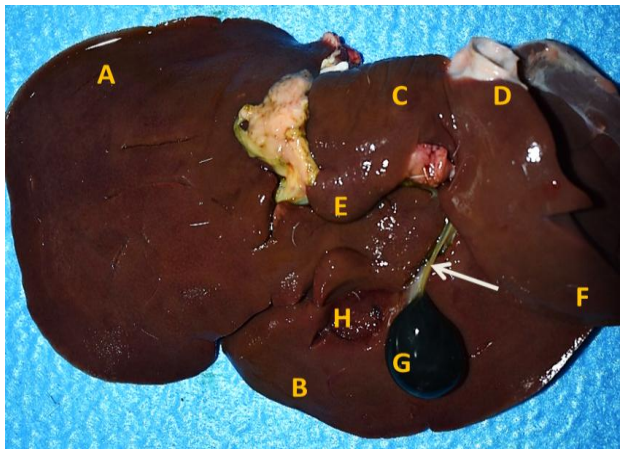

Fig 3: Convex visceral surface of the liver shows: Left lobe (A), Right lobe (B), quadrate lobe (C), caudate lobe (D), papillary process (E),-caudate process (F), gallbladder (G), gallbladder fossa (H) & Cystic duct (arrow).

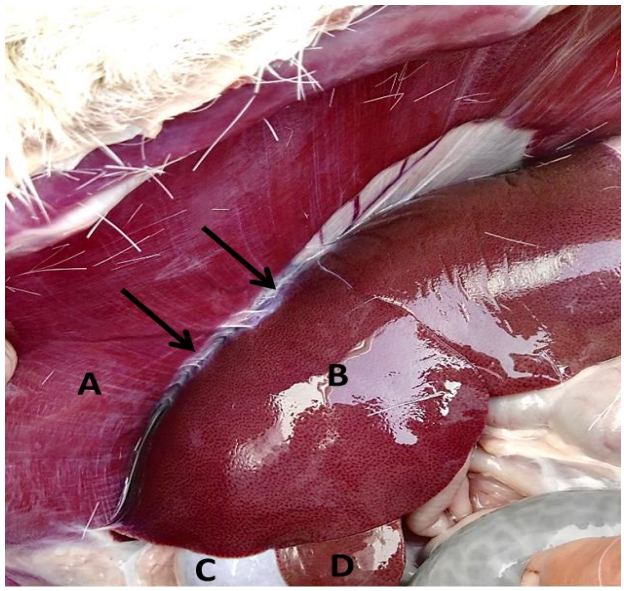

Fig 4: The ligament associated with the liver shows: Diaphragm (A), Triangular ligaments (B), Right kidney (C) and Caudate process (D)

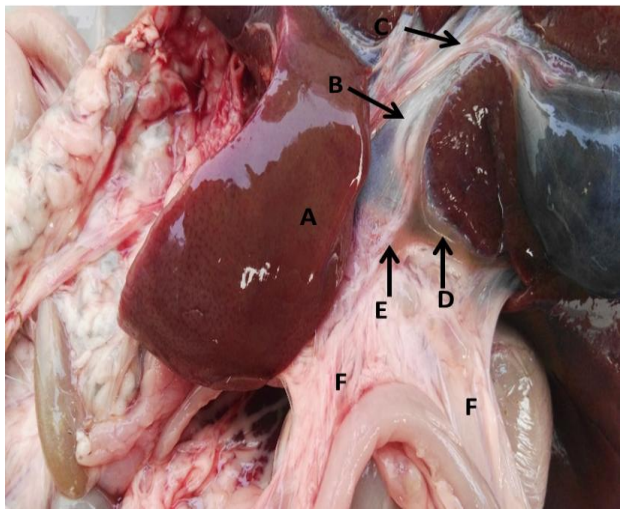

Fig 5: The ligament associated with the liver shows: Caudate lobe (A), right hepatic duct (B), cystic duct (C), left hepatic duct (D), common bile duct (E) & hepatoduodenal ligaments (F).

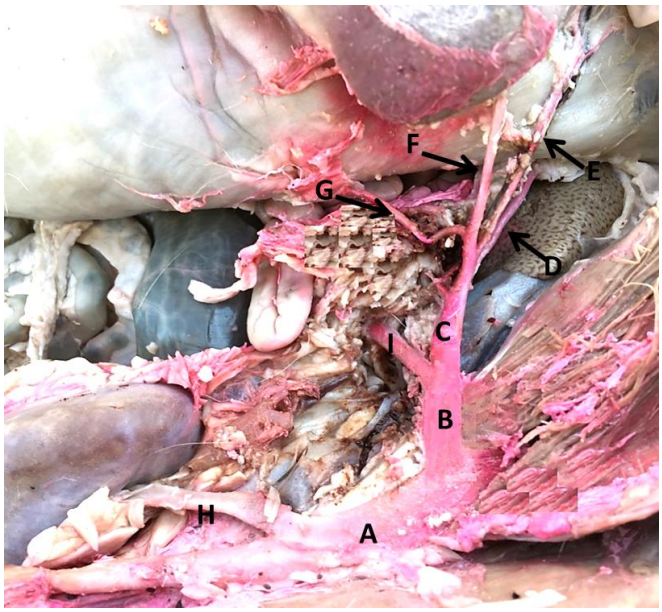

Fig 6: Main blood supply of the liver shows: Aorta (A), celiaco-mesentric trunk (B), celiac artery (C), hepatic artery (D), left ruminal artery (E), splenic artery (F), & left gastric artery (G), renal artery (H) & cranial mesenteric artery (I).

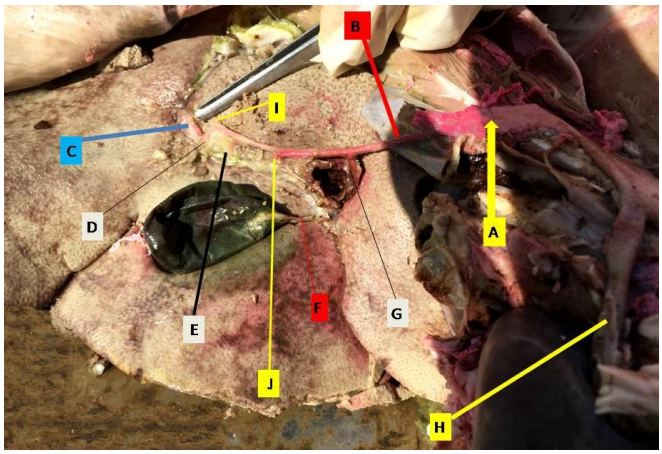

Fig 7: Blood supply show: Celiac artery (A), hepatic artery, lobular hepatic artery(B), (C,D,E,G, pancreatoduodenal artery (J), right gastric artery (I), renal artery (H) and cystic duct artery (F)

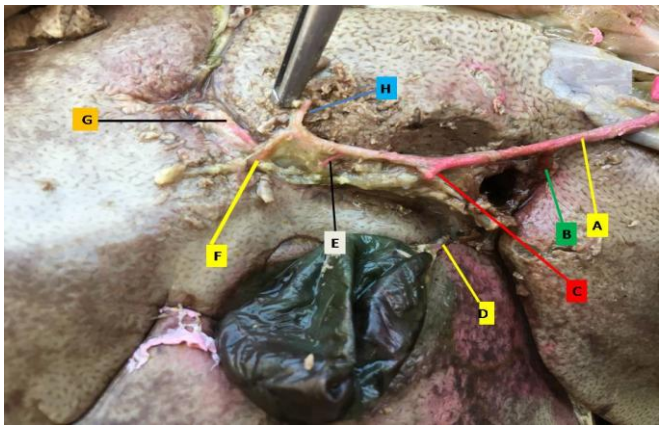

Fig 8: Blood supply of the liver and gallbladder shows hepatic artery (A), lobular hepatic artery B,G,F,E), cystic artery (D), pancreatoduodenal artery (C) & right gastric artery (H).

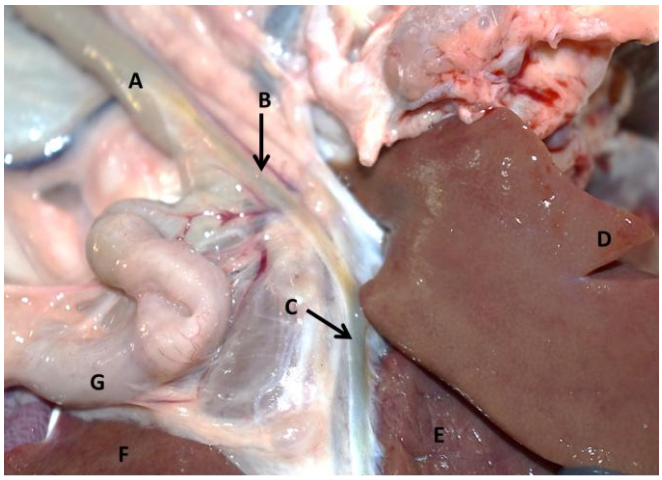

Fig 9: Liver lobe and common bile duct shows: intramural common bile duct (A), retro duodenal common bile duct (B), left hepatic duct (C), caudate process (D), right lobe (E), left lobe (F) & duodenum (G).

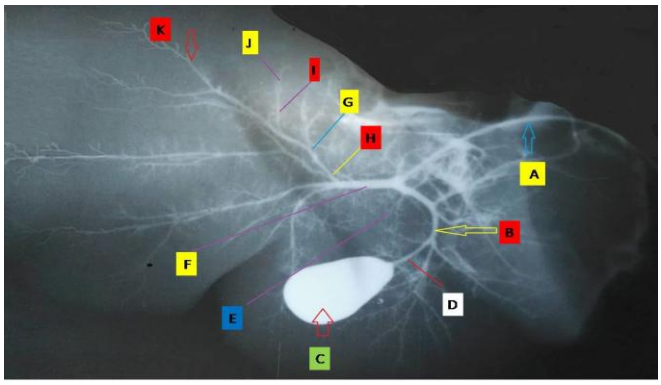

Fig 10: Radiogaphical picture after biligrafin injection as contras media (11)ml shows: common bile duct (A), right hepatic duct (B), gallbladder (C), cystic duct (D), bile tree of the right lobe (E), primary duct (H), secondary duct (G), tertiary duct (I&K), interlobular duct (J) & left hepatic duct (F).



Fig 11: The cast picture after injection of resin shows: gallbladder (A), cystic duct (B), branch of right lobe (C), branch of caudate lobe (D), common bile duct (E), branch of left hepatic duct (F), branch of papillary process (G), right hepatic duct (I), branch of left lobe (J), branch of quadrate lobe (H).

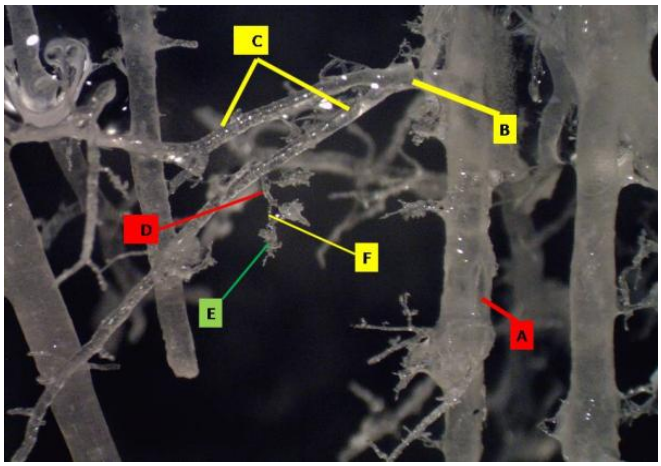

Fig 12: magnification picture by dissecting microscope shows: left hepatic duct (A), primary duct (B), secondary duct (C), tertiary duct (D), interlobular duct (E) & inter lobular duct (F).

6. Acknowledgement
The authors would like to acknowledge all technical staff and assistances in the department of Anatomy, Histology &Embryology-College of veterinary Medicine at University of Baghdad.

7. References

1. Standring S. Gray's Anatomy - Anatomical basis of clinical practice. 40th Ed. Churchill Livingstone, London. 2008, 1173-1175.
2. Hihye C, Seoueon K, Hyunwook K, Junyoung K, Junghee Y. Radiographic liver size in Pekingese dogs versus other dog breed. Veterinary Radiology, Ultrasound. 2013; 54(2):103-106.
3. Mccuskey RS, Zakim IN, Boyer S. Hepatology. A Textbook of Liver Disease. Elsevier. 2012, 3-19.
4. Dyce M, Sack O, Wensing G. Textbook veterinary anatomy 4thEd. Publishing saunder, U. S. A. 2010; 551-220560.
5. Shil KS, Ferdows S, Sutradhar BC, Chandra BD. Topographic anatomy of organs of spotted deer (Axis axis) Research Journal for Veterinary Practitioners. 2014; 2(4):55-57.
6. Braun U, Steininger K. Ultrasonographic characterization of the liver, caudal vena cava, portal vein, and gallbladder in goats. American Journal of Veterinary Research, Schaumburg. 2011; 72(2):219-225.
7. Siddig R, Abdalla A, Ali A. Gross anatomical study on the liver of one humped camel (camelus dromedaries). Journal of Veterinary Medicine and Animal Production.2014; 5(2):17-23.
8. Sajjadian MS, Shojaei B, Zade BS. Computed Tomographic Anatomy of the Abdominal Cavity in the Jebeer (Gazella Bennettii). Research papers. 2015; 12(1):37-43
9. Konig E, Liebich G. Veterinary anatomy of domestic mammlas.3rdEd, Schattauer GMBH. Germany. 2007; 355-360.
10. Bamaniya M, Barolia Y, Mathur R, Shende K, Joshi S. Morphological and Histological study on gallbladder of Marwari goat. International Journal of Science. 2016; 5(6):3713-3718.
11. Kahlil MM, Islam MN, Khlil MM, Khan ZI, Adiluzzaman AA, Hussein M. Topography and morphometry of common bile duct and major duct papilla of man and domesticated animals. Mgmensingh Medical Journal.2005; 14(1):6-12.
12. Osman FA, Wally YR, EI-Nady FA, Rezk HM. Gross anatomical studies on the portal vein, hepatic artery and bile duct in the liver of pig. Journal of Veterinary Anatomy. 2008; 1:59-72.
13. Kingwood SC, Blank DA. Gazella subgutturosa. Mammalian Species.1996; 518:1-10.
14. Abood DA, Hussein ZH. Histological features of vomer nasal organ in Indigenous Gazelle (*Gazella subgutturosa*). Journal of Entomology and Zoology Studies. 2017; 5(4):598-604.
15. Tompestt DH. Anatomical techniques 2ndEd, Longman group limited. London, Great Britain, 1970.
16. Ghoshal NG, Getty R. Comparative morphological study of major arterial supply of thoracic limb of the domestic animals. Anatomia. 1970; 443-447.
17. Baruch Y. The liver: a large endocrine gland. Journal of Hepatology. 2000; 32(3):505-507.
18. Bertevello PL, Chaib E. Hepatic artery system variations correlated to split- liver surgery. Anatomic study in cadavers. Gastroenterology. 2002; 39(2):81-85.
19. Eken E, Gezici M. The Influence of Stomach Volume on the Liver Topography in Cats, Anatomia Histologia Embryologia. 2002; 2:99-104.
20. Abdel-Moniem ME, Abdel-Rahman Y, Alam-Edin MA, El-Nady FA. Changes in the topography of the liver of one humped camel during the prenatal life. Assuit Veterinary Medicine Journal. 2000; 44:22-34.
21. Rantanen NW. Disease of the abdomen. Veterinary Clinic, North America Equine practice.1986; 2(1):67-88.
22. Farag F. Some gross anatomical studies on the liver of the one humped camel (Camelusdromedarius) [dissertation] Cairo: University of Cairo. 1990; 11:153-165.
23. Siddig R. Morphology and morphometry of the liver of the camel (Camels dromedaries) [dissertation] Khartoum: University of Khartoum.2002; 70-83.
24. Juza RM, Pauli EM. Clinical and surgical anatomy of the liver: A review for clinicians. Clinical Anatomy. 2014; 27:764-769.
25. Nowak E, Kuchinka A, Kuder T. Extrahepatic Biliary Tract in Chinchilla (Chinchilla laniger). Anatomia. Histologia Embryologia. 2014; 1-6.
26. Kalt J, Stump E. Gross anatomy of the canine portal vein. Anatomia Histologia Embryologia. 1993; 22:191-197.
27. Chavan NN, Wabale RN. Morphological study of caudate lobe of liver in horse. Indian Journal of Basic and Applied Medical Research. 2014: 3(3):204-211.
28. leJeune S, Whitcomb MB. Ultrasound of the equine acute abdomen. Veterinary Clinic North America, Equine Pract. 2014; 30:353-381.
29. Nagpal SK, Sudhakar LS, Singh G, Dhingra LD, Singh Y. Gross morphology of the liver of camel (Camelus-dromedarius). Indian Journal of Animal and Science. 1985; 55(12):996-1001.
30. Shively M.Veterinary anatomy, basic comparative and clinical.2ndEd, Texas A and M university press, USA. 1987; 256-260.
31. Osman Eel, Morphological and Some Immunohistochemical Observations on the Stomach of the Camel (*Camelusdromedarius*).Thesis, University of Khartoum, 1999.
32. Eisa EI. The Morphology and Morphometry of the Spleen of the One-humped Camel

(*Camelusdromedarius*). Thesis, University of Khartoum, 2000.
33. Yeaser AY, Atyia MA, Hagras SM. Topographical anatomy of sheep. Dar AL-Hikma. University of Mousel, 1990.
34. AL-Mayahi MS. anatomical, radiological and histological study of the gallbladder and biliary duct system (extra and entra hepatic) in small ruminants. Thesis. College of Veterinary Medicine, University of Baghdad, 2008.
35. Carter MM, Detmerd AN. Contribution of the umbilical and portal veins to the hepatic blood supply of guinea pig fetuses angiographic study Laboratory animal Science by American Association for laboratory animal science, 1992.
36. Evan H, Oward E. Guide to the dissection of the dog 11830 west line industrial drive, 2010.
37. Ekataksin W, Wake K. Liver units in three dimensions: I. Organization of a rgyrophilic connective tissue skeleton in porcine liver with particular reference to the "compound hepatic lobule". Am J Anat. 1991; 191(2):113-153.
38. Slieght DR, Thomfoerd NR. Gross anatomy of the blood supply and biliary drainage of the canine liver. Anatomical Research. 1970; 166 (2):153-160.
39. Al-Rekabi AS. Anatomical, radiological and histological study of the gallbladder and biliary duct system (extra and entra hepatic) in indigenous buffalo Bubalusbubalis. M.Sc thesis. College of Veterinary Medicine University of Baghdad, 2011.
40. Rsna S.Potential living liver donors: Evaluation with an all – in one Protocol with multi – detector row C T Radiology. 2012; 224:586-591.