Journal of Entomology and Zoology Studies

Available online at www.entomoljournal.com

E-ISSN: 2320-7078
P-ISSN: 2349-6800
JEZS 2017; 5(6): 773-777

Received: 09-09-2017
Accepted: 12-10-2017

S Sathapathy
Department of Anatomy and Histology, C.V.Sc. and A.H., OUAT, Bhubaneswar, Odisha, India

UK Mishra
Department of Anatomy and Histology, C.V.Sc. and A.H., OUAT, Bhubaneswar, Odisha, India

N Sahoo
Centre for wild life health, Medicine, C.V.Sc. and A.H., OUAT, Bhubaneswar, Odisha, India

C Bhuyan
Department of Preventive Medicine, C.V.Sc. and A.H., OUAT, Bhubaneswar, Odisha, India

Correspondence
S Sathapathy
Centre for wild life health, Medicine, C.V.Sc. and A.H., OUAT, Bhubaneswar, Odisha, India

Histological, histomorphometrical and histochemical studies on the skin of zebra (*Equus caballus*)

S Sathapathy, UK Mishra, N Sahoo and C Bhuyan

Abstract
The histological, histomorphometrical and histochemical studies were conducted on the skin samples of Zebra (*Equus caballus*) died suddenly due to lung infection in the Nandankanan Zoological Park, Bhubaneswar, Odisha on 12th March at 12.30 pm. It was revealed that the epidermis was made up of stratified squamous epithelium, where the keratinocytes were arranged in four strata such as stratum basale or germinativum, spinosum, granulosum and corneum. The stratum germinativum was one cell layer thick. However, the stratum spinosum was 9, 7 and 5 cell layers thick in arm, abdomen and thigh regions respectively. Similarly, the stratum granulosum was 5, 4 and 3 cell layers thick in arm, abdomen and thigh regions respectively. The stratum corneum was 2 cell layers thick. The papillary layer of dermis was prominent in abdomen and thigh regions in zebra. The sweat glands were absent. The sebaceous glands were smaller and have regular pattern of arrangement in the dermis of abdomen, whereas irregularities were found in the skin of arm region with respect to the distribution of sebaceous glands in the dermis. The hair follicles that were associated with the sebaceous glands have less thick cortex and shorter shaft, particularly in the abdominal region of zebra. The quantity of deposition of melanin pigment varied according to the location of different body parts of the zebra and is restricted to the stratum basale layer of epidermis and root of the hair follicles. The above observations and descriptions on skin characteristics of zebra would be useful in the identification of this wild species and would help wildlife students, pathologists and researchers for academic purposes and solving the vetero-legal cases.

Keywords: histological, histomorphometrical, histochemical, skin, zebra

1. Introduction

Zebras are several species of African equids united by their distinctive black and white striped coats. Their stripes come in different patterns, unique to each individual. The unique stripes of zebras make them one of the animals most familiar to people. They occur in a variety of habitats, such as grasslands, savannas, woodlands, thorny scrublands, mountains and coastal hills. That means black is the actual color of the fur, and the white patches are simply the areas that lack pigmentation.

Apart from the aesthetic appreciation of stripped skin of the zebra, it has considerable economic value with regards to the leather, fur and wool industries [6]. The variation of the skin thickness between different sex groups and between different regions of the body is a important aspect [9, 12, 13].

Dermatologic disorders were often encountered by wild life practitioners and require a thorough evaluation, including the duration, distribution, and description of lesions and associated clinical signs. This article reviews the histological features of skin of zebra that may provide practitioners with additional tools to evaluate the skin disorders. The quantity and distribution pattern of sweat and sebaceous glands in the dermis of skin play vital role in developing the adaptive ability of the animal to the heat stress [5].

The skin histomorphometry includes the thickness of different layers of the skin, quantitative estimation of collagen and elastic fiber bundle and skin appendages such as sweat gland, sebaceous gland and hair follicle which provide specialized physiological functions to individuals for environmental adaptation [19]. The skin quality depends mainly on structure and position of collagens and elastic fibers in dermis and their correlation with epidermis, fiber roots, sweat glands and sebaceous glands [4].

The present histological, histomorphometrical and histochemical studies were conducted on the skin samples of Zebra (*Equus caballus*) to establish structural basis, pigmentation pattern and to develop quantitative data that would be useful to the wild life personnel for species identification.

2. Materials and Methods

For the histomorphometrical study, the skin samples were collected from the Zebra (*Equus caballus*) that died suddenly due to lung infection in the Nandankanan Zoological Park, Bhubaneswar, Odisha on 12th March at 12.30 pm. They were fixed in 10% neutral buffered formalin (NBF) for 24-48 hours. They were washed under running tape water overnight and then dehydrated in ascending grades of alcohol. They were cleared in xylene and subsequently embedded in liquid paraffin inside the wax chamber kept at 60^0c for 12 hrs. The blocks were made and sections were cut at 5-6 µm thickness with the digital microtome. The tissue were taken in a clean glass slide and were subjected to various staining procedures such as Haematoxyline and Eosin for normal histo-architecture, Masson's trichrome stain for the presence of collagen fiber and Schmorl's reaction for studying the pigmentation pattern respectively [7]. Histomorphometry was done using LAS software of a semi-motorized microtome (Leica).

3. Results and Discussion

In the present study, the skin of zebra like other mammals comprised of epidermis, dermis and hypodermis.

The epidermis imparts pigmentation, immunologic regulation, and touch perception. It was undulated and consists of a stratified squamous keratinized epithelium that originates from the ectoderm. Further, the epidermis was the non-vascular layer of skin that consisted of keratinocytes arranged in four strata (Fig. 1). These multiple layers of cells underwent a pattern of proliferation, differentiation, and keratinization [15]. The layers were stratum basale or germinativum, stratum spinosum, stratum granulosum and stratum corneum like that of horse [11] and ostrich [3], where as the epidermis of pig has five strata [8] and that of deer has only three strata [10]. The thickness of epidermis varied according to the location of different body parts of the animal. It was 17, 14 and 11 cell layers thick in arm, abdomen and thigh regions respectively. The stratum germinativum was one cell layer thick. However, the stratum spinosum was 9, 7 and 5 cell layers thick in arm, abdomen and thigh regions respectively. Similarly, the stratum granulosum was 5, 4 and 3 cell layers thick in arm, abdomen and thigh regions respectively. The stratum corneum was 2 cell layers thick. The maximum and minimum thicknesses of the epidermis in the abdomen were 42.69 ± 3.52 µm and 32.65± 2.76 µm respectively (Table 1). Moreover, the thickness of keratin layer is 9.924 ± 1.01 µm and height of stratum basale was 19.096±2.12 µm in the abdominal region (Table 1). The maximum and minimum thicknesses of the epidermis in the arm region were 44.625 ± 2.12 µm and 38.454±1.87 µm respectively (Table 1). The thickness of keratin layer is 12.232 ± 1.89 µm and height of stratum basale was 20.132±2.23 µm in the arm region (Table 1). Further, the maximum and minimum thicknesses of the epidermis in the thigh region were 32.402±1.36 µm and 13.257±1.21 µm respectively (Table 1). The thickness of keratin layer is 8.172 ± 1.67 µm and height of stratum basale is 15.186 ±2.37 µm in the thigh region (Table 1). It was found that innermost layer of epidermis consisted of a single layer of stem cells that were columnar or cuboidal type that rested on the basement membrane. They produced continuously new cells in the epidermis and contained melanocytes. The keratinocytes derived from the basal layer form the stratum spinosum, which was one to three cell layers thick. The third stratum of epidermis was the stratum granulosum having granule bearing keratinocytes with indistinguishable nucleus. Further, the keratinization process started at the germinal layer (i.e. stratum basale), where the cells underwent mitosis. As the cells migrated superficially through the stratum spinosum, granulosum, and corneum, they lost many of their cellular characteristics and acted more as a mechanical barrier when they reached the stratum corneum, the outermost stratum. The keratinocytes of this stratum were chromophobic and cytologically homogeneous. The keratin filaments within each cell were oriented parallel to the surface of the skin. Among the outermost cells the superficial ones that were being normally removed were known as stratum disjunctum.

The dermis originated from the mesoderm and was composed of dense irregular connective tissue with collagen, elastin and reticular fibers that lied beneath the epidermal basement membrane, extending to the sub cutis. Collagen was the most abundant structural constituent of the dermis (Ahmad *et al*., 2011) (Fig. 2). It was much thicker than the epidermis and supports the epidermis and provided flexibility to the skin through its composition of elastic and collagen fibers.

Further, the dermis was divided into a papillary layer (i.e., superficial dermis) and reticular layer (i.e., deep dermis). Similar findings were reported in horse (Scott and Miller, 2003 and Wakuri *et al*., 1995) and cattle (Samuelson, 2007). The papillary layer of dermis was prominent in abdomen and thigh regions in zebra. The papillary layer housed the branching nerve endings and vascular capillary network that served to link and nourish the keratinocytes and non-keratinocytes of the epidermis. This layer interdigitated with the epidermis, resulting in formation of dermal papillae, which appeared saw-toothed in shape and created an interface between the dermis and epidermis for strong attachment. The inner reticular layer was characterized principally by the size and density of the extracellular fibers, which were larger and more compact than those comprising the papillary layer. The irregular appearance of collagen and elastic fibers was pronounced. The fibrocyte was the predominant cell type here and was seen in fairly low densities. The sebaceous glands and hair follicles of the skin lied mostly within the reticular layer that provided specialized physiological functions of the animal [19]. Their presence and number varied according to the location of the skin.

No sweat glands were observed in the skin of zebra which is in agreement with the findings of Shambhulingappa *et al* (2014) in Nilgai. The sebaceous glands were simple, branched alveolar glands [2] that secreted an oily material called as sebum. It lubricated and made the skin and hairs waterproof. The secretory cells were small and mostly cuboidal shaped (Fig. 3). The sebum producing cell had a centrally located nucleus and has lost all connections to the basal lamina. The sebaceous glands were closely associated with the hair follicles that together form the pilosebaceous canal. Further, the size of the sebaceous gland was inversely proportional to the size of the hair with which it is associated. The secretory units were saccular or even tubular like that of horse (Samuelson, 2007).

The distribution and number of skin glands varied in zebra according to the location of different regions of the body. The sebaceous glands had regular pattern of arrangement in the

dermis of abdomen, whereas irregularities were found with respect to the distribution of sebaceous glands in the dermis. The sebaceous glands of arm region were comparatively larger in size than those present in the abdomen. Moreover, the numbers of sebaceous glands and hair follicles were comparatively higher in this region than the rest of the body region of the animal.

Further, micrometrical studies were conducted pertaining to the sebaceous glands occurring in different regions of the body of the animal.

1. Abdominal region

The average length and maximum width in the middle of the sac of sebaceous gland were recorded to be 166.994 ±5.04 µm and 159.672±5.12 µm respectively (Table 2). The proximal, middle and distal widths of the sac were found to be 38.786±2.12 µm, 58.154±3.57 µm and 39.543±2.89 µm respectively (Table 2). Further, the length, width of each cell and diameter of the nucleus were 22.178 ±1.88 µm, 17.243±1.37 µm and 3.429±0.73 µm respectively (Table 2).

2. Arm region

The average length and maximum width in the middle of the sac of sebaceous gland were recorded to be 198.246 ±4.57 µm and 178.885±6.33 µm respectively (Table 2). The proximal, middle and distal widths of the sac were found to be 83.377 ±3.36 µm, 91.731 ±3.92 µm and 85.044 ±4.12 µm respectively (Table 2). Further, the length, width of each cell and diameter of the nucleus were 26.216 ±2.08 µm, 19.146±1.87 µm and 7.213±1.16 µm respectively (Table 2).

3. Thigh region

The average length and maximum width in the middle of the sac of sebaceous gland were recorded to be 69.636 ±2.88 µm and 68.885±3.33 µm respectively (Table 2). The proximal, middle and distal widths of the sac were found to be 23.268 ±2.16 µm, 28.562 ±3.67 µm and 25.045 ±2.52 µm respectively (Table 2). Further, the length, width of each cell and diameter of the nucleus were 13.223 ±1.25 µm, 10.866±1.19 µm and 2.587±0.92 µm respectively (Table 2).

Hairs were formed by hair follicles (Fig. 4) that consist of invaginations of the epidermis that have invaded the dermis. They were usually oriented more on a slant, which enhances their ability to provide thermal insulation and water resistance [14]. The hair follicles were rectangular in shape in zebra, which is in line with Shambhulingappa *et al* (2015), who described the shape of the hair follicles as rectangular in wild animals. At the base it had the hair root and adjacent dermal papilla, which protruded into the root. They were together known as hair bulb. The dermal papilla possessed small plexus of blood vessels that fed the root. The innermost portion of the root next to the papilla was the hair matrix, densely packed cells that underwent proliferation and were responsible for hair growth. The cells of the hair matrix were a specialized form of the basal layer of the epidermis. The cells within the central portion of the hair matrix formed the medulla. The cells that enveloped the medulla formed the cortex of the hair. The cortex was 8 and 9 cell layers thick in the arm and abdominal regions respectively. However, the cortex of superficially located hair follicle of thigh region was 12 cell layers thick and that of deep located hair follicle was 5 cell layers thick. The outer lining of cells those were present outside the cortex form the cuticle of hair. There were the presences of outer and inner root sheaths. In conjunction with the hair follicle was one or more small bundle of smooth muscle called the arrector pili, which had one end attached to the side of a follicle and the other end attached near the epidermis within the superficial dermis. When these bundles contracted, the hairs, which were usually positioned at low angles, became erect and stood on end. These muscle fibers contract in low temperatures causing the raised hairs to trap air within the coat, which acts to insulate the body.

Micrometrical observations were also taken which revealed that the hair follicles that were associated with the sebaceous glands have less thick cortex and shorter shaft in the abdominal region of the animal.

4. Abdominal region

The thickness of cortex of hair follicle that were not associated with sebaceous gland were measured to be of 22.487 ±2.22 µm, whereas those were associated with sebaceous gland were having the value as low as 15.883±1.89 µm. The length of the shaft of the hair follicle that were not associated with sebaceous gland were measured to be of 74.833±4.22 µm, whereas those were associated with sebaceous gland were 39.904±3.37 µm longer. Further, the width of the shaft is variable along its length. The proximal, middle and distal widths of the shaft of hair follicle that were not associated with sebaceous gland were measured to be 37.157±3.95 µm, 52.841±4.11 µm and 35.526±3.59 µm respectively(Table 3), whereas those were associated with sebaceous gland have the maximum width as 39.815±3.87 µm at the middle.

5. Arm region

The thickness of cortex of a hair follicle that was not associated with sebaceous gland is measured to be 46.613±2.89 µm. The length of the shaft of the hair follicle that was not associated with sebaceous gland were measured to be of 24.724±3.14 µm. The proximal, middle and distal widths of the shaft of the hair follicle were measured to be 27.324±3.86 µm, 28.258±3.77 µm and 24.987±3.68 µm respectively (Table 3).

6. Thigh region

Similar findings were observed as seen in the skin of the ventral abdominal region of the animal, i.e. the hair follicles that were associated with the sebaceous glands have less thick cortex and shorter shaft. The thickness of cortex of a hair follicle that was not associated with sebaceous gland were measured to be of 89.386±4.57 µm, whereas those were associated with sebaceous gland were having the value as low as 51.404±5.32 µm (Table 3). The length of the shaft of the hair follicle that was not associated with sebaceous gland was measured to be of 57.451±3.92 µm. The proximal, middle and distal widths of the shaft of the hair follicle were measured to be 59.182±4.23 µm, 64.993±4.37 µm and 55.233±3.95 µm respectively (Table 3). Similarly, the length and maximum width of the shaft in the middle of the sebaceous gland that were associated with the hair follicle were found to be 57.209±4.12 µm and 46.208±3.67 µm respectively.

The sub cutis (i.e., hypodermis) was formed by a loose arrangement of collagen and elastic fibers and attached the dermis to the deeper structures of bone and muscle. Within these fibers were variable amounts of fat cells that provide energy, protection, support, and heat insulation in the body.

The present study confirmed that the deposition of melanin pigment was confirmed to the stratum basale layer of the epidermis and the root of the hair follicles (Fig. 5). Further, the quantity of deposition varied according to the location of

different body parts of the zebra. The quantity of melanin deposition was highest in the skin of the arm region of zebra followed by abdomen and thigh regions. Moreover, the hair follicles that were present in the deeper part of the dermis of abdomen contain more melanin pigment than the upper superficial ones. The quantity of melanin deposition was more in the pigmented part of skin than the non-pigmented part of the animal.

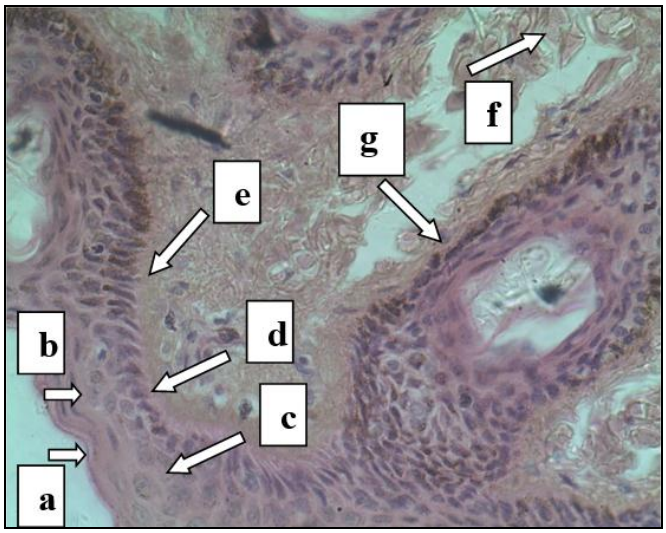

Fig 1: Photomicrograph of skin of abdomen of zebra showing a) Stratum corneum, b) Stratum granulosum, c) Stratum spinosum, d) Stratum basale, e) Papillary layer of dermis, f) Reticular layer of dermis and g) Hair follicle H & E, 45X

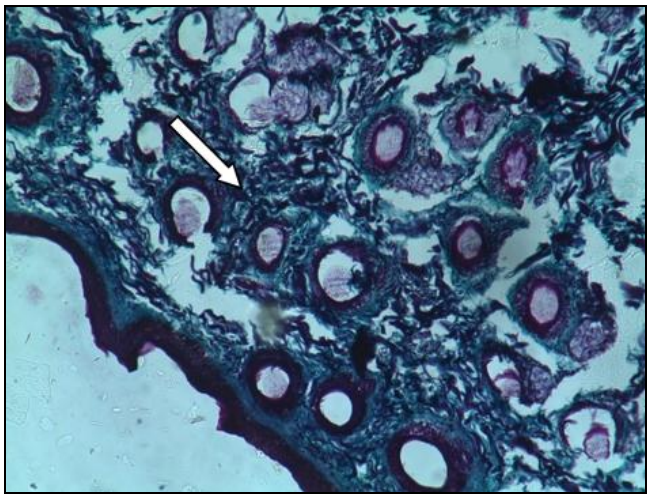

Fig 2: Photomicrograph of skin of thigh of zebra showing presence of collagen fibers (arrow) in the dermis Masson's trichrome, 10X

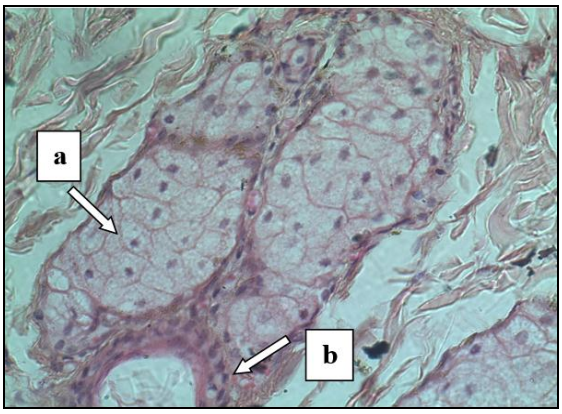

Fig 3: Photomicrograph of skin of abdomen of zebra showing a) cuboidal cells of sebaceous gland and b) Associated hair follicleH & E, 45X

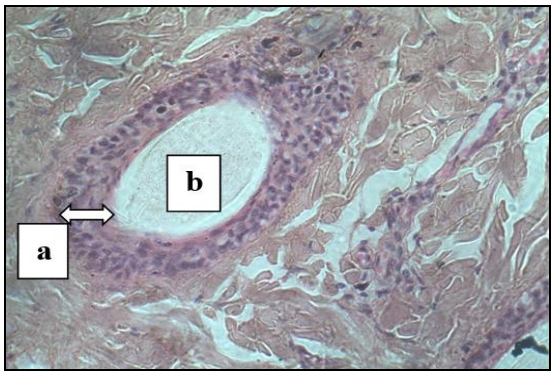

Fig 4: Photomicrograph of skin of abdomen of zebra showing hair follicle in the dermis with a) Cortex and b) Shaft H & E, 45X

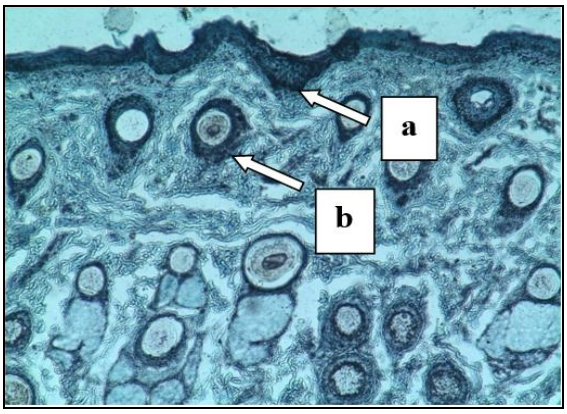

Fig 5: Photomicrograph of skin of arm of zebra showing the deposition of melanin pigment in a) Stratum basale and b) Root of hair follicle Schmorl's reaction, 10 X

Table 1: Micrometrical observations of epidermis and its different strata in various regions of zebra under 10X magnification

Parameters (in µm)	Regions		
Range (Mean ± SE)	Arm	Abdomen	Thigh
Maximum thickness of epidermis	44.625 ± 2.12	42.69 ± 3.52	32.402±1.36
Minimum thickness of epidermis	38.454±1.87	32.65± 2.76	13.257±1.21
Thickness of stratum corneum	12.232 ± 1.89	9.924 ± 1.01	8.172 ± 1.67
Height of stratum basale	20.132±2.23	19.096±2.12	15.186 ±2.37

Table 2: Micrometrical observations of sebaceous gland of dermis of skin in various regions of zebra under 40X magnification

Parameters (in µm)	Regions		
Range (Mean ± SE)	Arm	Abdomen	Thigh
Average length	198.246 ±4.57	166.994 ±5.04	69.636 ±2.88
Maximum width	178.885±6.33	159.672±5.12	68.885±3.33
Proximal width of the sebaceous sac	83.377 ±3.36	38.786±2.12	23.268 ±2.16
Middle width of the sebaceous sac	91.731 ±3.92	58.154±3.57	28.562 ±3.67

Distal width of the sebaceous sac	85.044 ±4.12	39.543±2.89	25.045 ±2.52
Length of cell of sebaceous gland	26.216 ±2.08	22.178 ±1.88	13.223 ±1.25
Width of cell of sebaceous gland	19.146±1.87	17.243±1.37	10.866±1.19
Height of nucleus of cell of sebaceous gland	7.213±1.16	3.429±0.73	2.587±0.92

Table 3: Micrometrical observations of hair follicle of dermis of skin in various regions of zebra under 40X magnification

Parameters (in µm)	**Regions**		
Range (Mean ± SE)	Arm	Abdomen	Thigh
Thickness of cortex	46.613±2.89	22.487 ±2.22	89.386±4.57
Length of shaft of hair follicle	24.724±3.14	74.833±4.22	57.451±3.92
Proximal width of shaft of hair follicle	27.324±3.86	37.157±3.95	59.182±4.23
Middle width of shaft of hair follicle	28.258±3.77	52.841±4.11	64.993±4.37
Distal width of shaft of hair follicle	24.987±3.68	35.526±3.59	55.233±3.95

4. Conclusion

The skin of a zebra was well organized and functional, protected it from mechanical injury, heat stress and acted as an immunologic sentinel for the body. The variation in the thickness of skin, quantity and pattern of pigmentation and distribution of skin appendages in different regions of the body provided uniqueness to this species of animal. The above observations and descriptions of skin characteristics of zebra would be useful in the identification of this wild species which were poached by the poachers. Observations made by this study would help wildlife students, pathologists and researchers for academic purposes and solving the vetero-legal cases.

5. Acknowledgement

The Authors are much grateful to the Head of the Department of Anatomy and Histology and Director, Centre for Wild life Health, C.V. Sc. and A.H., OUAT, Bhubaneswar for their constant guidance and providing necessary facilities to carry out the research work within the period of time.

6. References

1. Ahmad MS, Sathyamoorthy OR, Ramesh G, Balachandran C. Micrometrical studies on the skin of madras red sheep (Ovis aries) in different age groups. Tamil nadu Journal of Veterinary & Animal Sciences. 2011; 7(1):23-28.
2. Aughey E, Frye F. Comparative Veterinary Histology with Clinic Correlates. 1st. ed, Manson, London, 2001, 129-130.
3. Foroogh S, Sara D, Mahsa M. Histological study of Ostrich skin after Biopsy. Iranial Journal of Veterinary Science. 2013; 8(1):53-58.
4. Genkovski D, Gerche G. Study of the skin histological structure in ewes from staroplaninska and thorough bred Tsigai. Biotechnology in Animal Husbandry. 2007; 23(5-6):191-197.
5. Hussain AM. The histological relationship between the environmental stress and milk production in Iraqi Buffaloes; Bubalus bubalis. Journal of Entomology and Zoology Studies. 2016; 4(3):19-22.
6. Konig HE, Liebich HG. Veterinary Anatomy of Domestic mammals. Schatter, New York. 2004, 585-635.
7. Luna IG. Manual of histological staining methods of the armed forces institute of pathology. 3rd ed. New York: McGraw Hill Book Company, 1968.
8. Meyer W, Scharz R, Neurand K. The skin of domestic mammals as model for human skin with apical references to the domestic pig. Current Problems in Dermatology. 1978; 7:39-52.
9. Mobini B, Faradonbeh KS. A morphometric study on differentregions of the skin in lori-Bakhtiari sheep at different ages. International Journal of Plant, Animal and Environmental Science. 2012; 2(4):180-185.
10. Nagaraju G, Prasad R, Jamuna K, Ramkrishua V. Histomorphological Featur in differentiation of Skin of Spotted Deer, Cattle and Goat. Indian Journal of Veterinary Anatomy. 2012; 24(1):10-12.
11. Obayes Ali Khudheyer. Histological study of skin of horse. Tikrit Journal Pure Science. 2016; 21(1):31-35.
12. Renani HRA, Salehi M, Ebadi Z, Moradi S, Baghershah HR, Renani MYA *et al*. Determination of hair follicle characteristics, density and activity of Iranian cashmere goat breeds. Small Ruminant Research. 2011b; 95:128-132.
13. Salehi M, Lavvaf A, Farahvash T. Skin quality and physical properties of leather based on sex, age and body parts of goats rewered on sub-humid hill country. Iranian Journal of Applied Animal Science. 2013a; 3(4):853-857.
14. Samuelson Don A. Textbook of Veterinary Histology. 1st edn. Elsevier, USA, 2007, 271-299.
15. Schummer A, Wikens H, Vollmerhause B. Skin and cutaneous organs of the horse. New York. Springer, 1981, 537.
16. Scott DW, Miller WM. Skin immune system and allergic Scott, D.W., Miller, W.M. (eds): Equine Dermatology. Philadelphia, WB Saunders, 2003, 1-34:436-440, 446-448.
17. Shambhulingappa YB, Prasad RV, Jamuna KV, Narayanaswamy HD, Narayana BM, Ramkrishna V *et al*. Histological characteristics of hair follicle pattern in Indian bison (Bos gaurus), Black buck (Antelope cervicapra) and Nilgai (Boselaphus tragocamelus). Veterinary World. 2014; 7:189-193.
18. Wakuri H, Muton K, Ichikawa H. Microscopic anatomy of equine skin with the special reference to the dermis.Okajima Folia Anato- mical Japanica. 1995; 72(2-3):177-183.
19. Wildelitz Randall B, Ting Xin J, Alexandra IV, Sheree A, Ting Berreth FY, Han Sung J *et al*. Molecular histology in skin appendage morphogenesis. Microscopy Research and Technique. 1997; 38:452-465.