Journal of Entomology and Zoology Studies

Available online at www.entomoljournal.com

E-ISSN: 2320-7078
P-ISSN: 2349-6800
JEZS 2017; 5(6): 1301-1304

Received: 15-09-2017
Accepted: 18-10-2017

Amer M Hussin
Assist. Prof. Dr., Anat. Dept., Coll. of Vet. Med. University of Baghdad, Iraq

Mustafa AL- Badrani
Student Master. Anat. Dept., Coll. Of Vet. Med. University of Baghdad, Iraq

Correspondence
Amer M Hussin
Assist. Prof. Dr., Anat. Dept., Coll. of Vet. Med. University of Baghdad, Iraq

Histological adaptive changes of adrenal cortex in adult male indigenous Gazelle *"Gazella subgutturosa"*

Amer M Hussin and Mustafa AL-Badrani

Abstract
This study was designed to focus the light on the histological adaptive changes that occurred in the tissues of adrenal gland of gazelle in response to the mechanism of flight or fight. The study was carried out on 10 adult male gazelle that were collected from Baghdad province in 2017. Immediately after slaughtering, samples of adrenal tissue were collected from these gazelle, fixed with 10% Neutral Buffered formalin and processed for light microscopy. The process of slaughtering represents the fight or flight response. The present study revealed that gazelle had well developed adrenals. The adrenal gland was surrounded by large well developed capsule. The capsule contains ovoid reservoir structures includes primordial undifferentiated cells. These capsular reservoirs replace the exhausted or dead cell in the underlying zones of adrenal with compensatory cells. The capsule was lined by extensive adipose tissue layer. The adrenal gland characterized by a well-developed adrenal cortex. This cortex contains well-developed two zones, the zona glomerulosa and zona fasciculata on account of the small developed zona reticularis. The zona glomerulosa was wide containing two layers: outer dark and inner pale. High mitotic figures and binucleated cells were observed in the first two layers of adrenal cortex. The study concluded that gazelle contains efficient well developed adapted adrenal gland to withstand the predators during fight or flight response. The study declared firstly the presence of undifferentiated primordial cells out and in the lumen of blood vessels. So that, additional way for cellular migration via blood stream was considered for the first time in the present study. The study declared that in gazelle, in spite of the efficient adrenals, its size was adaptively decreased.

Keywords: Gazelle, adrenal, histology, adaptation

1. Introduction
Different organs of the body were encapsulated by different capsules. However, most consisted of connective tissue with epithelioid cells lies among these constituents Raso *et al* [1]. Bandiera *et al.* [2] stated that, by embryonic day 12.5 in mice, the developing adrenal gland becomes surrounded by condensing mesenchymal cells that form the capsule. Vidal *et al* [3] reported that adrenal glands act to replace the damaged cells of the underlying glomerulosa zone and are zonated endocrine organs that are essential in controlling body homeostasis. Capsules remain in adult life to compensate the lost and damaged cells of zona glomerulosa. Bartoli *et al* [4] reported that the capsule thickness was correlated strongly with vascular density and modestly with blood flow. Cells of adrenal cortex have characteristic features of steroid-secreting cells [5]. The permanent cortex is formed through the supply of capsular cells by the adrenal progenitor cells that have lost King *et al* 2009[6], and Wood *et al* [7]. How renewal of the adrenal cortex is ensured remain as un dissolved mystery. The thickness zones of adrenal cortex in gazelle were smaller than in other animals [8]. The adaptations of gazelles can be seen in the physical stature of these animals. Their medium size means less skin area for excess moisture loss through evaporation. Their long limbs allow them to sprint rapidly out of the range of predators. The Thomson's gazelle can reach speeds up to 40 miles per hour [9].

2. Materials and methods
The present work was designed to study the histological feature of the adrenal gland in healthy adult male gazelle *"Gazella subgutturos"*. Ten of adrenal glands were collected from (Baghdad) in 2017. The specimens were collected 20 minutes after slaughtering. The samples were included the right and left adrenal glands. Capturing of the animals, tighting, weighing, preparation of the animal for slaughtering, were lasted for more than one hour.

This process was carried out in college of veterinary medicine. The glands were washed with distilled water and the samples were put in a plastic container with 10 % formalin solution. Tissues were processed by routine histological techniques for histological analysis with light microscopy. Hematoxylin and eosin stain was used for staining [10], and Masson's trichrome stain [11]. Color USB 2.0 digital camera (Scope Image 9.0) was used to achieve the micromorphometric measurements which is provided with image processing software connected to light microscope.

3. Results

The present study revealed that the adrenal gland of gazelle had prominent well developed zona glomerulosa and zona fasciculate compared to poorly developed zona reticularis (table). The adrenal gland was enriched with abundant blood supply, lymphatic vessel and nerve fiber (Fig.1). The result referred that the capsule of gazelle was efficient. Moreover, the capsule contained extensive reservoirs of undifferentiated primordial epithelioid adrenal cells. These cells had round to ovoid pale nuclei. As noted, these cellular reservoirs appeared as compact ovoid structures embedded within the connective tissue of the capsule (Fig.2). Thick adipose tissue layer was also present under the capsule with high blood vascularization and abundant collagen fibers (fig.3). The zona glomerulosa of adrenal cortex was relatively wide and had two cluster types, outer smaller with acidophilic dark cytoplasm, and inner larger with paler cytoplasm. The nuclei were small, dark, and centrally located (Fig. 4). On the other hand, the present study found that the architecture of the cells of zona fasciculata lacks the obvious limits (fig.4). No clear line of demarcation between zona fasciculata and zona reticularis (fig.5). The result found the presence of undifferentiated primordial cells out and in the lumen of the capsular blood vessels. These cells were not similar to blood cells (Fig.6). The thickness of adrenal cortex and medulla in gazelle was adaptively smaller than in other animals.

Table: Dimensions of the cortical zones in adrenal cortex and its cells and nuclei (µm)

	Thickness (µm) Mean±SE	**Cells diameter large \ small Spherical clusters (µm) Mean±SE**	**Nucleus diameter large \ small Nucleus of spherical clusters (µm) Mean±SE**
Zona glomerulosa	120±1.9	37.7±0.5 \ 25.6±0.3	4.5±0.3 \ 4.5±0.3
Zona fasciculate	750±31.7	16.2±0.4	4±0.4
Zona reticularis	75±1.9	12.7±0.3	4.2±0.2

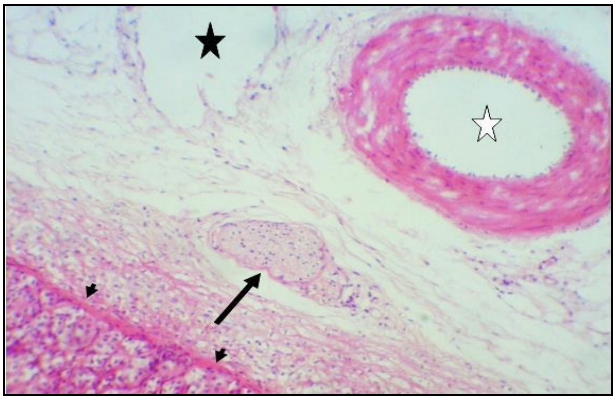

Fig 1: Capsule of adrenal gland of gazelle. Note the blood vessel in the capsule (white star). Lymphatic vessel (Black star). Large black arrow refers to the nerve fiber. Arrow heads indicate the limits of zona glomerulosa of the gland. X400. H & E stain.

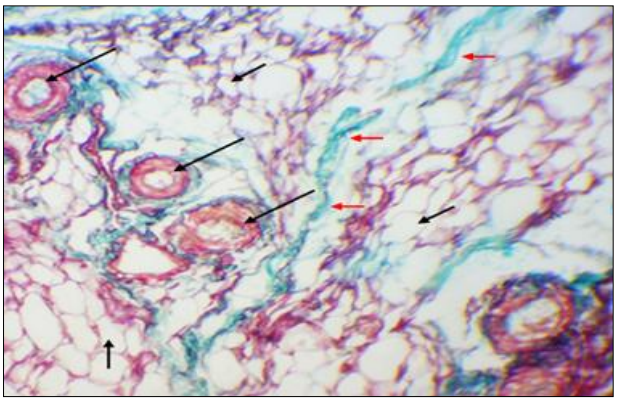

Fig. 3: High magnification of the capsule of gazelle, note the high vascularization with blood vessels (large arrows), and abundant adipose tissue (small arrows). Red arrows indicate collagen fibers. X 400. Masson's trichrome stain.

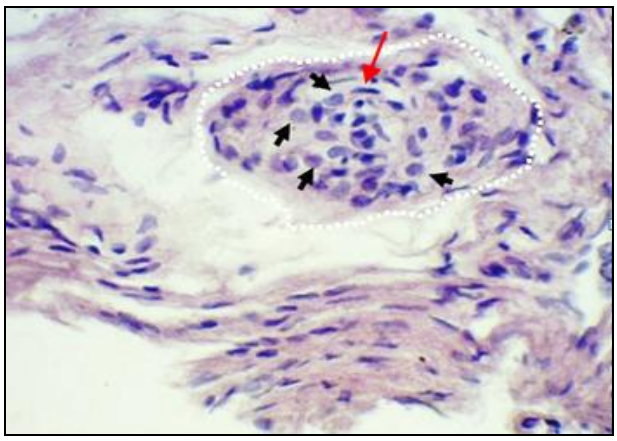

Fig 2: Capsule of adrenal gland of gazelle. Note the ovoid structure (dotted circle) of the primordial undifferentiated cells. The primordial cells had rounded to ovoid pale nuclei (arrows) intermingled with the fibroblast cells having elongated dark nuclei (red arrow). X400. H & E stain.

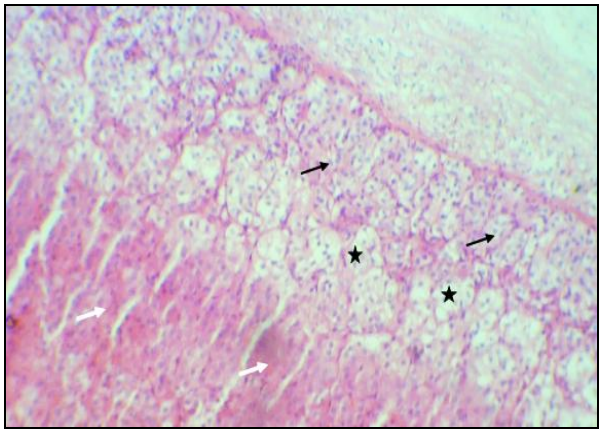

Fig 4: Adrenal cortex showed Prominent zona glomerulosa with two cellular clusters; small clusters of zona glomerulosa (black arrows), and large clusters of zona glomerulosa (Black stars). White arrows refer to the well-developed zona fasciculata with eosinophilic abundant cytoplasm. X 400. H & E stain.

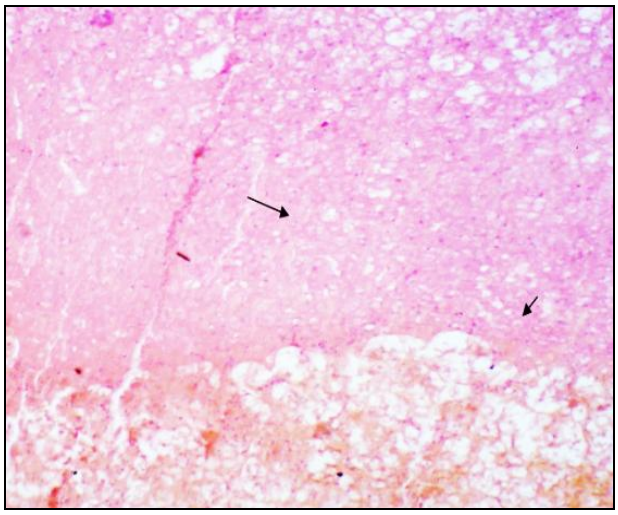

Fig 5: Low magnification of adrenal gland showing no clear line of demarcation between zona fasciculata (large arrow) and zona reticularis (small arrow).X 100 H&E stain.

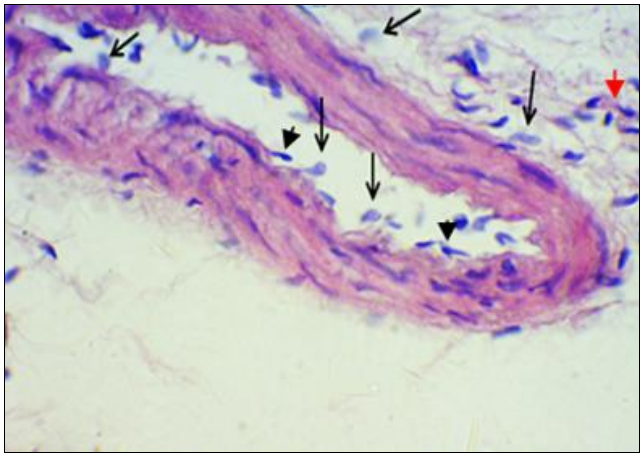

Fig 6: Nuclei of undifferentiated primordial capsular cells out and in the lumen of blood vessel of the capsule (black arrows). Arrow heads refer to the nuclei of endothelial cells. Red arrow indicates fibroblast. X400. H & E stain.

4. Discussion

This study depended on the fact that when any animal has been slaughtered, it will be subjected to a state of challenge similar to the physiological fight or flight response. This was confirmed with [12]. Who reported that within 15 minutes, fine structural changes may be detected post-operative in male albino rats. The present study was in consistent with Bartoli *et al* [4]. Who referred to the relation between the efficiency of adrenal gland and its containing of abundant blood vascular supply and adipose tissue. The presence of the primordial epithelioid cells may be related to the morphological adaptation of the gland to endocrine requirement during the defensive state of the gazelle against predatory animals. The zona glomerulosa in gazelle was well developed and not similar to human adrenals that were poorly developed as their cells have deeply staining nuclei with scanty basophilic cytoplasm with [13]. The high cellularity of zona fasciculata decreases the clarity of the common architecture of the zone and concealed the limits between the cells themselves of the zone. The absence of clear boundary between this zone and the underlying zona reticularis indicate the cellular exchange between the two zones. The present study regarded the type of migration of the capsular cells to the underlying zones as inward migration [13, 14]. Who reported that new cells arise in the glomerulosa, move inward through the fasciculate in correlation to the secretory changes and finally degenerate in the reticularis. This was in variance with [15, 16]. Who regarded the migration as centripetal migration. The study monitored firstly another type of migration, namely the blood stream migration, from the capsule to the underlying zones via blood to cover the need and to compensate the exhausted or dead cells during fight and flight mechanism. These primordial cells can pass through the opening present in the sinusoidal capillaries of the capsule of adrenal gland [17, 18]. Similarly, when bone marrow forms new blood cells, these cells must enter the blood circulation via the sinusoidal capillaries. Moreover, many cells can travel through the wall of the blood vessels, Monocytes and neutrophils can migrate through blood vessels by the process called diapedesis [5]. Besides, adipose tissue can travel through blood stream Vidal *et al*[3],Wood *et al*[7], and[17].The absence of mitotic processes in adrenal cortex indicates that the undifferentiated primordial cortical cells cover this area. On the other hand, the presence of mitotic figures in the cells of adrenal medulla refers to the absence of these capsular primordial cells. The study hypothesized that Mitosis hinders other cellular activity like movement. The study revealed that the gazelle had an efficient well developed adrenal gland. It was concluded that the regeneration and replacement of the damaged and dead tissues of adrenal cortex take place through compensation by undifferentiated primordial cortical cells. The gazelle showed physical adaptation in its structure and organs, so that the size of their organs especially adrenals was decreased in spite of its efficiency, that's to escape from the predators animals. This was confirmed by [18]. The present study concluded that there were two pathways for compensatory cellular transportations, cellular and humoral migration.

5. Conclusion

It was concluded from the result of the present study on the adrenal gland of the gazelle that:

1. Any animal subjected continuously for a long period of time to fight or flight response from predator animals will showing an adapted well developed adrenal gland.
2. Compensatory ovoid clusters of undifferentiated cells were present in the capsule.
3. When there is clear line of demarcation between two zones that mean there is no cellular interchange between them, On the other hand no clear line demarcation refers to cellular exchange between the two layers.
4. 4-The present study concluded that there were two pathways for compensatory cellular transportations, cellular and humoral migration.
5. The size of adrenals and the thickness of their zones varies with the species and sex.
6. In spite of the efficiency of the adrenal in gazelles, their sizes were adaptively decreased.

6. Acknowledgment

This work is the result of cooperation between the colleges of veterinary medicine of Baghdad and Mosul universities Authors would like to thank the Iraqi natural history research center and museum, university of Baghdad, for providing histology laboratory facilities.

7. References

1. Raso DS, Crymes LW, Metcalf JS. Histological assessment of fifty breast capsules from smooth and textured augmentation and reconstruction mammoplasty prostheses with emphasis on the role of synovial

metaplasia. Mod Pathol. 1994; 7(3):310-6.
2. Bandiera R, Vidal VP, Motamedi FJ, Clarkson M, Sahut-Barnola I, von Gise A *et al*. WT1 maintains adrenal-gonadal primordium identity and marks a population of AGP-like progenitors within the adrenal gland. Dev Cell. 2013; 27(1):5-18.
3. Vidal V, Sacco S, Rocha AS, Silva FD, Panzolini C, Dumontet T *et al*. The adrenal capsule is a signaling center controlling cell renewal and zonation through R spo3. Genes Dev. 2016; 30(12):1389-1394.
4. Bartoli CR, Nadar MM, Godleski JJ. Capsule thickness correlates with vascular density and blood flow within foreign body capsules surrounding surgically implanted subcutaneous devices. Artif Organs. 2010; 34(10):857-861.
5. Mesher AL. Junqueira's basic histology. Edn 12, Mc Graw, Hill Medical, 2009; 1:207-355.
6. King P, Paul A, Laufer E. Shh signaling regulates adrenocortical development and identifies progenitors of steroidogenic lineages. Proc Natl Acad Sci U S A. 2009; 106(50):21185-21190.
7. Wood MA, Acharya A, Finco I, Swonger JM, Elston MJ, Tallquist MD *et al*. Fetal adrenal capsular cells serve as progenitor cells for steroidogenic and stromal adrenocortical cell lineages in *M. musculus*. Development. 2013; 140(22):4522-32.
8. Prasad G, Sinha RD. Micometric observations on the adrenal glands of domestic animals. Ind. J Anim. Sci. 1981; 51(12):1144-1147.
9. Estes RD. The Behavior Guide to African Mammals: including Hoofed Mammals, Carnivores, and Primates. New Ed edition, Vol. 1, University of California Press. 1992, 634.
10. Suvarna SK, Christopher L, Bancroft JD. Theory and Practice of Histological Technique. Edn 3rd, N.Y. New York, Churchill Livingstone, 2013; 1:109-121.
11. Luna G. Manual of histological staining methods of the armed forced institute of pathology. Edn 3rd, New York, Blakiston McGraw-Hill, Division. 1968; 1:258.
12. Adrian I. Katz**.** Renal function immediately after contralateral nephrectomy: relation to the mechanism of compensatory kidney growth. Yale J Biol Med. 1970; 43(3):164-172.
13. Bajpai RN, Human Histology. Edn 2nd, Jaypee, 1982, 194.
14. Copenhaver WM, Bunge RP, Bunge MB. Bailey's textbook of Histology. Edn 16th. The Williams & Wilkins Company, Baltimore, 1971, 651.
15. Pawlikowiski M. Adrenal cortex- the next biological clock Neuroendocrinology letters. Neuroendocrinology Letters. 2005; 26(3):194-195.
16. Walczac EM, Hammer GD. Regulation of the adrenocortical stem cell niche: implications for disease. Nature Review Endocrinology. 2015; 11(1):14-28.
17. Ganong WF. Medical physiology. Edn 23th. New York, Chicago San Francisco, 2005, 298.
18. Kol'tiukova NV. Morphological changes in the adrenal gland during adaptation to multiple individually measured physical loads. Morfoloqiia. 1997; 111(2):79-83.