Journal of Entomology and Zoology Studies

Available online at www.entomoljournal.com

E-ISSN: 2320-7078
P-ISSN: 2349-6800
JEZS 2018; 6(1): 473-476

Received: 14-11-2017
Accepted: 15-12-2017

**Nanaboina Ramesh**
MVSc, Surgery, College of Veterinary Science, Rajendranagar, PVNR Telangana Veterinary University, Hyderabad, Telangana, India

**EL Chandra Sekhar**
Professor and Head Department of Surgery and Radiology, College of Veterinary Science, Korutla, Jagtial (Dst), PVNR Telangana Veterinary University, Hyderabad Telangana, India

**KBP Raghavender**
Professor and University Head, Department of Surgery and Radiology College of Veterinary Science, Rajendranagar, PVNR Telangana Veterinary University, Hyderabad, Telangana, India

**G Purushotham**
Professor, Department of Veterinary Anatomy and Histology, College of Veterinary Science, Rajendranagar, PVNR Telangana Veterinary University, Hyderabad, Telangana, India

**Correspondence**
**Nanaboina Ramesh**
MVSc, Surgery, College of Veterinary Science, Rajendranagar, PVNR Telangana Veterinary University, Hyderabad, Telangana, India

# A clinical study on the use of veterinary Cuttable plates for femoral diaphyseal fractures in small dog breeds and puppies

**Nanaboina Ramesh, EL Chandra Sekhar, KBP Raghavender and G Purushotham**

**Abstract**
Six immature young dogs (2-8 months old, body weight ranging from 4-14 kg) were presented to Campus Veterinary Hospital, College of Veterinary Science, Rajendranagar were diagnosed to have femoral diaphyseal fractures. Physical examination and Radiography aided in diagnosis. The femur was approached through a cranio-lateral border of thigh for plating. Selection of plate and screws were determined by taking in to consideration of the size of the bone, fracture configuration and weight of the dogs. In all the six cases, the fracture was stabilized with indigenously designed 2.0 mm and 2.7 mm Veterinary Cuttable plates (VCP) along with compatible size of cortical screws under sedation with Xylazine Hydrochloride and Intravenous general anaesthesia with Propofol. Fracture healing was assessed periodically by taking plain radiographs. Postoperatively, all six cases showed complete weight bearing in an average of 30-45 days.

**Keywords:** dogs, femoral diaphyseal fractures, radiographs, veterinary cuttable plates

## 1. Introduction

Diaphyseal femoral fractures are common in young growing dogs resulted most of the times of trauma. External coaptation methods, such as casts or splints are ineffective and contraindicated for repair of femur in dogs due to the anatomical orientation of the hind limb. Internal fixation of long bone diaphyseal fractures in puppies has to take into account the particularities of growing bones. In puppies, the surgical technique has to not only ensure alignment and apposition of bone fragments but also prevent iatrogenic damage of growth plates and the periosteum. During the initial growth phase, both structural and material properties of immature bone are considerably different from those of adult bone and are characterized by lower strength, as well as lower yield stress and elastic modules. In addition, the diaphyseal cortices are considerably thinner in young dogs compared to adults [5].

Consequent upon the above mentioned facts, Veterinary Cuttable Plates (2.0mm and 2.7mm) has been developed and is gaining acceptance among practicing veterinarians. The Veterinary Cuttable Plates (VCPs) can be cut to a desired length (Fig.1), to suit the bone length and can also be applied stacked on top of one another, if need be. Since the VCPs are narrow and thin and also have the property of elasticity, they are suitable for fracture repair in growing dogs [14] for internal fixation of long bone fractures in young dogs. In the present study use of veterinary cuttable plates for femoral diaphyseal fractures in small dog breeds and puppies was discussed.



**Fig 1:** 2.0 & 2.7 mm VCPs and screws

## 2. Materials and Methods

The present study was carried out in six young dogs with femoral diaphyseal fractures. The type of fracture and its severity was assessed by physical examination of the animal and radiography of the affected limb. The anamnesis of all the six animals was shown in Table.1.

**Table 1:** Anamnesis of the six animals

| S. No. | sex | Age/ months | Breed | Weight/Kg | Location of femur fracture | Type of fracture |
|---|---|---|---|---|---|---|
| 1 | Male | 5 | Non-descript | 9 | Mid-diaphyseal | Closed Complete short oblique overriding |
| 2 | Male | 6 | Non-descript | 11 | Mid-diaphyseal | Closed Complete short oblique overriding |
| 3 | Female | 5 | Non-descript | 9 | Mid-diaphyseal | Closed Complete transverse overriding |
| 4 | Male | 4 | Non-descript | 4 | Proximal-diaphyseal | Closed Complete transverse overriding |
| 5 | Female | 4 | Non-descript | 8 | Distal-diaphyseal | Closed Compete transverse overriding |
| 6 | Male | 8 | Non-descript | 14 | Distal-diaphyseal | Closed Compete transverse overriding |

All the six dogs were given a first aid for the fracture on the day of their presentation and advised 12 hours fasting prior to surgery. Temporary stabilization of the fracture site was done by application of Robert jones bandage, till the date of surgery. The affected limb was aseptically prepared by clipping the hair and operative site was shaved and scrubbed using povidone iodine surgical scrub. All the animals were prepared for aseptic surgery and were sedated with intramuscular injections of Xylazine hydrochloride @ 0.05 mg/Kg body weight. Following induction with ketamine hydrochloride @ 10 mg/kg body weight, anaesthesia was maintained with intravenous infusion of propofol at the rate of 4 mg/kg body weight.

All the dogs with fractures of femur were positioned in lateral recumbence with the fractured limb up. The distal extremity of the limb was covered with a sterile gauze bandage. The prepared site was painted with 5 % povidone iodine solution followed by application of surgical spirit. A skin incision was made along the craniolateral border of the thigh extending from the trochanter major to the lateral condyle of the femur (Fig. 2). Following separation of subcutaneous tissue, the tensor fascia lata muscle was incised to expose the biceps femoris and vastus lateralis muscles. After reduction of the fracture fragments to their normal anatomical position (Fig. 3), the Veterinary Cuttable Plate was cut to the required size by first making a mark on the plate using an orthopedic file and was then cut using a pin cutter (Fig. 4). The plate was then positioned over the femoral diaphysis in such a way that the fracture line was approximately mid-way between the ends of the VCP. A hole was drilled across the femoral diaphysis through the proximal-most hole of the VCP (Fig. 5) using a low speed high torque electric drill. In cases where 2.7 mm plate and screws were used, a 2 mm drill bit was employed and when 2 mm plate and screws were used, a 1.5 mm drill bit was employed to drill the holes through the femoral diaphysis. A screw of suitable length was then placed at the drilled hole and tightened using a hexagonal orthopaedic screw driver until the screw tip exited the far cortex to secure the plate to the bone. Similarly, the distal-most screw was also inserted.

**Fig 2:** Skin incision of a dog made from trochanter major to lateral condyle of the femur

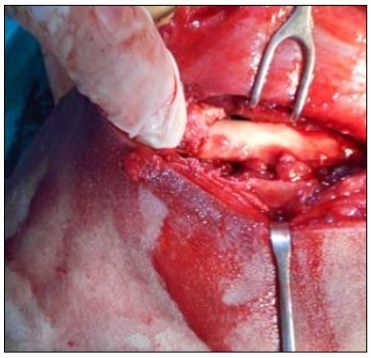

**Fig 3:** Fracture fragment was reduced to their normal anatomical position

**Fig 4:** The VCP was cutting to required size with a pin cutter.

**Fig 5:** Proximal-most hole was being drilled using a low speed high torque electric drill.

Bone plating was accomplished by insertion of two to three screws in both proximal and distal fracture fragments (Fig. 6). Following fracture repair, the incision on the tensor fascia lata was closed in a simple continuous pattern using 2-0 chromic catgut. The skin incision was closed in a row of cruciate mattress suture using 2-0 polypropylene and the suture line was covered with a thin layer of sterile gauze bandage dipped in 5% povidone iodine solution, over this a modified Robert johns bandage was applied.

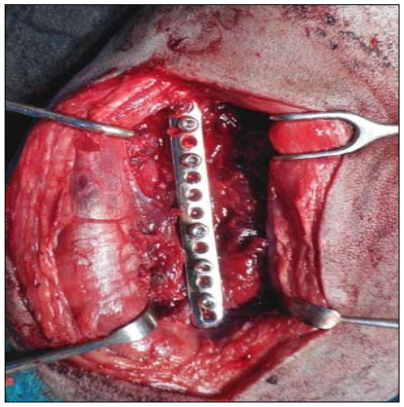

**Fig 6:** Bone plating was accomplished by insertion of two to three screws in both proximal and distal fracture fragments.

The dressing was changed every alternate day until the sutures were removed on the 10th post-operative day. Ceftriaxone sodium was administered at the rate of 20 mg/kg body weight as intramuscular injection once a day for 7 days post-operatively. Meloxicam was administered once a day at the rate of 0.3 mg/kg by intramuscular injection for 3 days. Plain anterio-posterior and lateral radiographs of the operated femur were obtained immediately after surgery and on the 15th, 30th and 45th post-operative days and whenever needed on later dates to assess the progress of bone healing (Fig. 7).

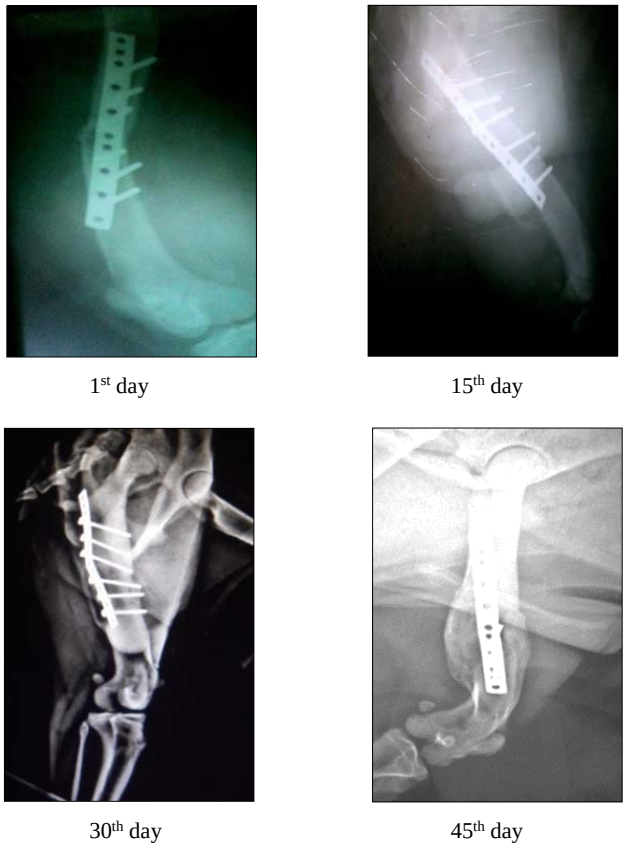


**Fig 7:** Progressive radiographic changes on the 1st, 15th, 30th and 45th days

## 3. Results and Discussion

In the present study, the use of Veterinary Cuttable Plates (2.0mm and 2.7mm size) was provided good fracture stability. The length of the plate was determined by the length of the bone as measured on plain radiographs. Required length of the veterinary cuttable plate was cut with a pin cutter. 2.7 mm VCPs with eleven to sixteen holes were used for five dogs in the present study based on the requirement. In one dog, 2.0 mm VCP with 10 holes was employed for fracture fixation.

In present study the 2.7 mm non-self tapping cortical screws varying from 22 mm to 30 mm in length were used in five dogs and 2.0 mm cortical screws varying from 14 mm and 16 mm in length were used in one dog. The length of screws was determined by measuring the thickness of the bone from the anterio-posterior radiographs obtained pre-operatively. Screw positioning without involving growth plates and their application without tapping gave good result in all the cases. Application of Robert-Jones bandage was found to be satisfactory for immobilization of the limb. The use of Ceftriaxone sodium effectively prevented post-operative infection. None of the dogs developed post-operative swelling.

All the six dogs in the present study showed partial weight bearing from the 1st post-operative day. One dog achieved complete weight bearing by the 7th post-operative day, three dogs by 15th post-operative day and two dogs by 30th post-operative day. The mean lameness scores in the animals were found to be 3 ± 0.25, 2.16 ± 0.30, 1.33 ± 0.21, 1 ± 0 and 1 ± 0 respectively by the end of the 1st day, 7th day, 15th day, 30th day and 45th day of surgery. Fracture fixation using 2.7 mm and 2.0 mm VCPs with cortical screws resulted remarkable improvement with normal limb function. Good implant stability throughout the treatment period without any complications could be achieved in four dogs. In one dog slight bending of pate was observed at the fracture site by 15th post-operative day (Fig. 8) and in the other dog, distal screw loosening was observed due to jumping from height by 30th post-operative day. However, there was no loss of stability in fractured fragments. In none of the cases, implant removal was taken up since the owners were reluctant for the second surgery.

**Fig 8:** Bending of plate was observed by the 15th post-operative day**.**

Based on the observations of the present study it was revealed that the main cause of fractures was found to be trauma from road accidents in 4 dogs (66.66%) followed by falls from height in 2 dogs (33.33%). These findings are in accordance with Authors [10, 12, 1, 9], the authors stated that automobile accidents and jumping from height were major exciting causes of fractures in dogs. The patient preparation and anaesthetic protocol followed for the surgery was found satisfactory in all the six animals for management of fracture in the present study. Pardeshi and Ranganath [11] also adapted similar anaesthetic protocol.

Studies were conducted to test the design and biomechanical

properties of VCPs by Fruchter and Holmberg [7], Crigel and Balligand [4], Hammel *et al.* [8], Zahn *et al.*, [18] Rose *et al.*, [13] and Bichot *et al.*, [2] was helpful in this study. These authors were recommended that VCPs were suitable for treatment of long bone fractures in young dogs. 2.0 mm and 2.7 mm non-self tapping cortical screws used in present study provided good stability to the fracture fixation. This was also corroborated by reports of Dejardin and Cabassu [5].

None of the dogs showed any post-operative complications like pre-mature closure of the growth plate or other deformities. The same findings were also reported by Cabassu [3], Dejardin and Cabassu [5]. Robert-Jones bandage was applied for ten days after surgery for all the dogs in the present study as recommended by Tobias [16] and Denny and Butterworth [6].

The lameness grade was carried out in accordance with the protocol developed by Vasseur *et al.* [17]. In the present study, all the six cases showed grade-I lameness an average of 30-45 days post-operatively.

In the present study, the VCPs with cortical screws showed remarkable improvement with normal limb function and maintaining good implant stability throughout the treatment period without any complications in four out of six dogs. Similar findings were observed by Dejardin and Cabassu [5].

Out of six dogs, plate bending at the fracture site was encountered by 15$^{th}$ post-operative day in one dog and distal screw loosening was observed by the 30$^{th}$ day in another dog. Sarrau *et al.* [15] also observed plate bending in puppies which were treated with VCP.

## 4. Conclusion

Based on the present study, it was concluded that Veterinary Cuttable Plates were found suitable for the treatment of femoral diaphyseal fractures in young dogs with thin cortical bones and active growth plates. The implant used in this technique was economical, making it amenable to use in veterinary practice.

## 5. Acknowledgement

We would like to express our sincere gratitude to Dr. V. Gireesh Kumar**,** Professor, Department of Surgery and Radiology, PVNRTVU, Rajendranagar, Hyderabad, for his continuous support and valuable suggestions during the research study period.

## 6. References

1. Aithal HP, Singh GR, Bi7sht GS. Fractures in dogs: a survey of 402 cases. Indian Journal of Veterinary Surgery. 1999; 20:15.
2. Bichot S, Gibson TW, Moens NM, Runciman RJ, Allen Monteith GM. Effect of the length of the superficial plate bending stiffness, bending, strength and strain distribution in stacked 2.0-2.7 mm Veterinary Cuttable Plate construct. An in vitro study. Veterinary and Comparative Orthopedics and Traumatology. 2011; 24(6):426- 434.
3. Cabassu J. Elastic plate osteosynthesis of femoral shaft fractures in young dogs. Veterinary and Comparative Orthopaedics and Traumatology. 2001; 14:40-45.
4. Crigel MH, Balligand M. Critical size defects model on the femur in rabbits. Veterinary and Comparative Orthopedics and Traumatology. 2002; 3:158-163.
5. Dejardin LM, Cabassu JP. Femoral fractures in young dogs. AO Dialogue. 2005; 18:39-43.
6. Denny HR, Butterworth SJ. A Guide to Canine and Feline Orthopaedic Surger. Fourth Edition, 2000, 512-553.
7. Fructer AM, Holmberg DL. Mechanical analysis of the veterinary cuttable plate. Comparative Orthopedics and Traumatology. 1991; 4:10-13.
8. Hammel SP, Elizabeth PG, Novo RE, Bourgeault CA, Wallace LJ. Fatigue analysis of plates used for fracture stabilization in small dogs and cats. Veterinary Surgery. 2006; 35:573-578.
9. Johnson AL, Eurel JA, CLosonsky JM, Egger EL. Biomechanics and biology of fracture healing with external skeletal fixation. Compendium on Continuing Education for the Practicing Veterinarian. 1998; 20:487-500.
10. Maala CP, Celo EM. A study on the anatomical locations, incidence and causes of fractures in dogs. Philippine journal of American Veterinary Medical Association. 1975; 14:137.
11. Pardeshi GD, Ranganath L. Comparison of Type 1a and Type1b external skeletal fixation for tibial fracture repair in dogs. Indian Journal of Veterinary Surgery. 2008; 29(2):93-95.
12. Phillips IR. A survey of bone fractures in the dog and cat. Journal of Small Animal Practice. 1979; 20:661-674.
13. Rose BW, Pluhar GE, Novo RE, Lunos S. Biomechanical analysis of stacked plating techniques to stabilize distal radial fractures in small dogs. Veterinary Surgery. 2009; 8:954-960.
14. Sarrau S Meig, Autefage A. Treatment of femoral and tibial fractures in puppies by elastic plate osteosynthesis. Veterinary and Comparative Orthopedics and Traumatology. 2007; 20(1):51-58.
15. Theoret MC, Moens MM. The use of Veterinary Cuttable Plates for carpal and tarsal arthrodesis in small dogs and cats. Canadian Veterinary Journal. 2007; 48(2):165- 168.
16. Tobias TA. Slings, padded bandages, splinted bandages and casts. Small Animal Orthopedics. Mosby, 1995, 75-159.
17. Vasseur PB, Johnson AL, Buder berg SC, Linwin JB, Toombs JP, Whitebain JG, Lentz EL. Randomized, controlled trials of the efficacy of carprofen, a non-steroidal anti-inflammatory drug in the treatment of osteoarthritis in dog. Journal of American Veterinary medical Association. 1995; 206:807-811.
18. Zahn K, Frei R, Wunderle D, Linke B, Schwieger K, Guerguiev B, *et al*. Mechanical properties of 18 different A O bone plates and the clamp-rod internal fixation system tested on a gap model construct. Veterinary and Comparative Orthopedics and Traumatology. 2008; 21:185-194.