Journal of Entomology and Zoology Studies

Available online at www.entomoljournal.com

E-ISSN: 2320-7078
P-ISSN: 2349-6800
JEZS 2018; 6(1): 1256-1259

Received: 21-11-2017
Accepted: 22-12-2017

Azhar Ali Faraj An
Department of Parasitology, college of veterinary medicine University of Baghdad- Iraq

Haider Hadi Ghattof
Department of Parasitology, college of veterinary medicine University of Baghdad- Iraq

Correspondence
Azhar Ali Faraj An
Department of Parasitology, college of veterinary medicine University of Baghdad- Iraq

Diagnosis of *Neospora caninum* using ELIZA and study of histopathological changes in dairy goat in Wasit province: Iraq

Azhar Ali Faraj An and Haider Hadi Ghattof

Abstract
The current study designed to detection of *Neospora caninum* antibodies in goat milk in different areas of Wasit-province in Iraq, milk samples were collected from 74 dairy goats in different regions through November 2014- April 2015. The results recorded total infection rate of parasite 18.91% (14/74) with significant differences by using Indirect Enzyme Linked Immuno Sorbent Assay (ELISA). The histopathological examination revealed significant lesions in different internal organs; heart, lung, liver, brain, thymus for aborted goat fetus (in 90 day gestation) and placentom of naturally infected dam. The main lesions were described in these tissues; represented chronic infection reaction of MNCs (mainly monocytes and macrophages), perivascular cuffing around congested blood vessels, and atrophic necrosis of infected tissues. Most tissue sections revealed presence of cystic-like appearance of parasitic infection with thick wall and contained different stage of life cycle with cellular debris or diffusely present. The present study was considered as the first report about detection neosporosis in dairy goats in Iraq.

Keywords: *Neospora caninum*, Abortion, Milk, Goat, Histopathology, Iraq

Introduction
Neosporosis, caused by the obligate intracellular parasite protozoan *N. caninum*, is an important causative agent of repeated abortions in ruminants, including cattle, sheep, goats, horse, and deer (Dubey, 2003) [4] and neurological alterations in dogs (Barber and Trees1998) [1]. *N. caninum* may cause disease in animals infected during pregnancy (Barr *et al*.,1990) [2]. At birth may have neurological signs, be underweight, lacking ability to rise, or have no clinical signs (Dubey and Schares, 2011) [5]. *N. caninum* infection may reduced milk production and shortened production life due to early culling (Thurmond and Hietala, 1997) [19]. Dogs and coyotes are the final hosts. Cattle and a wide range of other warm blooded animals can act as intermediate hosts. There are three infection stages of the parasite: Tachyzoites and bradyzoites occur in tissues of infected hosts (intermediate and definitive hosts), whereas oocysts that are excreted in the faeces of the definitive host (Heuer *et al*.,2004, Moore, 2005) [10, 15]. The goal of current study was to detect *N. caninum* antibodies in skimmed milk samples and study the histopathological changes in placenta and some organs of aborted fetuses of goats in wasit province.

Materials and Methods
Milk collection
Milk samples were collected randomly from 74dairy goats, during November 2014- April 2015 from different area (Karrada, Annomaniyah, Al-Kairat, Saila) in Wasite province, Iraq. the samples were centrifuged at 1000rpm for 10 min and skimmed milk (lactoserum) was collected and stored at -20 ℃ untile analysis using a commercial ELISA Kit(IDvet) according to the manufacturers instruction.

Histopathological Examination
The tissue specimens; brain, liver, lung, heart were collected from one aborted one-day-old goat fetuses also the placenta of infected dam (previously numbered goats in therapeutic numbering system) and cut into pieces (1 cm^3) and fixed in 10% buffered formalin solution, then submitted to serological laboratory to the department of central veterinary laboratories. The formalin fixed tissue specimens, paraffin blocks were made, and 5-6 microns thick sections were serially cut with a microtome and stained with hematoxylin and eosin (H&E) (Luna, 1968) [12].

Statistical analysis

Data was statistically analyzed by Chi-square tests for significance using SPSS 15 version.

Results and Discussion

This study showed that the rate of infection (18.91 %) in skimmed milk with significant differences on ($P \leq 0.05$). The highest rates of infection was recorded in the Annomaniyah was (26.66%), While in Al-Kairat without infections. (Table 1).

Table 1: Total infection rate of N. caninum in the skimmed milk by using ELISA in different areas of Wasit province.

Location	Total number	Positive	(%)
Karrada	14	3	21.42
Annomaniyah	30	8	26.66
Al-Kairat	16	0	0.00
Saila	14	3	21.42
Total	74	14	18.91

($P \leq 0.05$)

The samples of bulk milk can be easily collected and tested for antibodies of infectious diseases in dairy herds by ELISA method (Pritchard, 2001) [16]. Testing of bulk milk is a useful way for a rapid finding of the presence of *N. caninum* in a large area.

Hurkova *et al.* in (2005) [11] reported (1.01%) prevalence of *N. caninum* in cattle in the Czech Republic. Also with 3.9% prevalence in aborting cows (Vaclavek *et al.*, 2003) [20].

Schares *et al.* (2003) [7] reported 7.9% prevalence in 3260 examined herds using bulk milk ELISA method, when a maximum of 50 cows contributed to bulk milk samples in Germany.

The present results demonstrated generally high prevalence of *N. caninum* infected in skim milk of caprine in Iraq that corresponds with results that carried out in Thailand, 220 herds were analyzed by bulk milk ELISA and 46% herds were found positive (Chanlun *et al.*, 2002) [3].

Slapeta *et al.* in (2002) [18] mentioned that limited contacts of cattle and dogs. Moreover, water source, good nutrition, good management system and therapeutic system can be attributed to the differences in seroprevalence of caprine neosporosis between the regions.

Histopathological changes in brain

Necropsy was carried out for one aborted fetus (a one day old) of positive doe (Examined by ELISA for detection of *N. caninum*).

The histopathological lesions in brain showed many neurons were represents severe neuronal vacuolation (degeneration) with ischemic of neurons (Fig.1A, B).

The present study, we used foetal histopathology combined with ELISA to detect the presence of *Neospora* infection in aborted foetuses from caprine.

According to reviews, *N. caninum* is very similar in appearance to *T. gondii* and therefore needs to be differentiated in tissues by immunoperoxidase using specific anti sera (Dubey and Lindsay, 1996) [8, 9].

A preparatory way to distinguish *N. caninum* from *T. gondii* is the thickness of the tissue cyst wall. The *T. gondii* tissue cysts encysted by a very thin wall, ranging (less than 0.5 µm) in thick (Dubey *et al.*, 1996) [8, 9], which is negative to PAS stain, in contrast to the bradyzoites, which are positive; Whereas *N. caninum* cyst has thicker wall (larger or equal than 1 µm), bradyzoites are PAS-positive and the cyst wall stains variably with PAS (Dubey *et al.*, 2002) [7]. The current study, detected 1.0 µm thick cyst wall for descriptions of *N. caninum*, tissue cyst so is thicker than that described for *T. gondii* cyst and the findings of several tissue cysts in internal organs and had no tachyzoites associated with the perivascular lymphoplasmacytic cell response and focal gliosis which suggested that the infection was chronic in the goat kid.

Histopathological changes in liver

The characterized microscopic finding in the liver of aborted fetus showed severe destruction in liver parenchyma accompanied with solitary presence of tachyzoite (that appear as banana shape) with severe necrosis of remaining hepatocyte (Fig. 2).

In liver**,** two types of lesion could be encountered in the liver: periportal hepatitis and multifocal hepatocellular necrosis. Both types of lesions may occur together. Periportal hepatitis, characterized by infiltration of mononuclear cells in portal.

Areas, is the most common lesion. Multifocal hepatocellular necrosis, with associated intra-sinusoidal deposits of fibrin (Wouda *et al.*, 1998b) [21]. Previous lesions are similar to present results.

Histopathological changes in lung

This section was characterized by moderate to severe necrosis in bronchial mucosa together with cellular infiltration associated with evidence of longitudinal cyst containing aggregation bradyzoites (Fig. 3A). Lung section in the wall of bronchus showed capillary dilation and congestion together, this is an evidence of presence of *N. caninum* pseudocyst closely packed bradyzoite within fibrosis (Fig. 3B).

In lung, the microscopical lesions characterize by increase thickening of interalveolar septa, congestion, alveolar edema, irregular and longitudinal tissue cyst containing numerous of bradyzoites, severe necrosis and cellular infiltration, this findings of the present study were agreement with results that described in bovine histopathological lesions by (Dubey, 1992) [6].

Histopathological changes in thymus

The hallmarking feature of thymic fetal tissue characterized by lymphoid depletion mainly in medullar region together with blood vessels congestion (Fig. 4).

In thymus, the lesions of aborted goat fetuses such as lymphoid depletion and blood vessels congestion are first reported in this present study.

Histopathological changes in heart

The characterize microscopic lesions in heart showed Necrosis of cardiomyocytes (infilteration of myocardial) accompanied with number of *N. caninum* tachyzoites pseudocyst seen within necrotic fiber accompanied with MNCs infiltration in the epicardium (Fig. 5).

In heart, Focal or diffuse myocarditis is a frequent finding in infected fetuses (Barr *et al.*, 1990) [2], with lesions characterized by varying numbers of mixed mononuclear cell infiltrates in the epicardium, myocardium and endocardium also focal macrovesicular steatosis.

Rarely, aggregations of tachyzoites can be found within cardiac muscle cells (Wouda *et al.*, 1998b) [21]. That was compatible with present findings.

Histopathological changes in placenta

There was thickening of chorionic plate and rich collagen accompanied with multiple necrotic foci containing cellular debris and number of *N. caninum* bradyzoites like structure

enclosed with thickened chorionic plate (Fig. 6A). In other section there was mineralization of chorionic plate within cellular aggregation of leukocytes and necrotic foci (Fig. 6).

In placentom, the main lesions have been thickness of chorionic plate, number of *N. caninum* bradyzoites like structure, necrotic villi and giant cell formation and mineralization of chorionic plate. The present results are similar to results both (Maley *et al.*, 2003; Macaldowie *et al.*, 2004) [14, 13].

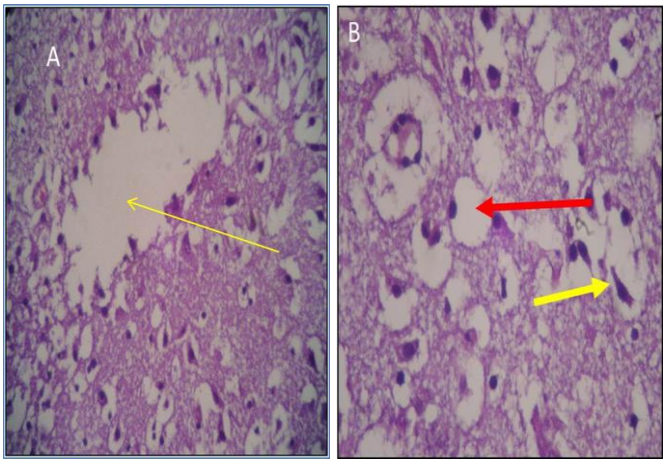

Fig 1: Histopathological sections in brain of aborted fetus. (H & E, X40) **A**: Large empty space cavity in cerebral tissue of aborted fetus represent sever necrotic area with remnant of pykinotic nuclei; sever vacuolation of neuron in **B:** with large intracellular vacuoles and necrotic one also see.

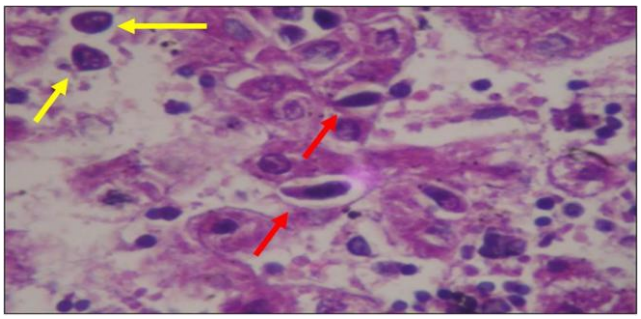

Fig 2: Histopathological sections in liver of aborted aborted fetus. (H & E, X40)

- Presence of tachyzoite in necrotic parenchyma (red arrow).
- *N. caninum* pseudocyst containing basophilic bradyzoite (yellow arrow).

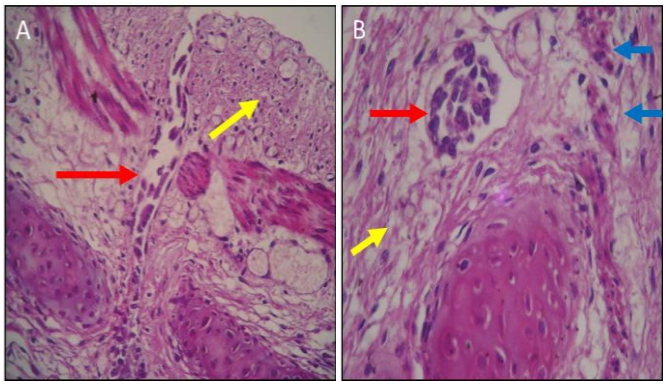

Fig 3: Histopathological sections in lung of aborted fetus. (H & E, X40) **A:** Longitudinal cyst containing aggregation bradyzoites in the bronchial wall (red arrow), intensive necrosis of bronchial epithelial (yellow arrow). **B:** *N.caninum* tissue pseudocyst developed bradyzoite (red arrow), collagen proliferation in the bronchial wall (yellow arrow) capillary congestion & dilation (blue arrow).

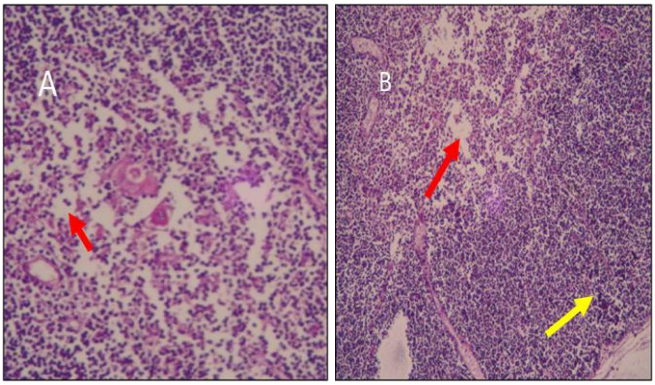

Fig 4: Histopathological sections in thymus of aborted fetus. (H&E, X10) **A:** Lymphoid depletion in medulla tissue (red arrow). **B:** Medulla (red arrow), cortex (yellow arrow).

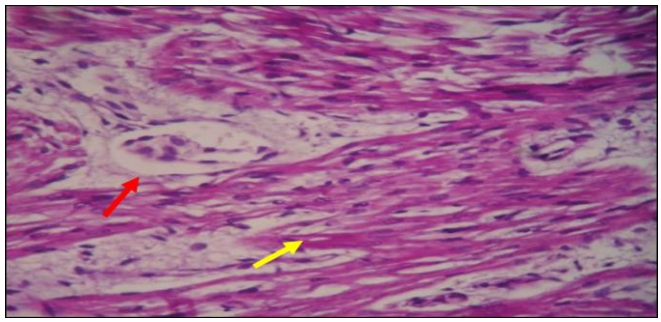

Fig 5: Histopathological sections in heart of aborted fetus. (H&E, ×40)

- *N. caninum* pseudocyst (red arrow), necrotic fibers stained deeply eosin (yellow arrow).

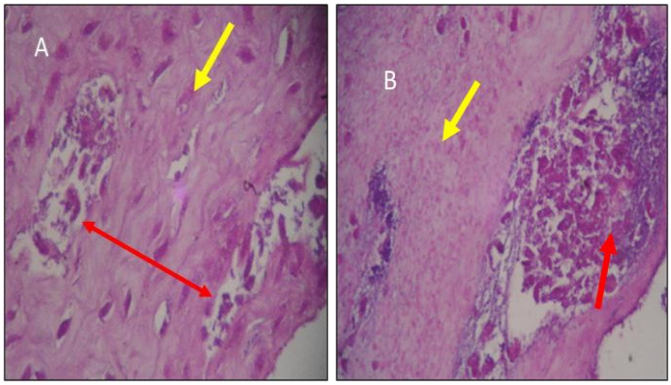

Fig 6: Histopathological sections in placentom of the infected dam. **A:** Multiple necrosis lesion containing tissue debris with *N.caninum* bradyzoite like structures (red arrow), thickened chorionic plate (yellow arrow). **B:** mineralization within necrotic foci (red arrow), thickened chorionic plate (yellow arrow) (H&E, X40).

References

1. Barber JS, Trees AJ. Naturally occurring vertical transmission of *Neospora caninum* in dogs. Int J Parasitol. 1998; 28:57-64
2. Barr BC, Anderson ML, Blanchard PC, Daft BM, Kinde H, Conrad PA. Bovine fetal encephalitis and myocarditis associated with protozoal infections. Vet Pathol. 1990; 27(5):354-361.
3. Chanlun A, Naslund K, Aiumlamai S, Bjorkman C. Use of bulk milk for detection of *Neospora caninum* infection in dairy herds in Thailand. Vet. Parasitol. 2002; 110:35-44.
4. Dubey JP. Neosporosis in cattle. J Parasitol. 2003, 89.
5. Dubey JP, Schares G. Neosporosis in animals-the last five years. Vet Parasitol. 2011; 180(1-2):90-108.

6. Dubey JP. A review of *Neospora caninum* and *Neospora*-like infections in animals. J. Protozool. Res. 1992; 2:40-52.
7. Dubey JP, Hill DE, Lindsay DS, Jenkins MC, Uggla A, Speer CA. *Neospora caninum* and *Hammondia heydorni* are separate species/organisms. Trends Parasitol. 2002; 18:66-69
8. Dubey JP, Lindsay DS, Anderson ML, Davis SW, Shen SK. Induced transplacental transmission of *Neospora caninum* in cattle. J of the American Vet. Med. Assoc. 1996; 201:709-713.
9. Dubey JP, Lindsay DS. A review of *Neospora caninum* and neosporosis. Vet. Parasitol. 1996; 67:1-59.
10. Heuer C, Nicholson C, Russell D, Weston J. Intervet symposium: bovine neosporosis. Vet Parasitol. 2004; 125:137-146.
11. Hurkova L, Halova D, Modry D. The prevalence of *Neospora caninum* antibodies in bulk milk of dairy herds in the Czech Republic: a case report. Vet. Med. 2005; 50(12):549-552.
12. Luna, LG. Manual of Histologic Staining Method of the Armed Force Institute of Pathology, 3rd ed., Mc Graw - Hill Book Co. New York, USA, 1968, 36.
13. Macaldowie C, Maley SW, Wright S, Bartley P, Esteban-Redondo I, Buxton D *et al*. Placental pathology associated with fetal death in cattle inoculated with *Neospora caninum* by two different routes in early pregnancy. J Comp. Pathol. 2004; 131:142-156.
14. Maley SW, Buxton D, Rae AG, Wright SE, Schock A, Bartley PM *et al*. The pathogenesis of neosporosis in pregnant cattle: inoculation at mid-gestation. J. Comp. Pathol. 2003; 129:186-195.
15. Moore DP. Neosporosis in South America. Vet Parasitol. 2005; 127(2):87-97.
16. Pritchard G. Milk antibody testing in cattle. In: Praktice. 2001; 23:542-550.
17. Schares G, Barwald A, Staubach C, Ziller M, Kloss D, Wurm R *et al*. Regional distribution of bovine *Neospora caninum* infection in the German state of Rhineland-Palatine modelled by logistic regression. Int.J. for Parasitol. 2003; 33:1631-1640
18. Slapeta JR, Koudela B, Votypka J, Modry D, Horejs R, Lukes J. Coprodiagnosis of *Hammondia heydorni* in dogs by PCR based amplification of ITS 1 rRNA: Differentiation from morphologically indistinguishable oocysts of *Neospora caninum*. Vet. J. 2002; 163:147-154.
19. Thurmond MC, Hietala SK. Effect of Neospora caninum infection on milk production in first-lactation dairy cows. J Am Vet Med Assoc. 1997; 210(5):672-674
20. Vaclavek P, Koudela B, Modry D, Sedlak K. Seroprevalence of *Neospora caninum* in aborting dairy cattle in the Czech Republic. Vet. Parasitol. 2003; 115:239-245.
21. Wouda W, Brinkhof J, Maanen CV, Gee AL, Moen AR. Serodiagnosis of neosporosis in individual cows and dairy herds: Acomparative study of three enzyme-linked immunosorbent assays. Clin. and Diagn. Lab. Immuno. 1998b; 5:711-716.