



E-ISSN: 2320-7078

P-ISSN: 2349-6800

JEZS 2018; 6(1): 1436-1441

© 2018 JEZS

Received: 18-11-2017

Accepted: 19-12-2017

**Hadeer AA**
 Department of pathology,  
College of Veterinary medicine,  
University of Baghdad, Iraq
**Bushra I AL-Kaisie**
 Department of pathology,  
College of Veterinary medicine,  
University of Baghdad, Iraq

## Pathological and biochemical study on liver of male mice intoxicated with thioacetamide

**Hadeer AA and Bushra I AL-Kaisie**

### Abstract

The present study is aimed to study the hepatotoxic effect of thioacetamide on male mice. This study was carried out at college of veterinary medicine, Baghdad from November 2016 to April 2017. One hundred twenty albino male mice were divided into two groups. First group was control. The second group divided into three subgroups. The first subgroup received thioacetamide intraperitoneally 100 mg/kg for two months. The second subgroup received thioacetamide intraperitoneally 100 mg/kg for four months. The third subgroup received thioacetamide intraperitoneally 100 mg/kg for six months. All animals were euthanized and blood samples were taken for biochemical analysis and liver sample obtained and fixed in 10% normal buffer formalin for routine histopathological examination. Results showed significant increase in Alkaline phosphatase, Alanine Aminotransferase, Aspartate Aminotransferase and Bilirubin while showed significant decrease in Glutathione and peroxynitrate radicals concentration. Histopathological changes characterized by centrilobular necrosis, fibrosis, liver cirrhosis and hyperplasia of bile ducts.

**Keywords:** thioacetamide, biochemical, pathological, glutathione

### 1. Introduction

The TAA is a thioamide compound that usually preserved and stored at room temperature<sup>[1, 2]</sup>. It is soluble in water and ethanol, miscible with benzene, petroleum and sparingly soluble in ether. It can be hydrolyzed by acids or bases and it reacts with salts of heavy metals. The substance decomposes by burning producing toxic fumes such as nitrogen oxides and sulfur oxides<sup>[3]</sup> and it is a chemical reagent was found potent hepatotoxin, hepatocarcinogen in experiment animals models<sup>[4, 5, 6]</sup>. The influence of TAA is not limited to liver because it can cause structural and functional changes in spleen, lung, brain, stomach, kidney and intestine<sup>[7]</sup><sup>[8, 9]</sup>. It has been used as a fungicide, chemical reagent, organic solvent, accelerator in the vulcanization of rubber, textile, dye, paper and as a stabilizer of motor oil<sup>[10, 11]</sup>. Currently, TAA is used only as a replacement for hydrogen sulfide in qualitative analyses<sup>[1, 2]</sup> and as a reactant in producing metal salt nanoparticles<sup>[12, 13]</sup>. Cirrhosis is defined as damage of liver cells and gradual replacement with scar tissue that impair blood flow through the liver, causing hepatocytes death and loss of normal function<sup>[14]</sup>. Cirrhosis is advanced stage of fibrosis and it is a critical stage of chronic hepatitis that can produce liver failure. It may be due to viral infection, toxic agents or alcohol<sup>[15]</sup>. Oxidative stress has been accused in the genesis of acute and chronic liver damage in many conditions such as toxin exposures, bile duct obstruction, excess alcohol intake, liver ischemia and viral infection<sup>[16]</sup>. Overproduction of ROS and nitrogen species, together cause significant decrease of antioxidant production in these pathological conditions<sup>[17]</sup>. Oxidative stress produced by free radicals has been implicated in the pathogenesis of acute liver injury<sup>[18]</sup>. The aims of the present investigation to study the hepatotoxicity of TAA (fibrosis and cirrhosis) by assays of hepatic enzymes, glutathione, total bilirubin concentration in serum and Pathological changes in hepatic tissues.

### 2. Materials and Methods

#### 2.1 Chemicals and reagents

Thioacetamide obtained from Qualikems – India. It was administered at a dose of 100 mg/kg body weight intraperitoneally according to Lieber<sup>[19]</sup>.

#### 2.2 Animals and diets

120 male albino mice with three months age and body weight ranged between 30 and 35 g

**Correspondence****Hadeer AA**
 Department of pathology,  
College of Veterinary medicine,  
University of Baghdad, Iraq

were used to perform the present study. Animals were housed in plastic cages of 60x10x10 cm<sup>3</sup> dimensions. Stander rodent diet (commercial feed pellets) and drinking water were given. Housing condition were maintained at 22± 25 °C, with controlled lightening using automatic electrical timer providing daily light of twelve hour (7.00 Am to 19.00 Pm) and twelve hour night cycle. The litters of the cages were changed every seven days.

### 2.3 Preparation of doses and treatment

Thioacetamide was freshly dissolved in distilled water and administrated to mice at a dose of 100 mg/kg B.W. injected intraperitoneally, monthly.

### 2.4 Experimental design

Animals were randomly divided into 2 groups of mice, namely: control group of 30 mice received normal diet only, treated group of 90 mice were divided into 3 subgroups as follow:

1<sup>st</sup> group (G1) 30 mice received TAA dose (100 mg/kg B.W) monthly for 2 months (2 injections) I/P.

2<sup>nd</sup> group (G2) 30 mice received TAA dose (100 mg/kg B.W) monthly for 4 months (4 injections) I/P.

3<sup>rd</sup> group (G3) 30 mice receive TAA dose (100 mg/kg B.W) monthly for 6 months (6 injections) I/P

At the end of experiment all animals sacrificed were after 2, 4, 6 months subsequent biochemical and pathological studies.

### 2.5 Determination of oxidative enzymes

#### 2.5.1 Determination of serum glutathione (GSH) concentration (µm/I)

Detection of serum glutathione is depended on the action of sulfhydryl groups 5, 5 dithiobis (2- nitrobenzoic acid)(DTNB) which is adisulfide chromogen that is readily reduced by sulfhydryl group of (GSH) to an intensive yellowish compound [20].

#### 2.5.2 Determination of serum peroxynitrate radical concentration (m/i)

Peroxynitrate ONOO- from nitrophenol was absorbed at 412 nm. The amount of nitrophenol that was formed in the serum reflects the level of peroxynitrite in the serum by a method described by Vanuffelen [21].

### 2.6 Determination of liver enzymes

#### 2.6.1 Serum transamination

Colorimetric method for detection of ALT and AST in serum was done by using of AST and ALT kits [22].

#### 2.6.2 Alkaline phosphatase

Serum ALP concentration was enzymatically measured using standard assay (ALP-Kit) [23].

#### 2.6.3 Total bilirubin

The total bilirubin was evaluated in the mouse serum using a commercial kit produced by Giesse Company [24].

### 2.7 Histopathological study

All animals were sacrificed by inhalation of chloroform and postmortem was done for all animals. Liver and kidney, macroscopically examined to record any abnormal changes. Specimens were collected from these organs, then kept in 10% formalin fixative, then processed routine procedure by using the histokinette [25].

### 2.8 Statistical analysis

Data were analyzed by using complete randomized design (C. R. D.) in factorial experimental by using two ways analyses of variance (ANOVA) to compare between means, and Duncan multiple range test [26] was applied. Data were analyzed using statistical analysis system [27].

## 3. Results

### 3.1 Biochemical analysis

G3 showed significant increased P<0.05 in ALP serum concentration compared with G2 and G1, respectively: G3 (273.25 ± 1.50), G2 (200 ± 0.96) and G1 (164 ± 0.63). In ALT serum concentration, G1 (100.23 ± 1.40), G2 (170 ± 0.42) and G3 (233.94 ± 1.70), showed significant P<0.05 increased compared with control while in ALT G3 serum concentration noted significant P<0.05 increase compared with G2 and G1. AST serum concentration G1 (350.92 ± 1.50), G2 (490.27 ± 0.23) and G3 (604.57 ± 1.33) observed significant P<0.05 increase compared with control while in AST G3 serum concentration noted significant increase compering with G2 and G1. In Bilirubin serum concentration G1 (39.7 ± 0.60), G2 (44.52 ± 1.30) and G3 (53.29 ± 0.040) showed significant P<0.05 increase compering with control while Bilirubin G3 serum concentration noted significant P<0.05 increase compared with G2 and G1.

**Table 1:** At 2, 4 and 6 months showed significant increased P<0.05 in serum concentration of ALP, ALT, AST and Bilirubin G1, G2 and G3 compared to control group

Groups	ALP u/L	ALT u/L	AST u/L	Bilirubin Mg/dl
Control	50.32 ± 1.20	50.75 ± 1.25	189.52 ± 1.94	20 ± 0.83
G 1 2 months	164 ± 0.63*	100.23 ± 1.40*	350.92 ± 1.50*	39.7 ± 0.60*
Control	50.22 ± 0.25	50.33 ± 0.96	189.47 ± 0.88	20 ± 0.85
G 2 4 months	200 ± 0.96**	170 ± 0.42**	490.27 ± 0.23**	44.52 ± 1.30**
Control	50.29 ± 0.14	50.27 ± 0.45	189.54 ± 0.04	20.12 ± 0.15
G 3 6 months	273.25 ± 1.50***	233.94 ± 1.70***	604.57 ± 1.33***	53.29 ± 0.040***

(Mean ± S.E)\*Significant at P<0.05 (Values are expressed as mean ± S.E. (G n=30, Control n=10). The stars denoted that significant differences between administration).

### 3.2 Oxidative enzymes

G3 showed significant P<0.05 decrease in glutathione

concentration compared with G2 and G1 respectively: G3 (3.24 ± 0.84), G2 (5.72 ± 1.30) and G1 (7.23 ± 0.27).

**Table 2:** At 2, 4 and 6 months showed significant decrease  $P < 0.05$  in serum concentration of glutathione G1, G2 and G3 compared with control

Groups	Glutathione ( $\mu\text{M/l}$ )
Control	$10.72 \pm 0.13$
G 1 2 months	$7.23 \pm 0.27^*$
Control	$10.62 \pm 0.52$
G2 4 months	$5.72 \pm 1.30^{**}$
Control	$10.57 \pm 0.17$
G3 6 months	$3.24 \pm 0.84^{***}$

(Mean  $\pm$  S.E)\*Significant at  $P < 0.05$  (Values are expressed as mean  $\pm$  S.E. (G n=30, Control n=10). The stars denoted that significant differences between administration).

G3 showed significant decrease  $P < 0.05$  in peroxy nitrate radicals concentration comparing with G2 and G1 respectively: G3 ( $3.62 \pm 0.73$ ), G2 ( $5.28 \pm 0.05$ ) and G1 ( $7.3 \pm 0.47$ ).

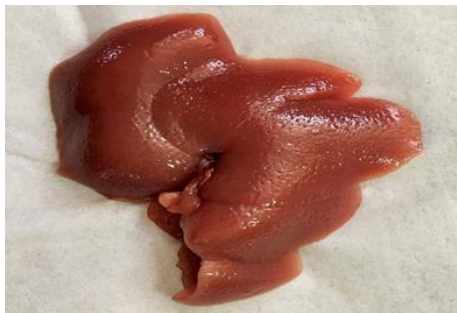**Table 3:** At 2, 4 and 6 months showed significant decrease  $P < 0.05$  in serum concentration of peroxy nitrate radicals G1, G2 and G3 compared with control.

Groups	Peroxy nitrate radical concentration (m/l)
Control	$10.22 \pm 0.03$
G 1 2 Months	$7.3 \pm 0.47^*$
Control	$10.22 \pm 0.03$
G2 4 months	$5.28 \pm 0.05^{**}$
Control	$10.27 \pm 0.07$
G 3 6 months	$3.62 \pm 0.73^{***}$

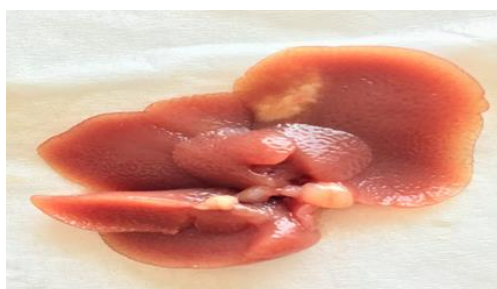(Mean  $\pm$  S.E)\*Significant at  $P < 0.05$  (Values are expressed as mean  $\pm$  S.E. (G n=30, control n=10). The stars denoted that significant differences between administration).

### 3.3 Gross pathology finding

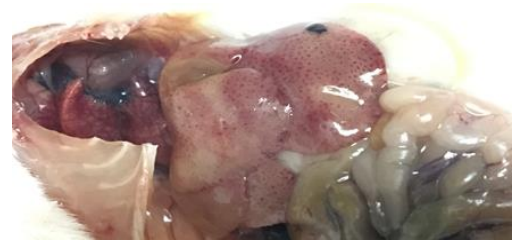Enlargement in the size of liver and appear pitted after two months of administration (fig. 1). After fourth months of administration the liver appear enlarged and pale in color and pitted and appearance of white patch on the surface of liver (fig. 2). The liver after six months of administration appear pale with white patches on the surface (fig. 3)



**Fig 1:** Liver of mice received thioacetamide (100 mg/kg) for two months administration show enlargement of liver



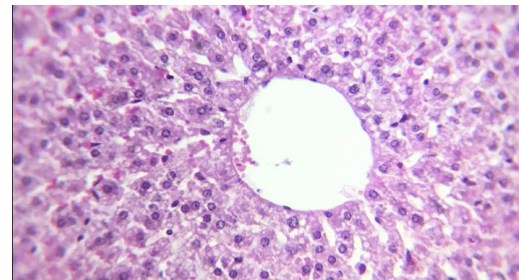
**Fig 2:** Liver of mice received thioacetamide (100 mg/kg) for four months administration show enlargement with white patch on the surface of live



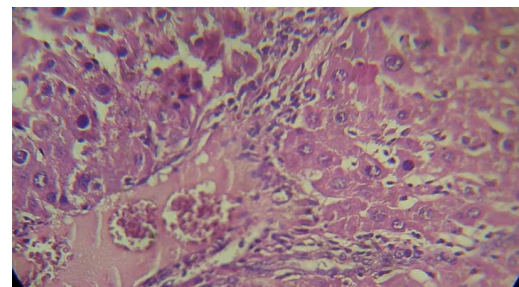
**Fig 3:** Liver of mice received thioacetamide (100 mg/kg) for six months administration show white patches on the surface

### 3.4 Histopathological finding

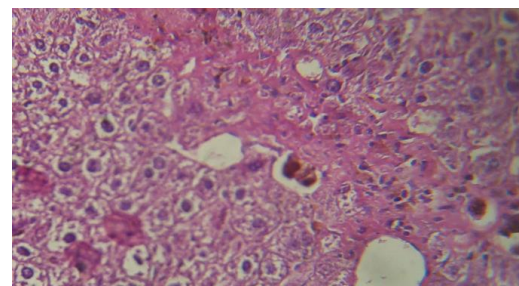
Liver section of normal mice showed normal cellular architecture with distinct hepatic cells, sinusoidal space and central vein (fig. 4). The liver section from the mice of (G1) group showed disarrangement of hepatic cords with congestion, acute cellular swelling, dilated sinusoids with infiltrations of inflammatory cells and extension of fibrin strands (fig. 5). The section from mice of (G2) group showed fibrous tissue extend within the hepatic parenchyma, necrotic hepatocytes and hemosiderin pigment deposition (fig. 6). At 4 months administration also showed hyperplasia in bile ducts and inflammatory cells infiltrations (figure 7). The section from mice at 6 months administration showed pseudoblobules and fibrous tissue encapsulate the nodules and appearance of pseudobile ducts (fig. 8).



**Fig 4:** Normal tissue (H&EX400)

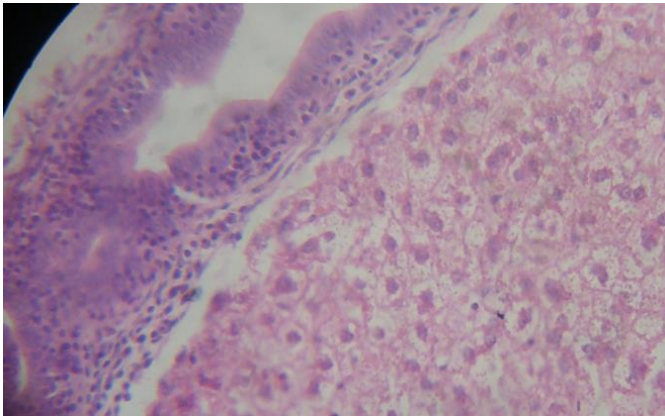


**Fig 5:** Histopathological changes occurred in the liver treated with TAA after two months. Show congestion, acute cellular swelling and lymphocytic cuffing around the blood vessel with extension fibrin strands (H&EX400)

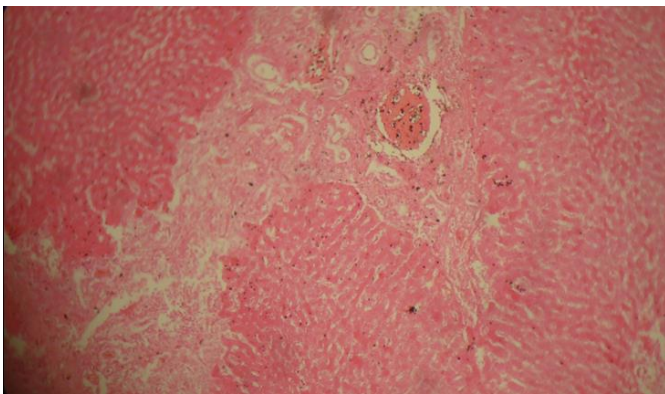


**Fig 6:** Histopathological changes occurred in the liver treated with TAA after four months. Showed fibrous tissues extend within the hepatic parenchyma, necrotic hepatocytes and hemosiderin pigment deposition (H&EX400)





**Fig 7:** Histopathological changes occurred in the liver treated with TAA after four months. Hyperplasia in bile ducts and inflammatory cells infiltrations (H&E400)



**Fig 8:** Histopathological changes occurred in the liver treated with TAA after six months. Showed pseudonodules and fibrous tissue encapsulate the nodules and appearance of pseudobile ducts (H&E400)

## 5. Discussion

Current results were indicated significant decrease ( $p < 0.05$ ) in glutathione and peroxynitrate radicals concentrations which indicated oxidative effect of TAA in sera of administrated albino mice. Antioxidants are expected to protect tissue mostly liver from oxidative stress [28]. As the TAA is responsible for the generation of reactive oxygen species (ROS), which are the main agents in charge of the cellular damage and interfere with the body's normal defense mechanism against these compounds particularly in the liver [29, 30]. The reduced form GSH become readily oxidized to glutathione disulfide (GSSG) and interacting with free radicals result in oxidative stress, which lead to damage macromolecules [31]. The present study agree with finding of [32] as they reported decrease in GSH concentration possibly due to enhancement of ROS formation that trigger depletion in GSH-PX causing defect in the mechanism of antioxidant system to increase the production of ROS that are not sufficiently removed due to impaired antioxidant mechanism which lead to progressive organs failure due to high reactivity of ROS made it easily react with essential molecules (protein, lipid and DNA) [33]. Present results found elevation in serum ALT, AST, ALP and bilirubin. Serum liver biomarker (ALT, AST) are important criteria for evaluation of hepatic damage. The amount of enzymes leak to the blood streams indicate the severity of liver damage [34, 35]. The present study agree with [18] when they recorded an increase in levels of ALT and AST in serum due to the damage in structural integrity of liver and their release to the circulation [36]. The current study agreed with [37] because they observed an increased level of ALT,

AST, ALP possibly due to TAA produced free radicals which affected on the cellular permeability of hepatocytes leading to elevated levels of serum biochemical parameters. Bilirubin is the breakdown product of heme and the liver responsible for clearing bilirubin from the blood. It bind reversibly to albumin and transported to the liver where it conjugated with glucuronic acid and secreted in the bile through intestine [38]. Anbarasu *et al* 2012 [39] reported an increase in bilirubin level after administration of TAA for 21 days. The elevation possibly due to hemorrhage or differences in bilirubin excretion and metabolism and this agree with the present work. Suspected that liver and bile duct degeneration and necrosis caused destruction in bilirubin pathway causing hepatic jaundice (toxic type) because of the toxic effects of TAA on liver represented by prevent the conversion of bilirubin (lipid soluble) by Glucuronic transferase in liver to bilirubin diglucuronide (water soluble) and then accumulate in serum and tissue. Current results indicated that the pathological changes depend on severity of lesion and duration of toxicity. Present study showed macroscopically enlargement of liver after two months administration possibly due to the congestion and the cellular swelling and after four months administration show enlargement of liver with paleness possibly due to congestion and accumulation of fibrous connective tissue with in the liver parenchyma. After six month administration showed large pseudonodules, pale, firm, capsulated by white to pink fibrous tissue and visible on surface (liver cirrhosis) and this agree with [39]. This study microscopically it showed centrilobular necrosis, fatty change in 2 month I/P injection of TAA and these change agree with [40] who reported fatty change and centrilobular necrosis. The mechanism behind this toxicity is associated with its toxic metabolites the *s*-oxide which it reduce the number of hepatocytes as well as rate of oxygen consumption and also decrease the volume of the excreted bile [41]. Administration of TAA for six weeks showed focal inflammatory cells infiltration in the hepatic parenchyma, surrounding the central vein and portal area and proliferation of kuffer cells due to oxidative stress is the key factor for hepatic satellite cells (HSC) activation [42] which in turn involved in the deposition of extracellular matrix, HSC differentiated in to myofibroblast like proliferate and cause fibrosis and cirrhosis [43].

## 6. Conclusions

From the present results obtained in this study, it can be concluded that the toxicity of TAA caused an increase in hepatic enzyme concentrations in the serum (ALP, ALT, AST and Bilirubin) of male mice after 2, 4 and 6 months. Toxicity of TAA caused decrease in GSH and peroxynitrate radicals concentrations in sera of male mice after 2, 4 and 6 months. Toxicity TAA caused histopathological changes characterized by centrilobular necrosis, fibrosis, microabscesses and liver cirrhosis. Therefore, the application of thioacetamide should be carefully to prevent toxicity in the future.

## 7. Acknowledgment

The authors are very grateful to Dr Sarab Ridha for the technical support provided.

## 8. References

1. HSDB. Hazardous Substances Data Bank. National Library of Medicine. <http://toxnet.nlm.nih.gov/cgi-bin/sis/htmlgen>, 2009. Last accessed: 7/14/09
2. IARC. Thioacetamide. In Some Anti-thyroid and Related Substances, Nitrofurans and Industrial Chemicals. IARC

- Monographs on the Evaluation of Carcinogenic Risk of Chemicals to Humans, Lyon, France: International Agency for Research on Cancer. 1974; 7:77-83.
3. NOISH. The national institute for occupational safety and health, thioacetamide, center for disease control and prevention, us department of health and human services. 2014; 62-55-5.
  4. Chen LH, Hsu CY, Weng CF. Involvement of p53 and Bax/Bad triggering apoptosis in thioacetamide-induced hepatic epithelial cells. *World J Gastroenterol.* 2006; 12:5175-5181.
  5. Sarkar MK, Sil PC. Hepatocytes are protected by herb *Phyllanthus niruri* protein isolate against thioacetamide toxicity. *Pathophysiology.* 2007; 14:113-120.
  6. Al-Attar AM, Ali AA, Daklallah AA. Protective effect of olive and juniper leaves extracts on nephrotoxicity induced by thioacetamide in male mice, *Saudi Journal of Biological Sciences.* 2015; 08:013.
  7. Al-Bader A, Mathew TC, Koursheed M, Asfar S, Al-Sayer H, Dashti HM. Thioacetamide toxicity and the spleen: histological and biochemical analysis, *Anat. Histol. Embryol.* 2000; 29:3-8.
  8. Kadir FA, Kassim NM, Abdulla MA, Yehye WA. Effect of oral administration of ethanolic extract of *Vitex negundo* on thioacetamide-induced nephrotoxicity in rats. *BMC Complement. Altern. Med.* 2013; 13:294.
  9. Gao W, Li HY, Wang LX, Hao LJ, Gao JL, Zheng RJ, *et al.* Protective effect of omeprazole on gastric mucosal of cirrhotic portal hypertension rats. *Asian Pac. J Trop. Med.* 2014; 7:402-406.
  10. Chen TM, Subeq YM, Lee RP, Chiou TW, Hsu BG. Single dose intravenous thioacetamide administration as a model of acute liver damage in rats. *Int. J Exp. Pathol.* 2008; 89:223-231.
  11. Lee JW, Shin KD, Lee M, Kim EJ, Han SS. Role of metabolism by flavin-containing monooxygenase in thioacetamide induced immunosuppression. *Toxicol Lett.* 2003; 136:163-172.
  12. Zhang YC, Wang H, Wang B, Yan H, Yoshimura M. Low-temperature hydrothermal synthesis of pure metastable gamma-manganese sulfide (MnS) crystallites. *J Crystal Growth.* 2002; 243(1):214-217.
  13. Liddell CM, Summers CJ. Nonspherical ZnS colloidal building blocks for three-dimensional photonic crystals. *J Colloid Interface Sci.* 2004; 274(1):103-106.
  14. Wang S, Nagrath D. Liver Tissue Engineering. *Biomaterials for Tissue Engineering Applications: A Review of the Past and Future Trends.* 2010; 14:389.
  15. Poynard T, Mchutchison J, Manns M. Impact of Pegylated interferon alfa-2b and ribavirin on liver fibrosis in patients with chronic hepatitis C, *Gastroenterology.* 2002; 122:1303-1313.
  16. Stehbens WE. Oxidative stress, toxic hepatitis, and antioxidants with particular emphasis on zinc, *Experimental and Molecular Pathology.* 2003; 75(3):265-276.
  17. Fang YZ, Yang S, Wu G. Free radicals, antioxidants, and nutrition, *Nutrition.* 2002; 18(10):872-879.
  18. Saad AR, Fath ME, Shalaby AA. Attenuation of acute and chronic liver injury by melatonin in rats, *Journal of Taibah University for Science.* 2013; 7:88-96.
  19. Lieber CS, Leo MA, Mak KM. Model of nonalcoholic steatohepatitis. *Am. J Clin. Nutr.* 2004; 79:502-509
  20. Burtis CA, Ashwood ER. *textbook of clinical chemistry.* 3<sup>rd</sup> ED. London. Chapter. 1999; 12(33):1145-1150.
  21. Van Uffelen BE, Van der Zee J, de Koster BM, Van Sterenink J, Elferink JG. Intracellular but not extracellular conversion of nitroxyl anion into nitric oxide leads to stimulation of human neutrophil migration, *Biochem. J.* 1998; 330:719-722.
  22. Reitman S, Frankel S. *Biochemical analysis: Amer. J Pth.* 1957; 28:56.
  23. Kind PR, King EJ. Estimation of plasma phosphatase by determination of hydrolysed phenol with amino-antipyrine. *J Clin. Pathol.* 4:322-326.
  24. Walters MI, Gerarde HW. An ultramicromethod for the determination of conjugated and total bilirubin in serum or plasma. *Microchem J.* 1954; 15:231-243.
  25. Luna LG. *Manual of histologic staining methods of the armed force institute of pathology.* 3<sup>rd</sup> Ed. 1968; McGraw-Hill, New York.
  26. SAS. (statistical analysis system), statistical user's Guide. INT., Cary, NC, USA, 2002.
  27. Duncan DB. Multiple range multiple F tests. *Biometrics.* 1955; 11(1):1-42.
  28. Kazemi S, Asgary S, Moshtaghian J, Rafieian M, Adelnia A, Shamsi F. Liver-protective effects of hydroalcoholic extract of *Allium hirtifolium* Boiss. in rats with alloxan-induced diabetes mellitus. *ARYA Atheroscler.* 2010; 6(1):11-5.
  29. Baydas G, Ozveren F, Tuzcu M. Effects of thinner exposure on the expression pattern of neural cell adhesion molecules, level of lipid peroxidation in the brain and cognitive function in rats, *Eur. J Pharmacol.* 2005; 512(2-3):181-187.
  30. Dundaroz MR, Turkbay T, Akay C, Sarici SU, Aydin A, Denli M. Antioxidant enzymes and lipid peroxidation in adolescents with inhalant abuse. *The Turkish journal of pediatrie.* 2003; 45:43-45
  31. Sinclair AJ, Barnett AH, Lunie J. Free radical and auto-oxidant systems in health and disease, *Journal of Applied Medicine.* 1991; 17:409-412.
  32. Czechowska G, Celinski K, Korolczuk A, Wojcicka G, Dudka J, Bojarska A, *et al.* Protective effect of melatonin against thioacetamide-induced liver fibrosis in rats, *journal of physiology and pharmacology.* 2015; 66(4):567-579.
  33. Okuyama H, Nakamura H, Shimahara Y, Araya S, Kawada N, Yamoka Y, *et al.* Overexpression of thioredoxin prevents acute hepatitis caused by thioacetamide or lipopolysaccharide in mice. *Hepatol.* 2003; 37:1015-1025.5
  34. Nkosi CZ, Opoku AR, Terblanche SE. Effect of pumpkin seed (*Cucurbitapepo*) protein isolate on the activity levels of certain plasma enzymes in CCl<sub>4</sub>-induced liver injury in low-protein fed rats, *Phytotherapy Research.* 2005; 19(4):341-345.
  35. Abul Najmi K, Pillai KK, Palv SN, Akhtar M, Aqil M, Sharma M. Effect of l-ornithine l-aspartate against thioacetamide-induced hepatic damage in rats, *Indian Journal of Pharmacology.* 2010; 42(6):384-387.
  36. Shim JY, Kim MH, Kim HD, Ahn JY, Yun YS, Song JY. Protective action of the immunomodulator ginsan against carbon tetrachloride-induced liver injury via control of oxidative stress and the inflammatory response, *Toxicology and Applied Pharmacology.* 2010; 242:318-325.
  37. Mehul DC, Varsha GJ. Effect of polyherbal preparation on thioacetamide induced liver damage and hepatic encephalopathy in rats, *international research journal of*

- pharmacy. 2012; 3:(6).
38. Raghavendren HR, Sathivel A, Devaki T. Hepatoprotective nature of seaweed alcoholic extract on acetaminophen induced hepatic oxidative stress. *J. Health Sci.* 2004; 50(1):42-46.
  39. Zargar S. Protective effect of *Trigonella foenum-graecum* on thioacetamide induced hepatotoxicity in rats. *Saudi Journal of Biological Sciences.* 2014; 21(2):139-145.
  40. Anbarasu C, Raj Kapoor B, Bhat KS, John G, Amuthan A Arul, Satish K. Protective effect of *Pisonia aculeata* on thioacetamide induced hepatotoxicity in rats, *Asian Pacific Journal.* 2012; 2(7):511-515.
  41. Isabel F. Dysregulation of apoptosis in hepatocellular carcinoma cells. *World J Gastroenterol.* 2009; 15:513-520.
  42. Greenwel P, Domínguez- Rosales JA, Mavi G, Rivas-Estilla AM, Rojkind M, Hydrogen peroxide: a link between acetaldehyde - elicited  $\alpha 1(I)$ collagen gene up-regulation and oxidative stress in mouse hepatic stellate cells. *Hepatology.* 2000; 31:109-116.
  43. Friedman SL. Molecular regulation of hepatic fibrosis, an integrated cellular response to tissue injury. *J Biol Chem.* 2000; 275:2247-50.