Journal of Entomology and Zoology Studies

Available online at www.entomoljournal.com

E-ISSN: 2320-7078
P-ISSN: 2349-6800
JEZS 2018; 6(1): 1654-1658

Received: 22-11-2017
Accepted: 23-12-2017

Hamrat Khadidja
Directorate of Agricultural Services Veterinary Inspection of department of Tizi-Ouzou, Algeria

Yahia Achour
Saad Dahleb University, Laboratory of biotechnologies related to animal reproduction, institute of veterinary sciences, university of Blida 1, Algeria

Correspondence
Hamrat Khadidja
Directorate of Agricultural Services Veterinary Inspection of department of Tizi-Ouzou, Algeria

Microscopic aspect of the hydatid cyst in dromedaries in the Algerian Desert

Hamrat Khadidja and Yahia Achour

Abstract
The present work was carried out on five livers and lungs with hydatid cyst, taken from seven 7-year-old camels. The method was based on classical techniques, namely histology, fixation, realization of inclusion, cutting, making slides, dewaxing, rehydration, staining, dehydration, editing and reading slides. The average diameter of the hydatid cyst varied between 0.5 and 1.3 cm and those pulmonary cysts vary between 1.5 and 2.2 cm. The results showed that the wall of the hydatid cyst was composed of the proliferous membrane, of the stratified membrane and the perikist. The connection between the parasite and the intermediate host tissue caused granulomatous local inflammation, a fact described even in other ruminants; cysts are observed at the early stage of degeneration and necrosis, with a large number of eosinophils observed outside lymphocytes. Finally, the histology of the hydatid cyst of the dromedary allowed us to identify layers constituting the parasite and to know the local reaction between host and parasite with appearance of the fertility cyst to distinguish it from other cysts of other species.

Keywords: camel, lung cyst, liver cyst, histology, granulomatous inflammation

1. Introduction
Cystic echinococcosis is a zoonotic helminthic which can sometimes affect human mainly the liver and the lung causing economic losses. This cosmopolitan zoonosis represents in many regions of the world a real scourge for animal husbandry and public health. In Mauritania, for example it is present in almost all slaughterhouses, in algeria little study have been realized, but it seems than the main areas livestock camelin up of the likely sites of hydatidosis foci, as the dromedary is the preferred host for Echinococcus larvae granulosus [1, 2].
Morphological experimental studies shows that the growth and the development of hydatid cyst is formed of two types of structures: morphological forming with pathogenic and hydatid proprieties; Morphological forming belonging to the host tissue. Noting that the spherical hydatid can measure several millimeters to several centimeters in diameter. It includes: external cuticular membrane and an internal proligerous membrane produced by budding proligerous vesicles, the hydatid is filled with a clear liquid. The adventitious is a fibrous area corresponding to the reaction of the host, it surrounds the hydatid. The cuticle is elastic consistency measuring between 0.5 and 1 mm, thick, structureless and consists of concentric layers superimposed. The proligerous membrane is very thin (10-25 microns) granular, of syncitiale structure with numerous nuclei, it buds on its inner side facing proligerous vesicles which bud in their turn to have protoscoleces, they are released into hydatid liquid because of a rupture of the proligerous vesicles. The protoscoleces is of ovoid form, measuring (50-150) microns and has four suckers and an invaginated rostellum whose hooks are clearly visible [3-6].

2. Materiels and Methods
2.1 Study area
The city of Touggourt is an oasis in the north of the Algerian Sahara. Touggourt is the largest city in the region of Oued Righ, its territory extends over the following territorial consistencies: Tebesbest, Nezla, Zaouia Al Abidia and Touggourt. The city is a center of trade and tourism important of 143 270 inhabitants in 20082.

2.2 Samples
The present study was conducted during the years 2010-2012, on the Camel species of the regions of Touggourt and el Oued located 700 km south of the capital Algiers. The study took place at the Touggourt slaughterhouse. In total, 15 dromedary carcasses, the object of post-

mortem inspection for the systematic search for hydatid lesions in the viscera. During the ante mortem examination, origin, age and sex were noted for each animal, hydatid cysts were removed in their entirety from the infested organ. The volume of cysts, the number of cysts per organ and their location (pulmonary or hepatic) were also recorded. Histological sections of the hydatid cysts were made and stained with hematoxylin-eosin according to the technique described in the literature.

In the first place, cyst concervation was 10% formalin, sent to the regional hospital of Ourgla province to make cuts, fragments of both organs (liver, lungs) (Fig. 1, and 2) were taken from specimens (Fig.3) fixed to 10% formaldehyde integrated with paraffin sectioned 5 µm, stained with hematoxylin and eosin (HE), periodic acid Schiff (PAS), hematoxylin phloxine saffron (HPS), alkaline blue (AB), Gomori trichrome (GT) with the appropriate controller mounted and finally examined under the microscope.

Fig 1: Germinal membrane of hepatic hydatid cyst

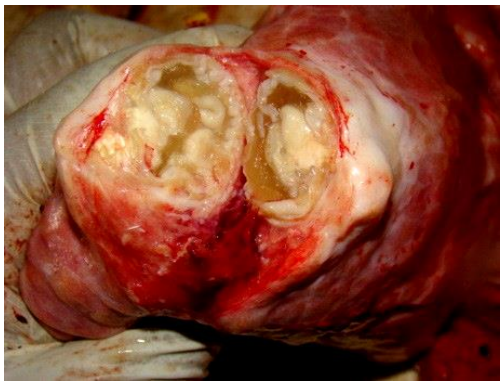

Fig 2: Pulmonary hydatid cyst fertile dromedary with germinal membrane

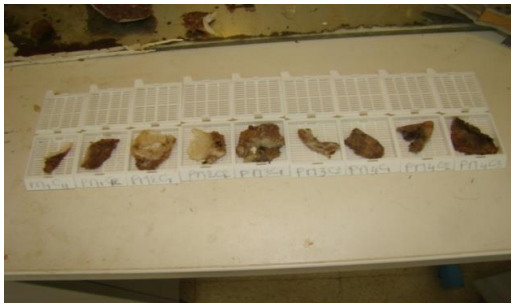

Fig 3: Distribution of fragments of organs tapes

3. Results

The results obtained in our work were generalized by cellular formations of giant nature in contact between cuticular membrane and perikist, with fibrous proliferation of compact granuloma and lympho-histiocytic infiltration, and giant multinucleate cells characteristic of unipolar nuclei.

The structure of the cyst was very clear and clear, see the structure of the endocyst liver (proliferous membrane), ectocyst (laminated membrne) and pericyst with syncitial layer formation cellular nature, with even the cyst wall is viable and fertile (Fig 4 and 5)

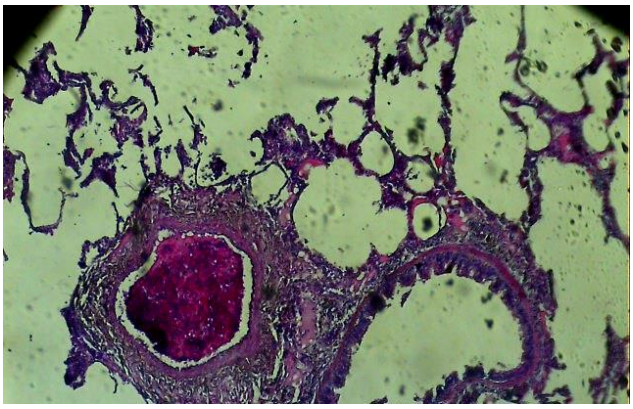

Fig 4: Formation of giant cell type contact between membrane and cuticular perikyste (Gross, x40)

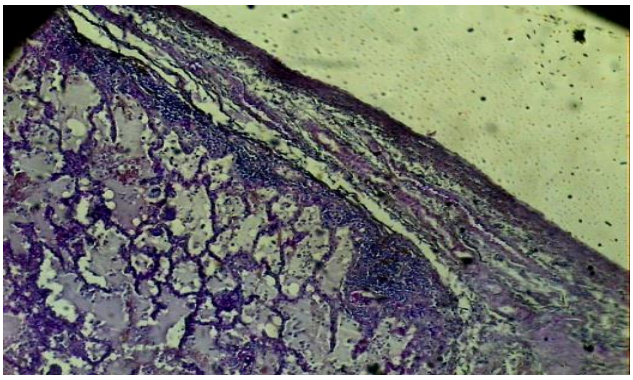

Fig 5: The structure of the hydatid cyst of the liver: endokyste, ectokyste and perikyste, (Gross, X100)

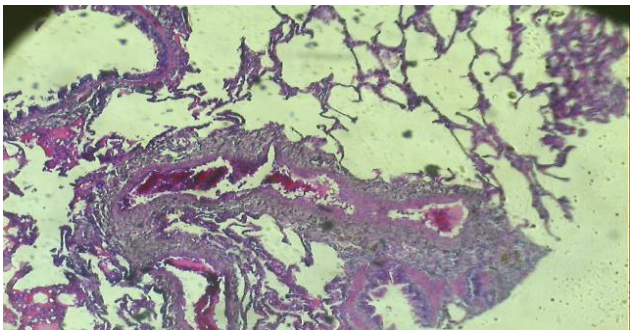

Fig 6: Lymphocytic infiltration with eosinophilia and translucent layers and Endokyste clear and well preserved fertile cyst (Gross, X100)

The results obtained in our work were generalized by cellular formations of giant nature in contact between cuticular membrane and perikist, with fibrous proliferation of compact granuloma and lympho-histiocytic infiltration (Fig.5), And giant multinucleate cells characteristic of unipolar nuclei.

The atrophy and necrosis of hepatic cells following the fibrosclerosis process produced by consolidation of the perikist membrane characterized some livers, (Fig. 5 and Fig. 6), we also noted lymphocyte and eosinophilic infiltrations (Fig. 6), Endocyst which is thin and translucent and clear and preserved layers it was fertile cyst (Fig.7).

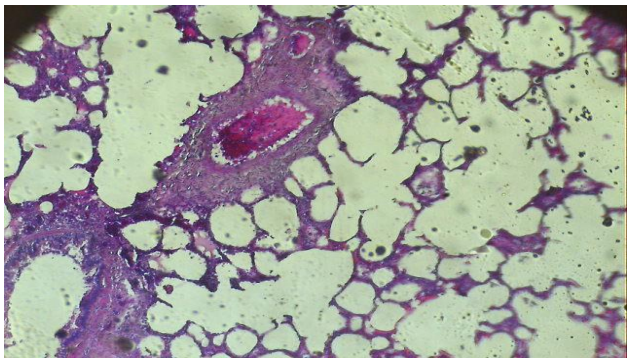

Fig 7: Lymphocytic infiltration with eosinophilia and thin and translucent layers and Endokyste clear and well preserved fertile cyst (Gross, X10)

This microscopic observation showed that all tissues showed signs of reaction between the host (cell) and cyst, marked by infiltration of the adventitious layer with neutrophils, eosinophils and plasma cells in addition to this inflammatory infiltrate, the new one. space between the liver and the cyst wall tissue contained the disrupted fibroblasts and mesenchymal cells. Giant cells are distinguished by the large number of nuclei arranged in a particular area of the cytoplasm located opposite the cuticular membrane.

4. Discussion

Cystic echinococcosis is a helminthic zoonosis that can affect humans, most often the liver and the lung where it provokes expansive cystic lesions. Endokyste membrane is the thinnest, delicate and translucent; it produces the cyst liquid and generates new elements able to expand larval infestation Histological investigations made in the study of the evolution and dynamics of hydatid cyst of the host tissue shows that the complex form with all the mentioned morphology is temporary and gradually due to multiple host- parasite relation- ships [1, 2]. Decreasing granulomatous or cystic form complicated by the intervention of other pathogens are obtained through is caused by the presence of fibrosis, necrosis and areas of calcification and the investigation was performed on tissue sections: liver and lung, usually collected from the camel they are portions of harvested tissue mainly on the cyst wall and the host tissue. The results are giant cells formation in contact between the membrane and cuticular perikyste, with fibrous proliferation of granuloma compact and histiocytic lymphocytic infiltration and multinucleated unipolar giant cells characterised as unipolar nuclei (Fig. 4). The structure of the cyst was very sharp and clear, see the structure of the endokyste liver (proligerous membrane),ectokyste (laminated membrane) and the formation of perikyste syn- cytial layer cell type,(Fig. 6), we have recorded a case of granuloma compact fibrous structure located in the liver, it is a very rare case,(Fig. 5), we have also the atrophy and necrosis of liver cells resulting from the process of fibrosclerosis.The microscopic observation shows that all tissues have signs of reaction between the host (cellular) and cyst, characterized by infiltration of the adventitia layer with neutrophils, eosinophils, and plasma cells in addition to the inflammatory infiltrate. The new space between the liver and the tissue cyst wall contained fibroblasts and disorganized mesenchymal cells [6]. Cuticular membrane stimulates the proliferation of important adventitia and monocyte-macrophage system represented by multinucleated giant cells and epithelioid on large surfaces, the contact line is the cell membrane separating cuticular syncitiale perikystique fibroconjonctive membrane structure, the layer of epithelioid cells and giant is distributed evenly around the circumference cystic, its thickness is also found in limited areas of necrobiosis cells and even areas of cellular debris.Giant cells are distinguished by the large number of nuclei arranged in a particular area of cytoplasm located in front of the cuticular membrane. Proliferation of connective fibers, collagen, it is reinforced by the development of bundles arranged concentrically. For the structure of the fiber, there is a strong network of neoformation of blood. Vessels and cellular infiltration is heterogeneous, eosinophils individualized, lymphocytes, histiocytes, macrophages, plasma cells and connective young fibroblasts, some studies show that hydatidosis lesions predominated by pulmonary and hepatic localizations in the camel, which is explained by the embryophores migration since they are released in the intestinal lumen, and thanks to their hook attaches during this migration, they meet two essential filter, the liver and the lung, that is to say there is a preference for the venous system, in addition, the diversity of strains of Echinococcus granulosus is also involved [7, 8]. For this study the histology of hydatid cyst, camels shows that the structure of the latter is as follows: thick cuticle, proligerous membrane, visible and clear proligerous capsules [7], Hydatids on fertile protoscoleces attached to the proligerous membrane, in the form of proligerous capsules and especially in camel lung cysts.Concerning the other species as sheeps and goats, the histological structure of hydatid cysts is not the same as in camels, because the cuticle and proligerous membrane are much less developed with the presence of inflammatory cell reactions and necrosis more frequent and intense,The transition from compact granuloma cyst occurs on stage and was present in all studied tissues, casuistry parasitized (liver, lung) of camels. Early morphological elements that alter the structure of the granuloma are hydatid cyst scolices, the proligerous membrane and hydatid are fluid. The structure with greater resistance components proved to be hydatid cuticular membrane. During the first phase of involution, the hydatid fluid is reabsorbed.

In addition to the presence of protein clots components, including membrane and necrotic proligerous debris, Proligerous capsules with scolex retraction and necrosis are the only remaining form of microcavities containing fragments of necrotic tissue. Cuticular membrane detaches from the relationship with epithelioid and giant cells; begins to retract among the cuticular membrane folds accumulate casein meals abundant with hyalinization, and calcification process. This phenomenon of inflammation and local cellular reaction are mainly due to the presence of proteins that are considered a marker during infestation by E. *granulosus*, they have an essential role in the host-parasite relationship [9]. The cellular and humoral response to infection by E. *granulosus* is characterized by release of cytokines that enters the control isotype and antibodies production. Cytokines IL-4 regulates the synthesis of IgE and IgG [11, 12]. Other studies show that this antigen induces proliferation *in vitro* and *in vivo* E. *granulosus*, it may even Influence Th1/ Th2 balance by releasing IL4, IL10 and IL13 [10]. The ability of cyclophilin E. *granulosus* to determine IgE production does not depend on the intrinsic ability to induce the production of IL-4 [11]. We don't know how IgG4 and IgE production is regulated [3], the answer depends on the activation of Th2 immune in some circumstances, while in others helminth infections including the IgG4 predominates. Proligerous membrane is considered as the true parasite [13]. It is considered a living membrane that generates the entire structure of the hydatid cyst, the

laminated membrane plays the role of external support for the proligerous membrane being the strongest part of the cyst, its structure shows overlapping concentric layers forming a structure more than 1 mm thick. It is a protein-polysaccharide complex with glucosamine and galactosamine predominance [12, 14]. The perikyste is a fibrous capsule, developed during inflammatory reaction between host and parasite, initiated in the early stages of development of the post-oncosphere and the initial intensity of this reaction is specific for each host and it is one of the factors that affect the rate of development of the larval cestode. If the reaction is severe, it will lead to death or even degeneration of parasites while a moderate reaction allows the development a viable cyst. The structure of this area is fragile, but it shows eosinophils and leukocyte infiltration [15-17], according to eosinophilic infiltration in the middle happens when the fabric is still perikyste eosinocytes histiocytic origin. Embryos show a series of very rapid reorganization within 10-14 days resulting in cell proliferation, degeneration of small hooks, atrophy of the muscles, and blistering one central cavity and the development of germ layers and laminates. The initiation is produced by dividing the six pairs of minor germ cells, located at the posterior end of the embryo. These cells trigger the main processes of larval development (degeneration and vesiculation after budding). Once the central cavity is formed, the release of the proligerous layer, production of hydatidosis fluid and growth of the gallbladder are initiated. The gallbladder is the encephalocystic and may appear a month later, ; the protoscoleces are formed inside the progelous capsules after the basic structure of the cyst, it develops around 5 or 6 months after infection on the outside [18] the cyst is surrounded by a fibrous layer produced by the host, called perikyste [17-19].

5. Conclusion

The histological study of the hydatid cyst in the camelina species allowed us to identify the different constituent layers of this major parasite (Endokyste, Ectokyste and Perikyste) and to know the local reaction between host and parasite, and to assess the fertility of the cyst. the naked eye on lung and liver, and be able to distinguish the difference between the other species in cyst size and layer thickness of the parasite, however histology is only a means of diagnosis for the identification of the Fertility of sterility of the cyst with study of the degree of inflammation of the affected organ and remains also an orientation for the distinction between species granulosus for different animals to know the circulating species for economic, medical, and scientific interest.

It would therefore be necessary, in view of the economic, health and medical importance of this zoonosis, to continue and deepen this study by molecular characterization and comparison of isolates of hydatid cysts in the different species.

Animals between them, on the one hand, and with reference lines on the other, in order to identify the circulating Echinococcus Granulosus line (s). One of the consequences would be to clarify the epidemiological role of different animals in the transmission of hydatidosis in the region.

6. Acknowledgements

The authors are grateful to the Director of the Center for Scientific and Technical Research on Arid Areas and technicians of the Hospital of Ourgla for the assistance provided for the realization of the histological sections.

7. References

1. Bacciarini LN, Gottstein B, Pagan O, Rehmann P, Grone A. Hepatic alveolar echinococcosis in Cynomolgus monkeys *(Macaca fascicularis).* Vet. Pathol. 2004; 41:229-234.
2. Candolfi E, Kien T, Chaker E, Fourati M, Benyounes A. Interet de l'antigenemie et des anticorps IgG, IgM, IgA et IgE dans l'immunologie du kyste hydatique. Resultats de l'immuno-enzymologie. Bull. Soc. Pathol. Exot. 1985; 78:700-706.
3. Carmen Solcan, Gheorghe Solcan, Mariana Ioniţă, Doru V. Hristescu, Ioan L. Mitrea. Histological aspects of cystic echinococcosis in goats, Sci Parasitol. 2010; 11(4):191-198, ISSN 1582-1366 original research article
4. Coman Ioan. Cercetări epizootologice, diagnostice şi profilactice în hidatidoză la animale, universitatea de ştiinţe agricole şi medicină veterinară cluj-napoca facultatea de medicină veterinară, Teză pentru obţinerea titlului de "Doctor în medicină veterinară, 2002.
5. Gatti A, Alvarez AR, Araya D, Mancini S, Herrero E, Santillan G *et al*. Ovine echinococcosis I. Immunological diagnosis by enzyme immunoassay in sheep echinococcosis. Vet. Parasitol. 2007; 143:112-121.
6. Hiris A, Heath DD, Lawrence JB, Shaw RJ. *Echinococcus granulosus* ultrastructure of epithelial changes during the first eight days of metacestode development *in vitro.* Int. J. Parasitol. 1989; 19:221-229.
7. Lupaşcu GH, Panaitescu D. *Hidatidoza.* Edit. Academiei R.S.R., Bucuresti, 1968.
8. Mitrea IL. Research regarding immunodiagnostics, immune response and immune prophylaxis in hydatidosis in ruminants] [In Romanian]. PhD thesis, USAMV Bucharest, Romania, 1998.
9. Ortona E, Vaccari S, Margutti P, Delunardo F, Rigano R, Profumo E *et al*. Immunological characterization of *Echinococcus granulosus* cyclophilin, an allergen reactive with IgE and IgG4 from patients with cystic echinococcosis. Clin. Exp. Immunol. 2002; 128:124-130.
10. Ould Ahmed Salem CB, Schneegans F, Chollet JY, Jemli MH. Prévalence et aspects lésionnels de l'hydatidose chez les dromadaires et les petits ruminants au nord de la Mauritanie, Revue Élev. Méd. vét. Pays trop. 2010; 63(1, 2):23-28
11. Panaitescu d. Tratamentul medicamentos în hidatidoză secundară, cu medicaţii anti-malarice. Simpoz. „ *Actualităti în zoonozele parazitare*", Cluj-Napoca. 1992; XIX:22.
12. Paul I. [The morphology of the fundamental pathological processes] [In Romanian]. Editura Societăţii de Medicină Veterinară, Bucharest, Romania, 1989.
13. Paul I. *Etiomorfopatologie veterinara*. Edit. All, Bucuresti. 1996.
14. Sevil Atalay Vural, Hikmet Keles, Mehmet Haligur Citation SA Vural, Keles H, Haligur M. Uniloculaire hydatidose splénique chez un mouton Le Journal Internet de la médecine vétérinaire. Numéro 1.DOI: 2005, 2 10.5580/bb5
15. Smith JD. Changing concepts in the microecology, macroecology and epidemiology of hydatid diseases. *In:* Geerts S.; Kumar V., Brandt J. (Eds.), Helminth zoonoses. Martinus Nijhoff Publishers, Dordrecht, The Netherlands, 1987, 1-11.
16. Thompson RC, Lymbery AJ. Echinococcosis and hydatid diseases. Wallingford, Oxon, UK: CAB International, 1995.

17. Tigin Y, Burgu A. Et Doganay, Échinococcose chez les animaux Types A, 7 Congrès national de parasitologie, 22- Octobre, Ankara, x, 1991.
18. Vincenzo Lamonaca, Anthony Virga, Marta Ida Minervini, Roberta Di Stefano, Alessio Provenzani, Peter Tagliareni. *et al*. Echinococcose hydatique du foie et du poumon Traité par ablation Thermique par radiofréquence: Un ex-vivo Expérimentale Etude pilote dans des animaux Modèles, Publié en ligne 14 Juillet. doi: 10.3748/wjg.15.3232, 2009.
19. Gatti A, Alvarez AR, Araya D, Mancini S, Herrero E, Santillan G *et al*. Ovine echinococcosis I. Immunological diagnosis by enzyme immunoassay in sheep echinococcosis. Vet. Parasitol. 2007; 143:112-121.