



E-ISSN: 2320-7078

P-ISSN: 2349-6800

JEZS 2018; 6(2): 402-404

© 2018 JEZS

Received: 16-01-2018

Accepted: 19-02-2018

K Manoj Kuma

Phd Scholar, Dept. of Veterinary Surgery & Radiology, NTR College of Veterinary Science, Gannavaram, Andhra Pradesh, India

N Mohammed Sharif

Post graduate student, Dept. of Veterinary Microbiology, College of Veterinary Science, Tirupati, Andhra Pradesh, India

Surgical management of ocular squamous cell carcinoma in buffaloes: A report of 4 cases

K Manoj Kuma and N Mohammed Sharif

Abstract

Four cases of ocular squamous cell carcinoma (OSCC) in the buffaloes were presented to veterinary Hospital, Vinamur. Lesions showed different clinical aspects (cauliflower-shape masses and/or papilloma-like growths), protruding through the palpebral fissure placed at the level of the nictitating membrane or the sclera-conjunctival junction. The neoplastic out growths were resected under lignocaine hydrochloride (2%) with peterson nerve block. Histopathological examination revealed proliferating epithelial cells with concentrating layer of keratin forming cell nest.

Keywords: Buffaloes, eye, surgical excision, squamous cell carcinoma

Introduction

Squamous cell carcinoma is a tumor of epidermal cells in which the cells show differentiation to keratinocytes. Squamous cell carcinoma is the most commonly occurring neoplasm afflicting the bovine eye ^[3,6]. The most common areas affected are limbus (junction of the cornea and the sclera), third eyelid, and on the upper and lower eyelid margins primarily at mucocutaneous junctions ^[2]. The malignant tendency of this disease makes early recognition critical. The etiology of the disease is multifactorial. However, prolonged exposure to sunlight (ultraviolet light) also seems to be a driving force for the disease ^[1]. Mechanical irritations, injuries and burns can also lead to squamous cell carcinoma. A retrospective study on the incidence of bovine external neoplasms by Kohlirn *et al.* (2008) ^[2] shows that squamous cell carcinomas were the most common tumor (62%) followed by papillomas (26%). The carcinoma is commonly erythematous, ulcerated, friable and foul smelling. Growths on the clear part of the eyeball (cornea) are less prone to spread to other parts of the body (metastasize) than tumors on the white part of the eyeball (sclera). This report communicates four cases of ocular squamous cell carcinoma in a she buffaloes, which were successfully treated by surgical intervention.

Case history and clinical examination

Four cases of graded murrah buffaloes were referred to the Veterinary Hospital, Vinjamur with a history of growths protruding through the palpebral fissure, and placed at the level of the nictitating membrane or the sclera-conjunctival junction [Figure 1A, C, E, F]. Clinical examination revealed a hard growth in all the animals. The animal had normal vision with mild opacity of cornea. The rectal temperature, heart, pulse and respiratory rate were within the normal physiological limits. The surgical excision was decided and the site was prepared for asepsis.

Results and Discussion

Animal was sedated with Injection Xylazine (Inj. Xylazine, Neon laboratories, Mumbai, India) at the rate of 0.01 mg/kg body weight intravenously and regional anaesthesia was achieved by performing Peterson nerve block using 10 ml 2% lignocaine hydrochloride (Inj. Lidocaine, Virbac Animal Health India Pvt. Ltd., Mumbai). After administration of anesthetic agents the growth was excised by using surgical blade [Figure 1B, D, F, H]. The eye was lavaged with normal saline solution. Post operatively parental antibiotics Enrofloxacin at the rate of 5 mg/kg body weight and analgesic Meloxicam at the rate of 0.5 mg/kg body weight were administered intra muscularly, daily for five consecutive days.

Correspondence

K Manoj Kuma

Phd Scholar, Dept. of Veterinary Surgery & Radiology, NTR College of Veterinary Science, Gannavaram, Andhra Pradesh, India

Eye ointment (C Flox -D) was applied topically in the affected eye (thrice per day) for 10 days. The animal was recovered

Uneventfully within 15 days and no complication has been reported till one month after operation. On histopathological examination, proliferating epithelial cells with concentrating layer of keratin forming cell nest was found [Figure 2]. The tumorous growth was confirmed as a squamous cell carcinoma as similar finding reported by Patel *et al.* (2009) [4] in buffalo. In India, among cattle, squamous cell carcinoma is a common tumor affecting the horn and eye [5]. It is found on skin of animals in various locations and melanin is protective against the actinic rays of sun. In areas where pigmentation is deficient squamous cell carcinoma has been seen [5]. Solar dermatosis is the first recognizable change at mucocutaneous junctions or on the skin of sparsely haired that lacks pigment. Erythema, edema and scaling are followed by crusting, scaling and thickening of the epidermis with subsequent ulceration. As the tumor becomes invasive of the dermis, the lesion feels more indurated [2].

Conclusion

Early recognition and evaluation of squamous cell carcinoma is necessary to remove easily without much complication.

Acknowledgments

The authors wish to acknowledge the contributions of the staff of the Veterinary Hospital, Vinjamur.

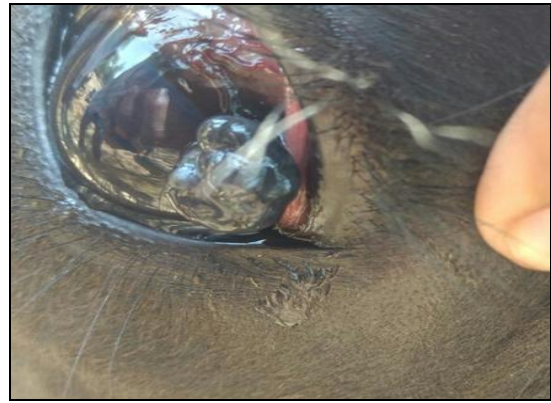

Fig 1C: Growth near the limbus of the left eye.



Fig 1D: Excision of neoplastic growth

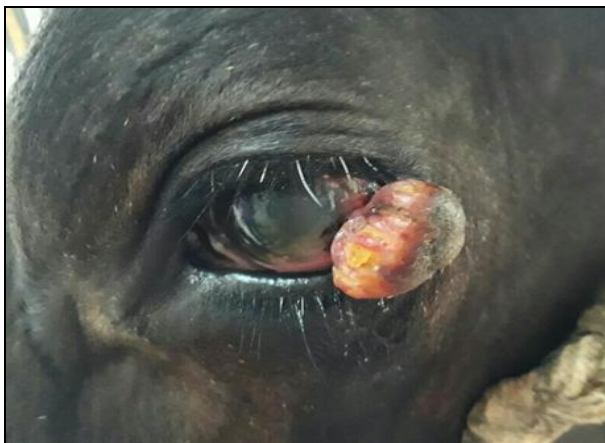

Fig 1A: Growth near the limbus of the left eye.

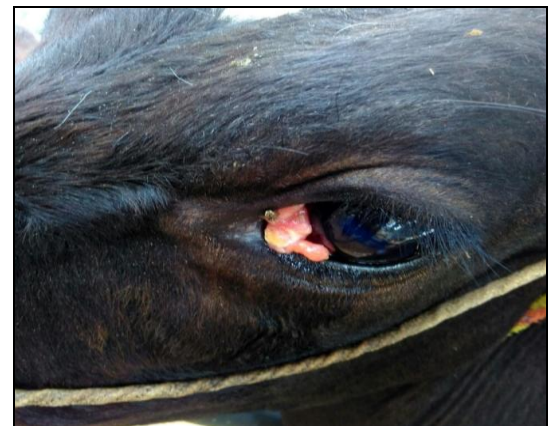

Fig 1E: Growth near medial canthus of eye




Fig 1B. Excision of neoplastic growth

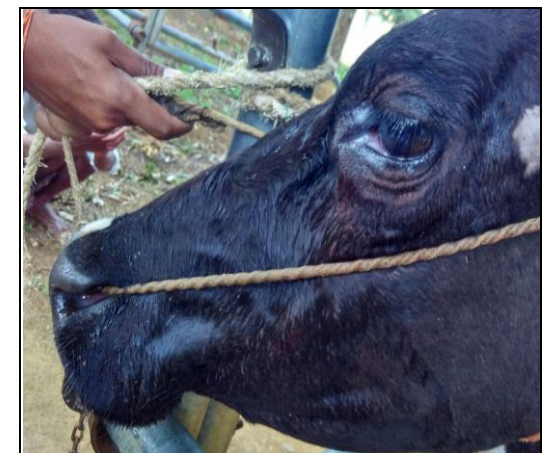

Fig 1f: Eye After Removal Of Growth

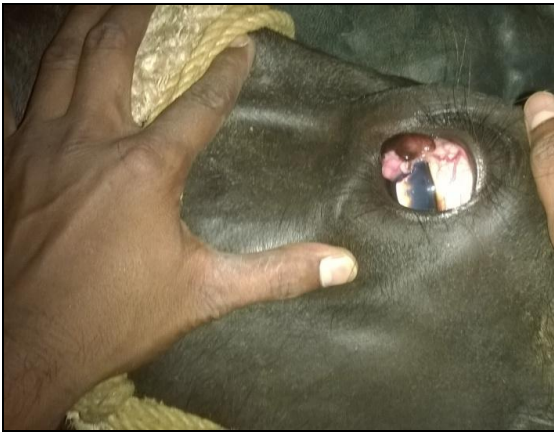

Fig 1g: Growth near Medial Canthus of Eye

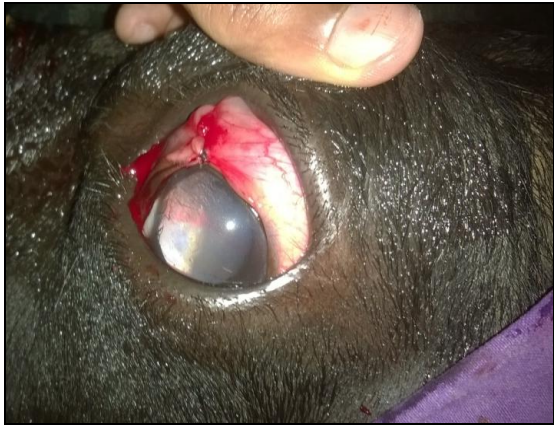

Fig 1h: Eye after Removal of Growth

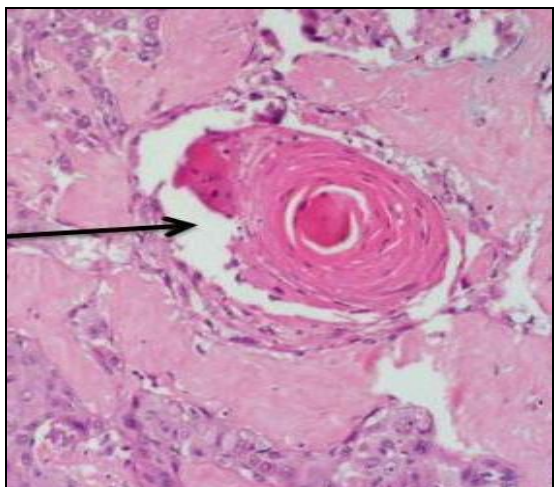


Fig 2: keratin forming cell nest

References

1. Anderson DE, Badzioch MS. Association between solar radiation and ocular squamous cell carcinoma in cattle. *American Journal of Veterinary Research*. 1991; 52:784-788.
2. Goldschmidt MH, Hendrick MJ. Tumors of skin and soft tissues. Meuten, DJ. In text book of Tumors of Domestic Animals, Edn 3, Iowa State Press. 2002; 4:153.
3. Kohlirn EW, Mashadi AG. Squamous cell carcinoma in an Iranian buffalo. *Indian Veterinary Journal*. 2008; 85:555-556.
4. Patel PB, Mistry JN, Suthar DN, Patel JB. Surgical Management of ocular squamous cell carcinoma in buffalo calf. *Intas Polivet*. 2009; 10(2):293-294.
5. Sastry GA. *Veterinary Pathology*. Edn 1, CBS Publishers

and Distributors, Delhi, 1983, 6:247-249.

6. Sivaseelan, S, Balasubranmaniam GA, Srinivasan P, Balachandran P, Thangathurai R, Dharmaceelan S *et al*. Squamous cell carcinoma of eye in a she buffalo. *Tamilnadu Journal of Veterinary and Animal Sciences*. 2008; 3:117-118.