



E-ISSN: 2320-7078

P-ISSN: 2349-6800

JEZS 2018; 6(3): 547-551

© 2018 JEZS

Received: 17-03-2018

Accepted: 18-04-2018

**Khan Idrees Mohd**

Department of Veterinary  
Anatomy, College of Veterinary  
and Animal Sciences, GBPUAT,  
Pantnagar, Uttarakhand, India

**Ishwar Singh**

Department of Veterinary  
Anatomy, College of Veterinary  
and Animal Sciences, GBPUAT,  
Pantnagar, Uttarakhand, India

**Rabab Saleem**

Department of Veterinary  
Anatomy, College of Veterinary  
and Animal Sciences, GBPUAT,  
Pantnagar, Uttarakhand, India

## Gross morphometrical changes in the ovaries of indigenous fowl (Uttara fowl) during postnatal development

**Khan Idrees Mohd, Ishwar Singh and Rabab Saleem**

### Abstract

The present investigation was performed, to study the detailed morphological changes occurring during postnatal development of the ovary. The experiment was conducted on 54 apparently healthy female fowl of different age groups (day-old and weeks 1, 4, 8, 12, 16, 20, 24 and 28) reared at Instructional Poultry Farm G.B.P.U.A.T, Pantnagar for 28 weeks during year 2017. Postnatal development of female reproductive system started with development of left ovary and oviduct with simultaneous regression of right ovary and oviduct. The ovarian weight increased non-significantly ( $P \leq 0.05$ ) from day 1 to 16 weeks of age. However, there was a significant increase in weight of left ovary from the 16 to 28 weeks of age. The ovarian morphology changed during postnatal development. It started as smooth elongated organ at day-old age, underwent segmentation with age to ensure increased surface area for follicular eruption and followed by grape bunch like appearance at laying phase due to formation of the hierarchical follicles.

**Keywords:** Postnatal development, Uttara fowl, ovary and hierarchical follicles

### Introduction

The avian female reproductive system is unique because only the left genital primordia develop to form functional organs (left ovary and oviduct) with few exceptions such as birds of prey <sup>[1]</sup>. However, functional left and right ovaries and associated oviduct are found in the Falconiformes and in the Brown Kiwi <sup>[2]</sup>. The local Hill fowl also called as Uttara fowl is an indigenous fowl found in the Kumaun region of Uttarakhand India which is adjoining to the Nepal and Tibet border <sup>[3]</sup>. The local Hill fowl symbolizes a precious and distinctive germplasm which is well adapted under harsh climatic and unsatisfactory management conditions in the villages. The hill fowl are unique in acclimatising to the agro-climatic conditions of mountainous terrain of the Uttarakhand. The average age at sexual maturity in local Hill fowl varied from 6-7 months in backyard system. The range of egg production was found to be 90 to 150 eggs in a laying cycle under backyard system. The egg weight ranged from 30 to 55 gm. The eggs are light brown and pinkish in colour with sound egg shells. The values of fertility and hatchability were more than 85% and 70% respectively <sup>[4]</sup>. The objectives of present investigation were to study the gross anatomy and the morphometrical parameters of ovary during different phases of postnatal development. The study was aimed to study the follicular growth and their developmental stages during postnatal development.

### Materials and Methods

The present study was conducted in Department of Veterinary Anatomy, College of Veterinary and Animal Sciences, G.B. Pant University of Agriculture and Technology, Pantnagar (Uttarakhand). The experiment was conducted on the female reproductive system of 54 apparently healthy female local Hill fowl divided into different age groups viz. day 1 and weeks 1, 4, 8, 12, 16, 20, 24, 28. Based on age, the birds were divided into nine age groups viz. I, II, III, IV, V, VI, VII, VIII and IX, with six birds each <sup>[5]</sup>. The birds of specified age groups were sacrificed as per the guidelines of SPCEA/ IAEC by severing jugular vein and common carotid artery. Following parameters were recorded: Weight of birds (live body weight); Weight, length, width and thickness of the left ovary; Weight, length, width and thickness of the right ovary wherever identified.

The data were analyzed using 'univariate' analysis for completely randomised design and means separated using 'Tukey's test'.

### Correspondence

**Khan Idrees Mohd**

Department of Veterinary  
Anatomy, College of Veterinary  
and Animal Sciences, GBPUAT,  
Pantnagar, Uttarakhand, India

When the variables in the data failed normality test 'Kruskal-Wallis test' was used instead. For comparison of right and left ovary 'paired t test' was applied.

### Results and Discussion

The left ovary of day old chick was smooth, elongated S-shaped and yellowish white organ, placed obliquely on the ventro-medial aspect of the left kidney. The left ovary was well developed as compared to right one which was present as visible rudiment. The observations corroborated with findings of Gonzalez-Moran [6] in growing (left) and regressing (right) chicken ovaries during post hatching development. The presence of rudimentary right ovary was also reported [7, 8] in chickens. However, functional right ovary was reported in, Falconiformes and Brown Kiwi [9] and in birds of prey [2]. The left ovary was suspended from the dorsal body wall by mesovarium forming an ill-defined ovarian stalk. The cranial end of the left ovary was broader and tapered gently to form a narrow caudal apex. These findings were in accordance with

observations of Shokry *et al.* [10] who reported that day-old ovaries of Alexandria chicken were fan-shaped structure with broader anterior end. The left ovary was bounded cranially by the caudal base of lung and attached to the medial surface of the anterior lobe of the kidney obscuring the adrenal glands. Moreover, it's ventral surface was related to proventriculus similar to the reports of Nickel *et al.* [11] in White Leghorn chicken. The gizzard was located caudoventral to the left ovary. These findings were in agreement with the reports of King [12] and Nickel *et al.* [11] in chicken. The weight, length and width of the left ovary in day old chicks were significantly ( $P \leq 0.05$ ) higher as compared to the right one. However, no significant difference was observed in the thickness of left and right ovary. The values of weight, length, width and thickness at day 1 of age, were recorded as shown (Table 1). Shokry *et al.* [10] reported some higher values of length and width in Alexandria breed. The difference was due to breed variation.

**Table 1:** Comparative gross morphometrical measurements of left and right ovary at day one and 1 week of age (Mean  $\pm$  SE).

Parameters (Mean $\pm$ SE)	Day 1		Week 1	
	Left	Right	Left	Right
Weight (g)	0.0095 <sup>a</sup> $\pm$ 0.001	0.0057 <sup>b</sup> $\pm$ 0.001	0.015 <sup>a</sup> $\pm$ 0.001	0.004 <sup>b</sup> $\pm$ 0.002
Length (cm)	0.33 <sup>a</sup> $\pm$ 0.02	0.24 <sup>b</sup> $\pm$ 0.01	0.49 <sup>a</sup> $\pm$ 0.02	0.17 <sup>b</sup> $\pm$ 0.02
Width (cm)	0.12 <sup>a</sup> $\pm$ 0.007	0.10 <sup>b</sup> $\pm$ 0.006	0.20 <sup>a</sup> $\pm$ 0.02	0.08 <sup>b</sup> $\pm$ 0.01
Thickness (cm)	0.06 <sup>a</sup> $\pm$ 0.006	0.05 <sup>a</sup> $\pm$ 0.003	0.12 <sup>a</sup> $\pm$ 0.006	0.045 <sup>b</sup> $\pm$ 0.005

\*Mean with different superscripts differ significantly ( $P \leq 0.05$ )

At 1 week of age, the right ovary of the chick was further regressed as small linear structure as reported by Nickel *et al.* [11] in the fowl. The left ovary appeared as pale white, dorso-ventrally flattened and crescent-shaped structure (Fig. 1). The ovarian surface was smooth, due to the absence of surface follicles. The relationship between left ovary and gizzard disappeared because proventriculus covered the entire ventral surface at this stage of development. At 1 week of age the weight, length, thickness and width, were significantly ( $P \leq 0.05$ ) higher in the left ovary as compared to the right one. The values of the weight, length, width and thickness were recorded as shown in Table 1. A similar trend of increase in length and width of the left ovary was recorded by Shokry *et al.* [10] in Alexandria chicks from day 1 to 1 week of age. At 4 weeks of age, the right ovary was completely regressed as inconspicuous vestige and only left ovary was observed on the left side of the dorsal part of the abdominal cavity close to the median line. These finding were in agreement with the reports of Sisson and Grossman [13], Ingole [14] and Banerjee *et al.* [15] in the domestic fowl. The left ovary was pale yellowish pink, elongated, triangular structure with a wide cranial part and narrow caudal apex (Fig. 2). Nickel *et al.* [11] also described that the left ovary of immature chicken as elongated Triangle. Hodges [7], King [12] and Ingole [14] similarly described the colour of ovary as pale yellowish pink. However, Nickel *et al.* [11] revealed it as yellowish white and Banerjee *et al.* [15] reported it to be pinkish red coloured. During the post natal development, the left ovary gradually

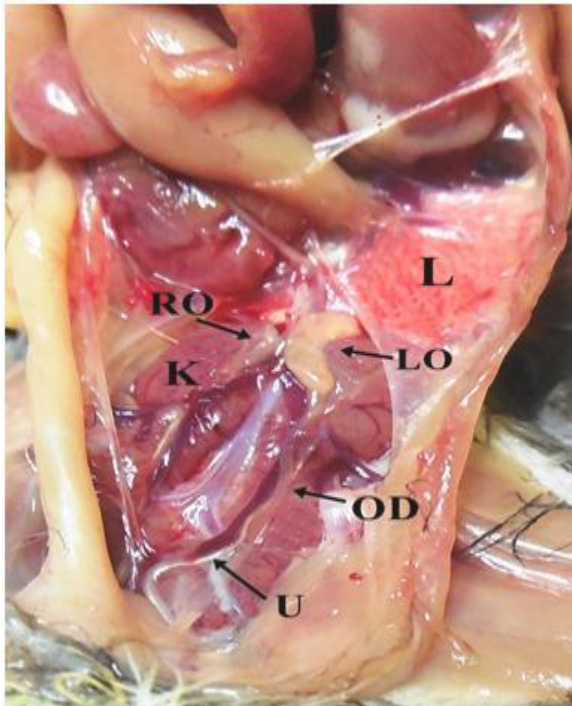
increased in size as well as complexity. The ovarian surface was thrown in to ridges with faint sulci and divided into cranial and caudal segments with a deep sulcus (Fig. 2). The deep sulcus traversed laterally and obliquely across the surface of the ovary. The findings were in accordance with Prochazkova and Komarek [16] in immature ovary of domestic fowl.

The length, width, thickness, weight and relative ovary weight at 4 weeks of age were calculated as shown in (Table 2). At 8 weeks of age, the left ovary occupied the mid dorsal part of the abdominal cavity due to complete regression of the right ovary. The findings were in agreement with the reports of King [12] and Nickel *et al.* [11] in the domestic fowl. At this stage of development, ovary was divided into 6 segments separated by grooves. The segmentation ensured increased surface area in a restricted available space of the ovary in the coelom. The segmentation or formation of ridges and grooves was also reported by Nickel *et al.* [11] in the White Leghorn chicken during prepuberal phase of development of ovary. The ovary was triangular in shape. The ovarian surface was finely granular, ventrally convex and bulged. Nickel *et al.* [11] also reported that ovarian surface was finely granular in a two-month old White leghorn pullet. However, Dhyaa *et al.* [17], reported that surface of the ovary was granular at only 4 weeks of age in ducklings. The length, width, thickness, weight and relative weight of ovary at 8 weeks of age were calculated as shown in Table 2.

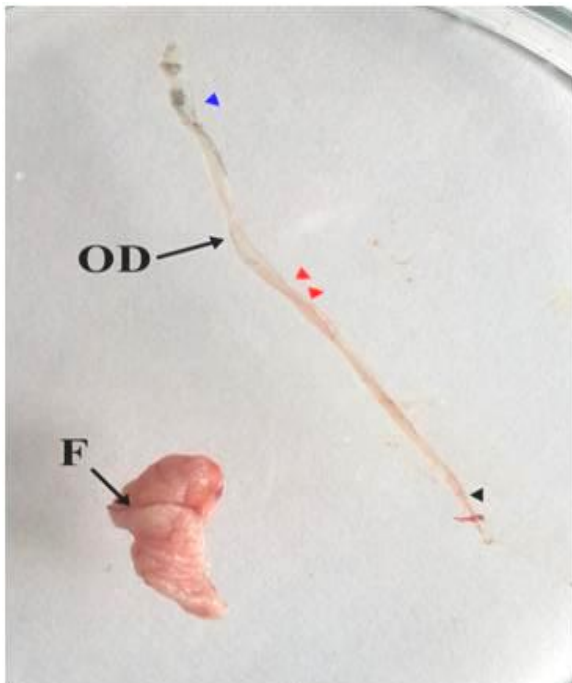
**Table 2:** Age group wise gross morphometrical measurements of left ovarian parameters during postnatal development (Mean ± SE)

Parameters (Mean ± S.E)	AGE								
	1 Day	1 week	4 week	8 week	12 week	16 week	20 week	24 week	28 week
Body weight (gm)	37.29 <sup>h</sup> ± 0.39	49.33 <sup>h</sup> ± 1.54	149.33 <sup>e</sup> ± 4.8	409.83 <sup>f</sup> ± 3.67	789.16 <sup>e</sup> ± 3.94	983.66 <sup>d</sup> ± 6.28	1094.33 <sup>c</sup> ± 20.84	1300.67 <sup>b</sup> ± 57.29	1406.5 <sup>a</sup> ± 32.36
Length (cm)	0.33 <sup>c</sup> ± 0.02	0.49 <sup>c</sup> ± 0.02	1.17 <sup>d</sup> ± 0.16	1.24 <sup>d</sup> ± 0.07	1.33 <sup>d</sup> ± 0.05	1.48 <sup>c</sup> ± 0.05	2.26 <sup>b</sup> ± 0.11	2.47 <sup>b</sup> ± 0.15	3.17 <sup>a</sup> ± 0.27
Width (cm)	0.12 <sup>c</sup> ± 0.00	0.20 <sup>c</sup> ± 0.02	0.64 <sup>d</sup> ± 0.03	0.8 <sup>d</sup> ± 0.01	0.92 <sup>d</sup> ± 0.07	1.07 <sup>d</sup> ± 0.04	1.48 <sup>c</sup> ± 0.13	2.06 <sup>b</sup> ± 0.09	2.28 <sup>a</sup> ± 0.08
Thickness (cm)	0.06 <sup>c</sup> ± 0.00	0.12 <sup>c</sup> ± 0.00	0.26 <sup>c</sup> ± 0.02	0.33 <sup>c</sup> ± 0.07	0.46 <sup>c</sup> ± 0.04	0.60 <sup>d</sup> ± 0.03	0.81 <sup>c</sup> ± 0.03	1.33 <sup>b</sup> ± 0.05	1.53 <sup>a</sup> ± 0.11
ovary weight (gm)	0.0095 <sup>d</sup> ± 0.001	0.014 <sup>d</sup> ± 0.001	0.06 <sup>d</sup> ± 0.003	0.19 <sup>d</sup> ± 0.01	0.38 <sup>d</sup> ± 0.01	0.51 <sup>d</sup> ± 0.02	1.53 <sup>c</sup> ± 0.12	13.51 <sup>b</sup> ± 0.91	26.25 <sup>a</sup> ± 1.14
Relative ovary weight (%)	0.025 <sup>c</sup> ± 0.002	.029 <sup>c</sup> ± 0.003	0.038 <sup>c</sup> ± 0.003	0.04 <sup>c</sup> ± 0.004	0.04 <sup>c</sup> ± 0.00	0.05 <sup>c</sup> ± 0.00	0.14 <sup>c</sup> ± 0.01	1.05 <sup>b</sup> ± 0.10	1.88 <sup>a</sup> ± 0.12

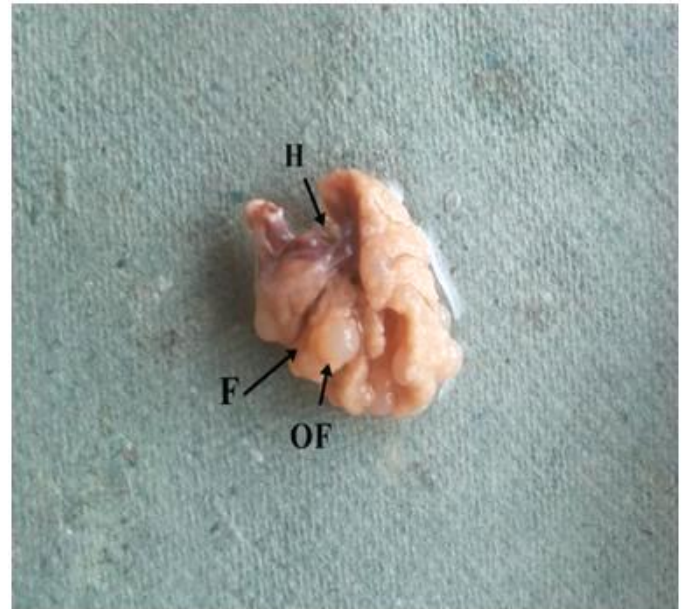\*Mean with different superscripts differ significantly ( $P \leq 0.05$ )




**Fig 1:** Photograph of female genitalia of local Hill fowl chick at 1 week of age, showing crescent shaped left ovary (LO), rudimentary right ovary (RO), oviduct (OD), kidney (K), ureter (U) and Cloaca (c).



**Fig 2:** Photograph showing left ovary and oviduct at 4 weeks of age. F denotes deep fissure of the ovary.



**Fig 3:** Photograph showing left ovary at 16 weeks of age, segmented by fissures (F). The hilus (H) is present on the ventral surface and small white follicle represented by (OF).



**Fig 4:** Photograph showing left ovary of mature local Hill Fowl at 28 weeks of age showing small (S), medium (M) and hierarchical follicles from F1-F6.

At 12 to 16 weeks of age the ovary assumed a spherical outlook with bulged, ventral convex surface and slightly concave dorsal surface containing ovarian stalk and hilus. At 12 weeks of age, the surface of the ovary was granular due to

presence of numerous minute follicles arranged in cords and closely apposed to the surface. At 16 weeks of age, the ventral surface of the ovary in addition to the minute follicles presented few small ripened follicles filled with liquor folliculi (Fig. 3). The follicles were grey in colour with diameter ranging from 1 to 5mm. However, Nickel *et al.* [11] reported that differentiation of ripened follicles began at earlier age i.e. at the beginning of 3<sup>rd</sup> month in the White Leghorn fowl. This delay in the growth and differentiation of follicles can be attributed to late maturity in Local Hill fowl. The length, width, thickness and weight of the left ovary were recorded as shown in Table 2. The results were justified by the findings of Banerjee *et al.* [15] in RIR fowl and Banerjee *et al.* [18] in Aseel. Due to continuous follicular growth and development, the sulci became obliterated and ovary assumed globular form. At 20 weeks of age, the ovary began to manifest the grape-bunch like appearance. The ovarian surface was seeded with numerous sessile small white follicles of average 5 mm diameter. At this stage there was a significant ( $P \leq 0.05$ ) gain in weight of the ovary due to growth of ripened follicle. The average length, width, thickness, weight and relative weight of the ovary were recorded as,  $2.26 \pm 0.11$ ,  $1.48 \pm 0.13$ ,  $0.81 \pm 0.03$  cm,  $1.53 \pm 0.12$  g and  $0.14 \pm 0.01$  % at 20 weeks of age, respectively (Table 2). The findings were in accordance with Hafeez and Kamar [19] who reported that ovary weight and relative ovary weight at 5 months of age before sexual maturity as 1.4 g and 0.17 % in Fayomi fowl. However, Banerjee *et al.* [15] stated that the weight of ovary at 5 months in Rhode Island Red birds was  $18.49 \pm 1.07$  g. The difference in the ovarian weight was due to late sexual maturity of Local Hill fowl as compared to RIR, the former attains the adult ovary weight at 6-7 months of age. The ovary of mature hen at 24-28 weeks of age, resembled a bunch of grapes (Fig. 4). It was attached to the cranial lobe of the left kidney by dorsal ligament and dorsal wall of the abdomen by the mesovarium. Similar findings were reported by King [12], Sturkie [8], Nickel *et al.* [11], Dyce *et al.* [20] in laying domestic hen and Deka *et al.* [21] in Pati and Chara-Chemballi ducks during the laying period. The ovary was located at the midline of the abdominal activity, and was related cranially to the caudal extremity of the lungs, ventrally to the proventriculus, abdominal air sac and dorsally to the aorta, both kidneys, and adrenal glands. Similar observations were reported by King [12] and Nickel *et al.* [11] in the domestic fowl and Ingole [14] in White Leg Horn fowl. The surface of ovary was bright yellow in colour due to the presence of large yellow to orange ovisacs (follicles) containing yolk and oocyte of future egg, projecting from the ventral surface of the ovary (Fig. 4). Each ovisac was attached to the main mass of ovary by pedicle or follicular stalk. Three types of surface follicles or ovisacs were observed viz. small (0.1-0.5 cm), medium (0.5-1.0 cm) and large (>1.0 cm) follicles. Nickel *et al.* [11] also reported that besides a large number of small follicles (3-10 mm) the ovary of mature hen has a number of dark yellow follicles measuring between 5-10 mm and even upto 40 mm in diameter. The small and medium follicles were white in colour and were classified as pre hierarchical follicles. The large yellow yolk filled follicles were classified as hierarchical follicles. In the laying hen, the number of hierarchical follicles varied between 5-6, with F5/F6 being largest and ready for ovulation (Fig. 4). The results were justified by the findings of Johnson [22], who reported that hierarchy consisted of 4 to 6 developing follicles, varying from bird to bird. The largest hierarchical follicle bulged out from the ovary with loose stalk which was ready for rupture.

The large follicles contained an avascular streak called as stigma lying opposite to the pedicle similar to the findings of Nickel *et al.* [11]. Hodges [7] also documented that blood vessels do not penetrate into the stigma. But, Nalbandov and James [23] have found fine vessels in the stigma. In addition to the growing follicles, a number of post-ovulatory follicles in different stages of regression were present. The post-ovulatory follicles appeared as empty sacs hanging on the ovarian substratum. They turned into brown and finally black inspissated mass. The average numbers of small, medium and large hierarchical follicles were calculated as  $91.50 \pm 8.53$ ,  $27.50 \pm 1.14$  and  $5.67 \pm 8.53$ , respectively.

The average length, width, thickness, weight and relative ovarian weight were recorded as  $2.47 \pm 0.15$ ,  $2.06 \pm 0.09$ ,  $1.33 \pm 0.05$  cm,  $13.51 \pm 0.91$  g and  $1.05 \pm 0.10$  % at 24 weeks and  $3.17 \pm 0.27$ ,  $2.28 \pm 0.08$ ,  $1.53 \pm 0.11$  cm,  $26.25 \pm 1.14$  g and  $1.88 \pm 0.12$  % at 28 weeks of age, respectively (Table 2). The results were comparably similar with the findings of Shyam [24] and Banerjee *et al.* [18] in the Aseel fowl and Hafeez and Kamar [19] in the Fayomi fowl.

### Conclusion

The ovarian weight increased non-significantly ( $P \leq 0.05$ ) from day 1 to 16 weeks of age. This would coincide with the first phase of slow follicular growth. However, there was a significant increase in weight of left ovary from 16 weeks to 28 weeks of age. This can be attributed to the deposition of abundant yolk in the hierarchical follicles. Relative ovarian weight gain was non-significant ( $P \leq 0.05$ ) from day 1 to 20 weeks of age and increased significantly between 20-28 weeks of age. The segmentation of ovary started at 4 weeks of age and at 8 weeks, six segments were recognised separated by the sulci. The follicular eruption started at 8 weeks of age in the form of fine granules, small ripened follicles (1-5mm) appeared at 16 weeks of age and yellow hierarchical follicles appeared at 24-28 weeks of age.

### Acknowledgments

I am highly thankful to my advisor Dr. Ishwar Singh Professor Department of Veterinary Anatomy College of Veterinary Sciences G.B.P.U.A.T, Pantnagar for his guidance. I am also thankful to Dr. Rabab Saleem for being side to side during my research work and her ever willingness for help.

### References

- Jacobs M, Bakst MR. Developmental anatomy of the female reproductive tract. In: Reproductive Biology and Phylogeny of Aves, (B. G. M. Jamieson, ed.). USA: Science Publishers. 2007; 6a:149-179.
- Rodler D, Stein K, Korbel R. Observations on the right ovary of birds of prey: A histological and immunohistochemical study Anat. Histol. Embryol. 2015, 44(3):168-177.
- Kumar S, Kumar D. Local Hill fowl of Uttarakhand state. Manager, University press Pantnagar, India. 2007, 1-9.
- Kaur N, Kumar S, Singh B, Pandey AK, Somvanshi SP. Morphological characterization of feathered shank local hill fowl of Central Himalayan Region of India. Indian J Anim Sci. 2010; 80(9):934-936.
- Ibrahim IA, Ahmed AK, Mokhtar DM, Desoky MME. Gross and Microanatomical Studies on the Uterus of Japanese quail (*Coturnix japonica*) During the Post-hatching Period with Special Emphasis on Sperm Host Gland. J Veterinar. Sci. Technol. 2015; 6(6):1-10.
- Gonzalez-Moran MG. Histological and stereological

- changes in growing and regressing chicken ovaries during development. *Anat. Rec.* 2011; 294:893-904.
7. Hodges RD. The reproductive system. In: *The Histology of the Fowl*. Academic Press, London. 1974, 326-408
  8. Sturkie PD. *Avian Physiology*, 4<sup>th</sup> edn. Springer Verlag Publishing, Berlin, 1976, 403-409.
  9. Johnson AL. Reproduction in female. In: *Sturkie's Avian Physiology*. 5<sup>th</sup> edition. Academic Press London, 2000, 569-575.
  10. Shokry DN, Amin ME, Karkoura AA, Alsafy MA, ElGendy SA. Post-Hatching Development of the Chicken Ovary (*Alexandria breed*). *Alexandria Journal for Veterinary Sciences*. 2016; 50(1):57-64.
  11. Nickel R, Schummer A, Seiferle E. *Anatomy of the Domestic Birds* (Translated by W. J. Siller and P.A. L. Wright), Verlag Paul Parey, Berlin, 1977, 75-81.
  12. King AS. The Female Genital organ. In: *The Anatomy of Domestic Animal*. 5<sup>th</sup> edition. W. B. Saunders Company, Philadelphia. 1975, 1935-1958.
  13. Sisson SB, Grossman JD. The female genital organs. In: *The Anatomy of Domestic Animals*. 4<sup>th</sup> edition. W. B. Saunders Company, Philadelphia. 1956, 943-945.
  14. Ingole SP. Late Pre and Posthatch Developmental Studies of Female Reproductive System in Narmada- XL (Dwarf) and Normal WLH Birds. M.V.Sc. Thesis submitted to M.P. Jawaharlal Nehru Krishi Vishwa Vidyalaya, Jabalpur, 1985.
  15. Banerjee A, Ghosh RK, Mondal AK, Kundu B. Gross Anatomical and histomorphological studies on post-natal development of ovary and oviduct in Rhode Island Red Breed of Poultry. *Ind. J Vet. Anat.* 2006; 18(1):1-4.
  16. Prochazkova E, Komarek V. Growth and differentiation of the ovarian follicles in the postnatal development of the chicken. *Acta Vet. Bra.* 1970; 39:11-16.
  17. Dhyaa AA, Al-Saffar FJ. The post hatching development of the female genital system in indigenous mallard duck (*Anas platyrhynchos*). *The Iraqi Journal of Veterinary Medicine*. 2015; 39(2):17-25.
  18. Banerjee A, Mehta S, Guha K, Kumar S. Gross and biometrical studies on the ovary of postnatal developing hen. *Ind. J. Vet. Anat.* 2008; 20(2):62-63.
  19. Hafeez ESE, Kamar GAR. Developmental changes in the reproductive organs of domestic fowl. *Poult. Sci.* 1955; 34:1002-1010.
  20. Dyce KM, Sack WO, Wensing CJG. *Avian Anatomy*. In: *Text book of Veterinary anatomy*. 2<sup>nd</sup> edn. W. B. Saunders Company, Philadelphia, 1996, 830-832.
  21. Deka A, Sarma K, Sarma S, Goswami J, Mahanta JD. Anatomy of ovary of Pati and Chara-Chemballi ducks (*Anas platyrhynchos domesticus*) during laying period. *Journal of Agriculture and Veterinary Science*. 2015; 8(2):33-37.
  22. Johnson AL. Reproduction in female. In: *Sturkie's Avian Physiology*. 5<sup>th</sup> edition. Academic Press London. 2000, 569-575.
  23. Nalbandov AV, James MF. The bloodvascular system of the chicken ovary. *American Journal of Anatomy*. 1949; 85:347-378.
  24. Shyam KL. Studies on gross histomorphology and histochemistry of female genitalia of Aseel and Rhode Island Red fowl. M.V.Sc. Thesis submitted to Indira Gandhi Krishi Vishwavidyalaya, Raipur, 2007.