



E-ISSN: 2320-7078

P-ISSN: 2349-6800

JEZS 2018; 6(3): 1764-1765

© 2018 JEZS

Received: 20-03-2018

Accepted: 21-04-2018

Sakhare MP

Assistant Professor, Dept. of
Veterinary Preventive Medicine,
COVAS, Parbhani, Maharashtra,
India

Digraskar SU

Professor and Head, Dept. of
Veterinary Medicine, COVAS,
Parbhani, Maharashtra, India

Saikia K

M.V.Sc Scholar, Dept. of
Veterinary Preventive Medicine,
COVAS, Parbhani, Maharashtra,
India

Chigure GM

Assistant Professor, Dept. of
Parasitology, COVAS, Parbhani,
Maharashtra, India

Banger SR

M.V.Sc. Scholar, Dept. of
Clinical Veterinary Medicine,
COVAS, Parbhani, Maharashtra,
India

Siddiqui MFMF

Assistant Professor, Dept. of
Clinical Veterinary Medicine,
COVAS, Parbhani, Maharashtra,
India

Correspondence**Saikia K**

M.V.Sc Scholar, Dept. of
Veterinary Preventive Medicine,
COVAS, Parbhani, Maharashtra,
India

Acute microfilariosis in a non-descript cow

Sakhare MP, Digraskar SU, Saikia K, Chigure GM, Banger SR and Siddiqui MFMF

Abstract

A case of an acute microfilariosis with nervous symptoms is reported. A four and half year old non-descript cow with history of complete anorexia, salivation, stiff gait, convulsion since 8-10 days was presented. On clinical examination moderate dehydration, rough hair coat, congested mucous membrane, normal body temperature, increased respiration and heart rate was observed. The blood sample was subjected for wet blood film and haematological examination. Wet blood film and Modified Knott method examination revealed microfilariae of *Setaria spp.* and haematological examination showed decreased Hemoglobin, Packed Cell Volume and Total Erythrocytic Count. On the basis of symptoms and laboratory examination case was confirmed as Microfilariosis. The Cow was successfully treated with three doses of Inj. Ivermectin @ 200µg/kg BW SC at weekly interval. Supportive therapy included non-steroidal anti-inflammatory drug, fluid therapy, antihistaminic and hematinic preparations for five days.

Keywords: Microfilariosis, *Setaria spp.*, non-descript cow, modified Knott method, Ivermectin

1. Introduction

The larval stages of filarid nematodes belonging to the genera *Setaria*, *Onchocerca*, *Stephanofilaria*, *Elaeophora* and *Parafilaria* cause microfilariosis in bovines. Setariosis caused by *Setaria digitata*, a filarid worm, is widely distributed chronic debilitating disease encountered in tropical and subtropical countries including India. The species of *Setaria* commonly found among cattle and buffaloes in India are *S. digitata*, *S. cervi* and *S. labiatopapillosa*, adult worms are commonly found in the peritoneal cavity of these herbivores. Filarid nematodes have been found to cause significant morbidity leading to economic losses by way of reducing the working capacity of draft animals and production performance of milch animals. The microfilaria or first stage larvae circulate in the peripheral blood of the host and cause clinical disease. Mortality has also been reported in severe and untreated cases. In India microfilariosis in bovines has been reported from different parts like Andhra Pradesh, Uttar Pradesh, Orissa, Madhya Pradesh and Tamilnadu [1]. The present case puts on record an acute microfilariosis in a non-descript cow with nervous signs.

2. Materials and Methods

A four and half year old non-descript cow referred to Department of Veterinary Medicine, COVAS, Parbhani with history of complete anorexia, salivation, stiff gait, convulsion since 8-10 days. The owner treated animal locally, however the attempts were futile. Detailed clinical examination revealed moderate dehydration, rough hair coat, congested mucous membrane, normal body temperature, increased respiration and heart rate. The blood sample was subjected for wet blood film and haematological examination. Wet blood film examination revealed 4-5 moving sheathed microfilariae per field. The blood was further examined to Modified Knott's method [8] for morphological identification (Fig.1 and 2). The haematological examination showed decreased Hemoglobin (6.5 gm%), Packed Cell Volume (20%) and Total Erythrocytic Count (4.2x10⁶/µl). On the basis of symptoms and laboratory examination case was diagnosed as Microfilariosis. The Cow was successfully treated with two doses of Inj. Ivermectin @ 200µg/kg BW SC at weekly interval. Supportive therapy included Inj. Meloxicam @ 0.5 mg/kg BW IM, Inj. DNS 2000ml IV, Inj. Feritas @ 5ml IM consecutively for five days.

3. Results and Discussion

The cow responded well to the second dose of Ivermectin in the second week of the treatment, with complete absence of nervous signs and partial improvement in feed intake. The restoration of the feed intake and other physiological parameters were observed after three weeks. *Setaria digitata*, the prevailing species parasitic in cattle and *S. labiato-papillosa* in buffaloes was recorded in Bihar [10]. Cattle and buffaloes affected by setarial microfilariosis display a wide range of clinical signs like fluctuating body temperature, increased pulse and respiration rates, anorexia, inappetance, sudden drop in milk yield, dyspnea, wheezing, watery or mucopurulent nasal and ocular discharge, pale mucous membrane, swelling of dependent parts of the body, general weakness, lameness, incoordination of movements and sometimes complete paralysis of the hindlimbs. Some animals also exhibit nervous signs like striking the head against the wall and constant scratching [4, 6, 9]. In present case salivation, stiff gait, congested mucous membrane, anorexia and ocular and mucopurulent nasal discharge was observed.

While, symptoms like pyrexia with ocular and nasal discharges, sudden drop in milk production, edema of hind limbs, weakness and dehydration was observed in buffaloes [3]. Buffaloes with high density of *S. digitata* in peripheral blood show symptoms of pyrexia, unthriftiness, diarrhoea, agalactia, edema of legs and udder and occasionally accompanied by mortality in untreated cases [5].

Immature forms of *Setaria spp.* are found in the central nervous system of abnormal hosts such as sheep, goats and horses. Neurological disturbances have also been seen in cattle infected with *Setaria spp.* [8] which was observed in the present case. Microfilariae in the brain and spinal cord tissue from typical cases of bovine paraplegia in Mysore was reorded and considered the disease in cattle as cerebro-spinal nematodiasis [1]. Setarial microfilariosis in cattle and buffaloes has been successfully treated by several drugs namely Anthiomaline, Levamisole and Diethyl carbamazine citate. But appreciable results have been obtained with a single dose of Ivermectin and Doramectin at a dose rate of 200µg/kg BW SC [9]. With a single subcutaneous dose of ivermectin @ 200 µg/ kg body weight with oral haematinics administration for 5 days was successfully treated in a cattle affected with microfilariosis [7].

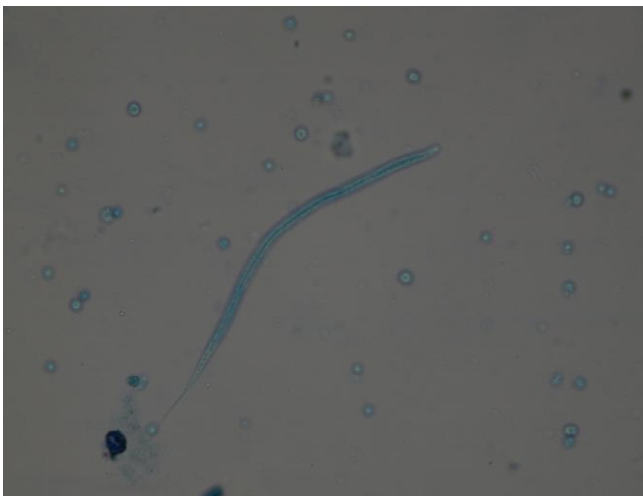

Fig 1: Microfilaria of *Setaria spp.* stained with Methylene blue revealing characteristic morphological features (10/40X)

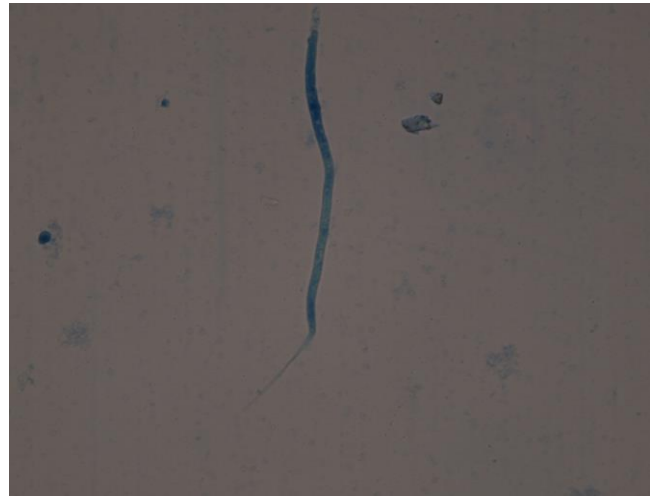


Fig 2: Microfilaria of *Setaria spp.* tapering towards hind end.

4. Conclusion

A non-descript cow affected with acute microfilariosis with nervous symptoms was successfully treated with two injections of Ivermectin.

5. References

1. Lakshmi Rani N, Syaama Sundar N, Jayabal L, Ramadevi V. Microfilariosis associated with epistaxis in a she buffalo. Buffalo Bulletin. 2009; 28(4):171–172.
2. Mohiyudden S. Enzootic bovine paraplegia in some maland tracts (hilly and heavy rainfall region) of Mysore state with particular reference to cerebrospinal nematodiasis as its probable cause. Indian Journal of Veterinary Science. 1956; 26:1-20.
3. Samatha V, Jyothisree Ch, Ramesh Babu K. Epidemiological and diagnostic studies of microfilariosis in buffaloes. J. Parasit Dis. 2016; 40(2):300–302.
4. Sharma SP. Treatment of clinical microfilariosis in buffaloes with ivermectin. Indian Veterinary Journal. 1991; 68:972-974.
5. Shastry GJS, Rao VP, Narasinh MVVL, Rao PK. Animal filariasis in East Godavari district, Andhra Pradesh, Livestock Advisor. 1985; 10:56-60.
6. Singh RK, Sharma SP, Mahesh Kumar Clinico haematological studies in experimental *Setaria digitata* infection in bovine calves. Indian Journal Veterinary Research. 2002; 11:1-7.
7. Singla LD, Moudgil AD, Sood NK, Deshmukh S, Turkar S, Uppal SK. *et al.* A unique case report on *Setaria* species Microfilariosis in adult cattle in Punjab (India). International Science Journal. 2014; 1(2):1-3.
8. Soulsby EJJ, Helminthes. Arthropods and Protozoa of Domesticated Animals.VII edn. ELBS and Baillere Tindall, London, 1982; 316-319.
9. Sunder STB. Prevalence of Setariosis in bovines with emphasis on diagnostic techniques. M.V.Sc. Thesis University of Agricultural Sciences, Bangalore. 2002.
10. Varma AK, Sahai BN, Singh SP, Lakra P, Srivastava VK. On *Setaria digitata* its specific characters, incidence and development in *Aedes vittatus* and *Armigeres obturbans* in India with note on its ectopic occurrence. Z. Parasitenk. 1971; 36:62-72.