



E-ISSN: 2320-7078

P-ISSN: 2349-6800

JEZS 2018; 6(4): 392-394

© 2018 JEZS

Received: 25-05-2018

Accepted: 26-06-2018

J Singh

Scientist, Wildlife Health and Forensic Centre, Chhattisgarh Kamdhenu Vishwavidyalaya, Durg, Chhattisgarh, India

S Mallik

General Secretary, Snake Helpline, Bhubaneswar, Odisha, India

I Nath

Department of Veterinary Surgery & Radiology, College of Veterinary Science & A.H., OUAT-Bhubaneswar, Odisha, India

A Acharya

Department of Veterinary Surgery & Radiology, College of Veterinary Science & A.H., OUAT-Bhubaneswar, Odisha, India

SP Das

Department of Veterinary Surgery & Radiology, College of Veterinary Science & A.H., OUAT-Bhubaneswar, Odisha, India

S Sethi

Department of Veterinary Surgery & Radiology, College of Veterinary Science & A.H., OUAT-Bhubaneswar, Odisha, India

M Sahoo

Department of Veterinary Surgery & Radiology, College of Veterinary Science & A.H., OUAT-Bhubaneswar, Odisha, India

Correspondence

J Singh

Scientist, Wildlife Health and Forensic Centre, Chhattisgarh Kamdhenu Vishwavidyalaya, Durg, Chhattisgarh, India

Infectious stomatitis in an Indian rock python (*Python molurus*) and its therapeutic management

J Singh, S Mallik, I Nath, A Acharya, SP Das, S Sethi and M Sahoo

Abstract

An Indian Rock Python (*Python molurus*) was presented with the history of mucopurulent discharge from the mouth, frothy salivation and anorexia for last 02 weeks. Upon clinical examination, the snake appeared dull with reduced tongue flicking along with necrotic lesions in the oral cavity. Based on the clinical findings, it was tentatively diagnosed as clinical case of infectious stomatitis and treatment was initiated with daily oral application of boroglycerine along with parenteral enrofloxacin at every 72 hours interval. Sterile swabs were collected from various oral lesions for microbiological culture and sensitivity test which revealed the growth of *Salmonella* spp. and the isolates were found to be highly sensitive to enrofloxacin and ciprofloxacin. Hence, the same treatment was continued for 2 weeks which led to complete healing of oral lesions and the animal made an uneventful recovery.

Keywords: Python, stomatitis, salmonella, enrofloxacin

1. Introduction

Two species of python are found in India viz. Indian Rock Python and Burmese python. Indian Rock Python is considered as an endangered species in tropical and subtropical areas of Southern and Southeast Asia with a distribution ranging throughout the Indian subcontinent [1]. The species has been found to inhabit a wide range of habitats, including grasslands, swamps, marshes, rocky foothills, woodlands, scrub forest and river valleys [2]. The feeding habit is generally omnivorous in free ranging conditions with their diet being mostly restricted to small reptiles, birds, smaller mammals and antelopes; but it can be entirely carnivorous in captivity [3,4]. The present communication puts on record a clinical case of infectious stomatitis in an Indian Rock python and its successful therapeutic management.

2. Materials and Methods

An Indian Rock Python was presented with the history of foul smelling mucopurulent discharge from mouth, excessive frothy salivation and anorexia for last 02 weeks. Clinical examination revealed snake to be dull with reduced tongue flicking. Close examination of oral cavity revealed presence of yellowish white caseous lesions along with varying degree of necrotic lesions in the oral cavity (Fig. 1). The clinical findings gave an insight of the python to be affected with clinical condition of infectious stomatitis. The treatment was initiated with oral application of boroglycerine twice daily along with parenteral enrofloxacin administered @ 10mg/kg IM at every 72 hours interval. Oral administration of Vitamin A and C tablets was supplemented on alternate day for 02 weeks.

3. Results and discussion

Sterile swabs were collected from necrotic areas as well as other parts of the oral cavity which were subjected for microbial isolation and antibiotic sensitivity. Growth of gram negative bacilli (Fig. 2) which produced colourless colonies on Mac Conkey agar and pink colonies on Brilliant Green Agar (Fig. 3) was observed. Isolate revealed IMVic pattern (- + - +), which confirmed *Salmonella* to be the causative agent. Antibiotic sensitivity revealed high sensitivity of isolates to enrofloxacin and ciprofloxacin. Hence, the same treatment was advised to be continued for 2 weeks. The necrotic lesions inside oral cavity completely healed within fortnight and the python made an uneventful recovery (Fig. 4).

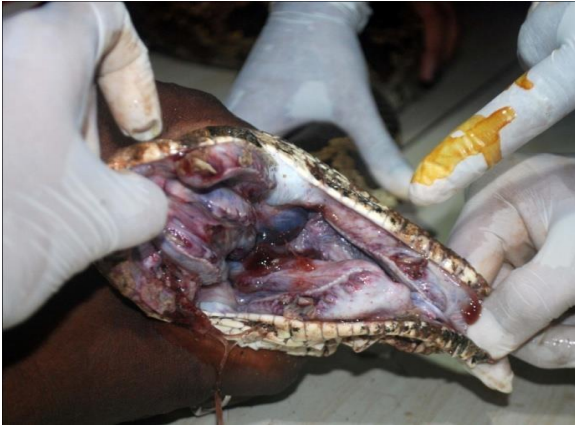

Fig 1: Mucopurulent discharge along with necrotic lesions in oral cavity

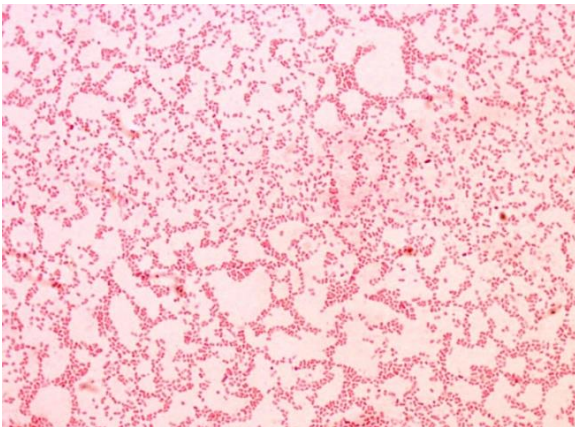


Fig 2: Gram-negative rod-shaped (bacillus)

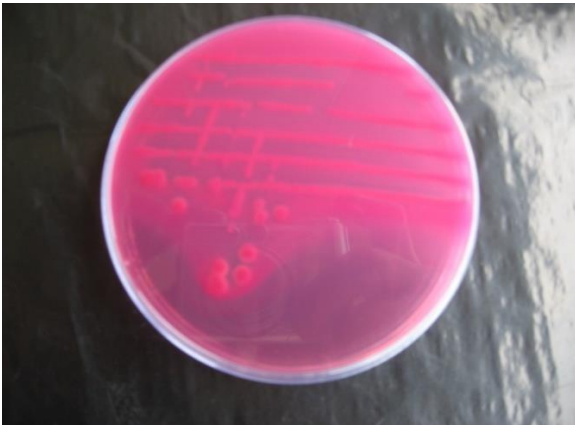

Fig 3: Pink colonies on Brilliant green agar

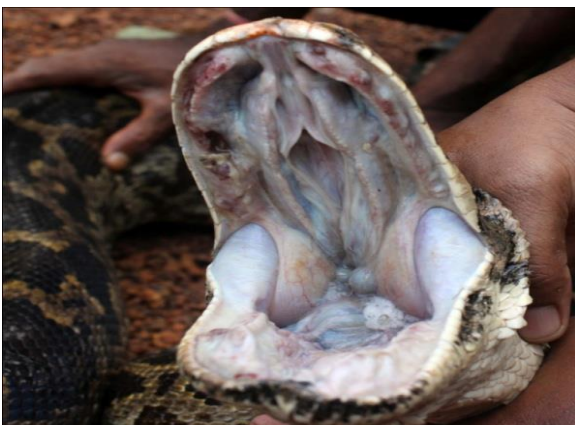

Fig 4: Fully healed oral lesions after completion of treatment

Infectious stomatitis has been reported in various species of reptiles with snakes being most commonly affected. The clinical signs associated with infectious stomatitis are often variable which include anorexia, excessive salivation, open mouth breathing, weight loss and caseous exudation from the oral cavity. Respiratory or GI infection may develop in poorly managed cases. Prolonged cases of infectious stomatitis can lead to systemic disease and possible death [5, 6]. The lining of the oral cavity may get eroded and often develops a "cottage cheese" appearance which is yellow or whitish-gray in colour. In severe cases, it appears like that mouth is rotting away, hence the name- mouth rot. In areas of deep ulceration and necrosis, a blood clot may form that is loaded with bacteria which when released into the bloodstream leads to septicemia [7].

Any of these stresses suppress the immune system of the reptile and make it much more susceptible to infections. Many pathogens can cause infectious stomatitis including bacteria, viruses and fungi. *Aeromonas* is among the bacteria implicated as the classical causative agent of infectious stomatitis [8]. Several others like *Pseudomonas*, *Salmonella*, *Klebsiella*, and *Mycobacterium* have also been listed as the causative agents for mouth rot in snakes. *Aeromonas* and *Pseudomonas* spp, common oral inhabitants, are most frequently isolated, along with a variety of other gram-negative and gram-positive bacteria [7].

Surgical debridement, application of antiseptics, systemic antibiotics and supportive therapy has been implicated for treatment of this condition. In severe cases with ulceration or granuloma formation, aggressive surgery may also be needed. Supplementation of Vitamin A and C has also been advocated for early recovery [9]. Early diagnosis of mouth rot and administration of antibiotic therapy is essential to prevent systemic disturbances and fatality [10]. In most cases, antibiotic therapy is best administered via intramuscular injection or directly into the affected areas. Successful topical treatment via application of sodium sulfamethazine [11], silver vitellin [12] and various tetracyclines [13] has also been reported. However, successful application of methylene blue (MB)-mediated antimicrobial photodynamic therapy has also been reported to successfully heal infectious stomatitis in snakes [14].

4. Conclusion

The present study puts on record a clinical case of infectious stomatitis caused by *Salmonella* spp. in an Indian Rock python and its successful therapeutic management using oral boroglycerine and parenteral enrofloxacin for 2 weeks.

5. Acknowledgement

Authors are thankful to Shri Akshaya Pattnaik, Divisional Forest Officer, Khurda division for providing necessary facilities at Ketkijhar Nursery, Khurda during treatment of this snake. Authors also convey thanks to Mr. Amit Mohanty and Soumya Mohanty, Snake Helpline members for their assistance in restraint and treatment.

6. References

1. O'Malley B. Clinical Anatomy and Physiology of exotic species. Edn 1, Elsevier Saunders Co., Philadelphia, 2005, 421-424.
2. Whitaker R and Captain A. Snakes of India, The field guide. Draco Books, Chennai, India, 2004, 3-81.
3. Bogat CM. The encyclopedia Americanus, New York,

- International Edn, Americana Corporation, New York, 1974, 102-107.
4. Grzimek BHC. Grzimek's animal life encyclopedia. Reptiles. VNR Company, New York, 1975, 428-430.
 5. Frye F. Reptile care: An atlas of diseases and treatments. Vol.1. T.F.H. Publications, New Jersey, 1991, 72-74.
 6. Divers SJ. Bacterial Diseases of Reptiles. MSD Veterinary Manual. Edn 11, Merck & Co., Kenilworth, USA, 2016. 206-208.
 7. Mader D. Reptile Medicine and Surgery. Edn. 1, W.B. Saunders Company, Philadelphia, 1996, 564-569.
 8. Reavil D. Selected topics in Reptile clinical pathology. U.C. Davis Avian/ Exotic Animal Symposium, California, USA, 2005, 1-12.
 9. Rani BK, Naik SG, Ananda KJ, Shambulingappa BE, Patel SR and Devaraj M. Necrotic stomatitis and hemorrhagic enteritis in an Indian Rock python. Eurasian Journal of Veterinary Science. 2012; 28(1): 60-63.
 10. Kauffeld C. New treatment of mouth rot in snakes. Herpetologica. 1953; 9: 132.
 11. Hunt TJ. A note on the use of silver vitellin in the treatment of reptilian diseases. British Journal of Herpetology. 1957; 2:87-88.
 12. Rothman N and Rothman B. Course and cure of respiratory infections in snakes. Bulletin Philadelphia Herpetological Society. 1960; 8:19-23.
 13. Grego KF, de Carvalho MPN, Cunha MPV, Knobl T, Pogliani FC, Catao-Dias JL, Anna SS, Ribeiro MS and Sellera FP. Antimicrobial photodynamic therapy for infectious stomatitis in snakes: Clinical views and microbiological findings. Photodiagnosis and Photodynamic Therapy. 2017; 20:196-200.