



E-ISSN: 2320-7078

P-ISSN: 2349-6800

JEZS 2018; 6(6): 159-162

© 2018 JEZS

Received: 16-09-2018

Accepted: 18-10-2018

S Bhargavi

PG Scholar, Dept. of Veterinary
Anatomy, Madras Veterinary
College, Chennai, Tamil Nadu,
India

TA Kannan

Professor, Centre for Stem Cell
Research and Regenerative
Medicine, Madras Veterinary
College, Chennai, Tamil Nadu,
India

Geetha Ramesh

Professor, Dept. of Veterinary
Anatomy, Madras Veterinary
College, Chennai, Tamil Nadu,
India

D Sumathi

Professor, Department of
Veterinary Clinical Medicine,
Madras Veterinary College,
Chennai, Tamil Nadu, India

A Arun Prasad

Professor, Dept. of Veterinary
Surgery and Radiology, Madras
Veterinary College, Chennai,
Tamil Nadu, India

Correspondence**S Bhargavi**

PG Scholar, Dept. of Veterinary
Anatomy, Madras Veterinary
College, Chennai, Tamil Nadu,
India

Radiographic evaluation of caudal vena cava and descending aorta in indigenous dog breeds of Tamil Nadu

S Bhargavi, TA Kannan, Geetha Ramesh, D Sumathi and A Arun Prasad

Abstract

Various cardiovascular diseases led to enlarged right side of the heart which resulted in the enlargement of caudal vena cava (CVC). CVC size could be best studied by evaluating the CVC/AOD ratio. Rajapalayam and Chippiparai dogs are the important indigenous breeds of Tamil Nadu. The present study was designed to develop basic data on the diameter of caudal vena cava and descending aorta in these indigenous breeds using Radiography. The study was carried out in young (1-6 months) and adult (> 6 months) dogs. In the present study, mean \pm SE of CVC/AOD were found to be 0.87 ± 0.0 and 0.93 ± 0.04 ; 0.77 ± 0.06 and 0.92 ± 0.03 in young and adult age group of Rajapalayam and Chippiparai dogs respectively. The study indicated that body weight didn't have an influence on CVC/AOD ratio.

Keywords: Caudal vena cava, Descending Aorta, Radiograph, Rajapalayam, Chippiparai

1. Introduction

Dilation of the caudal vena cava (CVC) on lateral radiographs of the thorax is often used as interpretation of right-sided congestive heart failure in dogs. Hence the diameter of caudal vena cava and descending aorta is used as an indicator in diagnosis of Right-sided cardiac disorders such as congestive heart failure, heart worms and lesion in the right atrium [1]. There are variations exist between the different breeds of dogs. VHS reference ranges for dogs and cats in general have already been documented. Breed specific data is not available yet.

India is a beautiful country with rich canine genetic resources. Indigenous dog breeds such as Rajapalayam, Chippiparai, Mudhol hound, Rampur hound, Caravan hound, Banjara hound and Jonangi are well known. Of which, Rajapalayam and Chippiparai dogs are the important indigenous breeds of Tamil Nadu. The breeding tract of these dogs were reported to be Virudhunagar and Tirunelveli districts of southern Tamil Nadu respectively [2, 3].

Hence, the present study was designed to develop the basic data on diameter of caudal vena cava and descending aorta in Rajapalayam and Chippiparai breeds using Digital Radiography.

2. Materials and Methods

The study was carried out on 24 clinically healthy Rajapalayam and Chippiparai breeds of dogs brought to Madras Veterinary College teaching hospital with the consent of the owner (n=12 each). The dogs were divided into two groups based on age as a young / puppy (from 1 to 6 months) and adult (6 months and above). Each group consisted of six animals. The radiographic examination included right-to-left and left-to-right lateral thoracic radiographs from non-sedated animals.

During radiography, care was taken to avoid movement of the animal so that the shape and size of the cardiac silhouette was not deviated from normal [4]. Radiographic images were obtained by using Siemens 500 mA, 3 phase, 6 pulse X-ray generator. Digital processing of the images was carried out using Computerised radiography AGFA 30-X using the standard exposure technique based on the chest depth of the animal.

Radiography was performed without sedating the dogs, using the standard exposure techniques based on the chest depth of the animal. Left lateral and right lateral radiographic views of thorax were obtained with a digital radiography plate. Radiographic images obtained were stored for future reference. While radiography, care was taken to avoid movement of the animal so that the shape and size of the cardiac silhouette was not deviated from normal. The Caudal Vena Cava (CVC) was visible on the thoracic radiographs as it courses from the

abdominal cavity to the thoracic cavity into the right atrium [1].

The following measurements were made from the left lateral view of the thoracic radiographs in each dog as per Lehmkuhl *et al.* [1].

1. The greatest diameter of CVC not overlapping the heart or diaphragm
2. Diameter of the descending aorta (AOD) at the same intercostal space where the CVC measurement was taken.

Based on this CVC to AOD ratio was calculated.

3. Results and Discussion

Cardiovascular diseases such as congestive heart failure, pericardial heart disease, heart worms and lesion in the right atrium led to enlarged right side of the heart which resulted in the enlargement of caudal vena cava (CVC). CVC size could be best studied by evaluating the CVC/AOD ratio [5].

Caudal vena cava (CVC) was observed on the lateral thoracic radiographs as it entered from the abdominal cavity into the right atrium [6].

Lehmkuhl *et al.* [1] quantitated the clinical utility of evaluation of CVC size as an indicator of right sided heart disease. The CVC diameter in normal dogs were found to be 1.47 ± 0.40 cm and the diameter of descending aorta (AOD) was 1.46 ± 0.39 cm. Larger CVC diameter could be interpreted as suggestive of right-sided congestive heart failure.

Cardiovascular diseases such as congestive heart failure, pericardial heart disease, heart worms and lesion in the right atrium led to enlarged right side of the heart which resulted in the enlargement of caudal vena cava (CVC). CVC size could be best studied by evaluating the CVC/AOD ratio [5].

In the present study, Mean \pm SE diameters of the caudal vena cava and descending aorta were measured using left lateral radiographs in both Rajapalayam (Table-1 and Figure 1, 2) and Chippiparai dogs (Table-2 and Figure 3, 4). Based on these values, CVC/AOD ratio was calculated.

In Rajapalayam dogs, mean \pm SE of CVC/AOD were found to be 0.87 ± 0.0 and 0.93 ± 0.04 in young and adult dogs respectively which is within the normal reference value of upto 1.50 in dogs as reported by Lehmkuhl *et al.* [1]. The result indicated that the dogs used for the study were free from right atrial disease.

Statistical analysis revealed no significant difference between age groups studied and no relation was observed with regard to body weight.

In Chippiparai dogs, mean \pm SE of CVC/AOD were found to be 0.77 ± 0.06 and 0.92 ± 0.03 in young and adult dogs respectively. This is in accordance with the findings of Vosugh and Nazem [5] in domestic short hair cat (0.77 ± 0.02). Statistical analysis revealed a significant difference between age groups studied and no relation was observed with body weight.

Table 1: Mean \pm SE of cardiac measurements in left lateral views of Rajapalayam dogs

Parameters	Mean \pm SE		t value
	Young	Adult	
CVC	10.98 ± 0.1	15.12 ± 0.59	6.88**
AO	12.58 ± 0.05	16.30 ± 0.47	7.83**
CVC/AO	0.87 ± 0.0	0.93 ± 0.04	1.39 ^{NS}

^{NS} - No significant difference between young and adult age groups ($P > 0.05$)

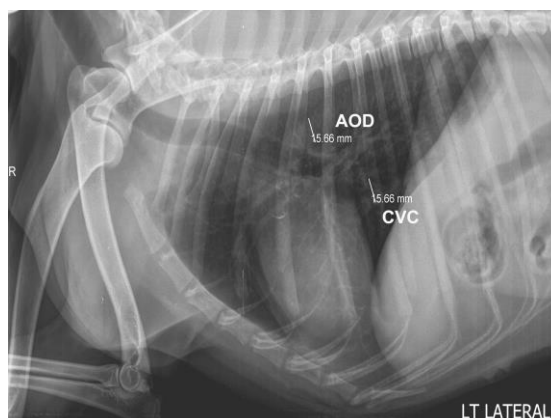
** - Significant difference between young and adult age groups ($P < 0.01$)

Table 2: Mean \pm SE of cardiac measurements in left lateral views of Chippiparai dogs

Parameters	Mean \pm SE		t value
	Young	Adult	
CVC	8.76 ± 0.78	15.63 ± 0.67	6.71**
AO	11.43 ± 0.92	17.06 ± 0.91	4.36**
CVC/AO	0.77 ± 0.06	0.92 ± 0.03	2.26*

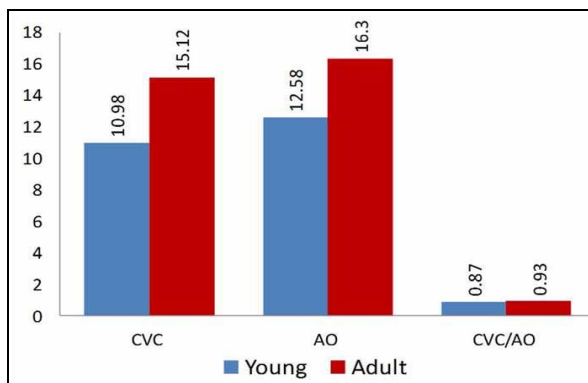
* - Significant difference between young and adult age groups ($P < 0.05$)

** - Significant difference between young and adult age groups ($P < 0.01$)



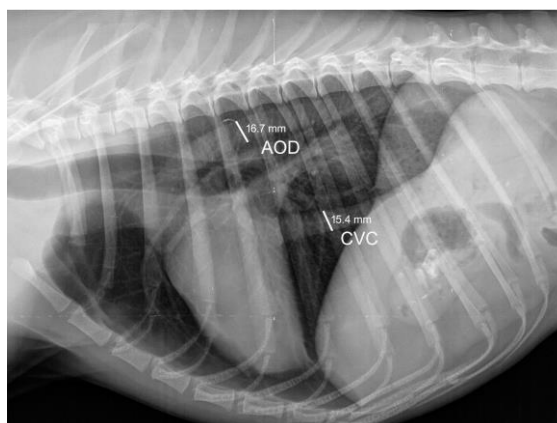CVC - Caudal Vena Cava AOD - Descending Aorta

Fig 1: Left lateral Radiographs of Rajapalayam dog showing CVC and AOD measurements



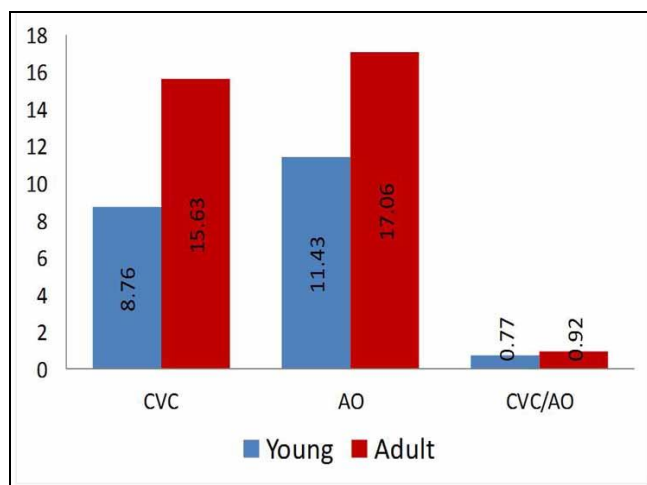
X axis denotes Cardiac measurements, Y axis denotes values

Fig 2: Graphical representation of Mean ± SE of cardiac measurements in Rajapalayam dogs



CVC- Caudal Vena Cava AOD – Descending Aorta

Fig 3: Left lateral Radiographs of Chippiparai dog showing CVC and AOD measurements



X axis denotes Cardiac measurements, Y axis denotes values

Fig 4: Graphical representation of Mean ± SE of cardiac measurements in Chippiparai dogs

4. Conclusion

The current study provided the reference data for the diameter of the caudal vena cava and descending aorta in Rajapalayam and Chippiparai, the indigenous sight hound dog breeds of Tamil Nadu. In Rajapalayam breed, age did not have any influence on CVC/AOD ratio, whereas, in Chippiparai breed, as age advances the CVC/AOD ratio altered. However, the values were within the normal reference range for other dog breeds. In conclusion, it was found that the diameter of the caudal vena cava and descending aorta from a lateral radiograph of thorax could be used in the diagnosis of right sided cardiac disorders in dogs.

5. Acknowledgement

The author acknowledges the Dean, Madras Veterinary College and Director of Clinics, Tamil Nadu Veterinary and Animal Sciences University, Chennai for providing necessary facilities to carry out the research work.

6. References

1. Marin LM, Brown J, McBrien C. Vertebral heart size in retired racing Greyhounds. *Veterinary Radiology & Ultrasound*. 2007; 48:332-334.
2. Srinivasan SR. Present status of dog genetic resources of Tamil Nadu. In: *Workshop Manual on Conservation of*

- Animal Genetic Resources of Tamil Nadu, organized by TANUVAS at Chennai, Tamil Nadu, 2011, 41-50.
3. Karthickeyan SMK, Ravimurugan T, Hisham A, Sivaselvam SN. Chippiparai breed of dogs in Tamil Nadu: an assessment of physical and performance characteristics. *Indian Journal of Science and Biotechnology*. 2015; 10(3):45-49.
 4. Bavegems V, Van Caelenberg A, Duchateau L, Sys SU, Van Bree H, De Rick A. Vertebral heart size ranges specific for whippets. *Veterinary Radiology & Ultrasound*. 2005; 46(5):400-403.
 5. Vosugh D, Nazem MN. Radiological evaluation of caudal vena cava in domestic shorthair cats with regard to right heart failure diagnosis. *Bulgarian Journal of Veterinary Medicine*, 2017, 1311-1477.
 6. Wyburn RS, Lawson DD. Simple radiography as an aid to the diagnosis of heart disease in the dog. *Journal of Small Animal Practice*. 1967; 8:163-170.