



E-ISSN: 2320-7078

P-ISSN: 2349-6800

JEZS 2018; 6(6): 414-417

© 2018 JEZS

Received: 20-09-2018

Accepted: 21-10-2018

Renu Yadav

M. V. Sc. Scholar, Department of Veterinary Anatomy, College of Veterinary Science and Animal Husbandry, DUVASU, Mathura, Uttar Pradesh, India

Ajay Prakash

Professor, Department of Veterinary Anatomy, College of Veterinary Science and Animal Husbandry, DUVASU, Mathura, Uttar Pradesh, India

MM Farooqui

Professor and Head, Department of Veterinary Anatomy, College of Veterinary Science and Animal Husbandry, DUVASU, Mathura, Uttar Pradesh, India

SP Singh

Assistant Professor, Department of Veterinary Anatomy, College of Veterinary Science and Animal Husbandry, DUVASU, Mathura, Uttar Pradesh, India

Abhinov Verma

Assistant Professor, Department of Veterinary Anatomy, College of Veterinary Science and Animal Husbandry, DUVASU, Mathura, Uttar Pradesh, India

Amit Vishen

M. V. Sc. Scholar, Department of Veterinary Anatomy, College of Veterinary Science and Animal Husbandry, DUVASU, Mathura, Uttar Pradesh, India

Correspondence

Renu Yadav

M. V. Sc. Scholar, Department of Veterinary Anatomy, College of Veterinary Science and Animal Husbandry, DUVASU, Mathura, Uttar Pradesh, India

Histology of endocrine pancreas in the chabro chicken

Renu Yadav, Ajay Prakash, MM Farooqui, SP Singh, Abhinov Verma and Amit Vishen

Abstract

Present study was conducted on the endocrine part of pancreas of twenty four apparently healthy chabro chickens irrespective of sex. The birds were divided into 0 day, 30 days, 60 days and 150 days age groups. Islets of Langerhans in chabro chicken were usually oval and rounded in shape but some of these were also irregular, quadrilateral and elongated. Their occurrence was relatively much higher in splenic lobe. Some developing islets had a cluster of acinar and islets cells. Fully developed islets were beta and mixed types. Beta islets were formed by the clusters of oval, triangular, irregular, elongated and polyhedral beta cells. Mixed islets consisted of beta and alpha cells and were found only in splenic lobe. The alpha cells were spherical, elongated and irregular in shape and appeared relatively smaller than beta cells. The capillaries were commonly observed inside islets which, sometimes, formed dilated sinus like structures.

Keywords: Histology, pancreas, Chabro chicken

Introduction

Chabro chicken is a rural meat type bird of India and is a cross breed of Barred Plymouth Rock and red Cornish birds. The pancreas has a distinct endocrine function to secrete hormones, the insulin and glucagon [5, 7]. The endocrine part of the pancreas (islets of Langerhans) contain alpha and beta cells located in separate islets in domestic animals [8]. The beta or B cells of pancreatic islets secrete insulin that functions to increase glucose uptake by muscles, liver and adipose tissue and also enhances the lipogenesis. The pancreatic islet alpha or A cells secrete glucagon which causes lipolysis in adipose tissue, decrease in muscles and liver glycogen, decrease in glucose utilization, increase in gluconeogenesis and decrease in lipogenesis [17]. Hence, Insulin and glucagon play critical role in glucose homeostasis and serve as acute regulators of blood glucose level. On perusal of literature it has been observed that little emphasis has been given on the histology of endocrine part of chicken pancreas particularly in its chabro breed. Hence, the present work has been conducted.

Materials and Methods

For the present study the pancreas was collected from twenty four apparently healthy chabro chicken irrespective of sex. The birds were procured at the time of hatching and were grown up to the prescribed age. These were divided in to four age groups i.e. 0, 30, 60 and 150 days after hatching; each group contained six chickens. Small pieces of tissue from each lobes of the pancreas were fixed in 10% neutral buffered formalin and were processed by a routine paraffin embedding technique [12]. Five to six microns thick paraffin sections were obtained and were stained by following staining procedures-

1. Hematoxylin and Eosin stain (Luna, 1968) - For general histoarchitectural study
2. Gordon and Sweet's method for reticulin (Bancroft and Stevens, 1977) - For reticular fibers
3. Masson's Trichrome method (Luna, 1968) - For collagen fibers
4. Verhoeff's method for elastic fibers (Bancroft and Stevens, 1977) - for elastic fibers
5. Gomori's method for pancreatic islets (Luna, 1968) - For alpha and beta cells

The micrometrical studies were conducted with the help of calibrated computerized image analyzer. The data generated by the histological observations was subject to statistical analysis to one way ANOVA for various parameters and for the test of significance with age [21].

Results and Discussion

The endocrine part or islets of Langerhans constituted only a small portion of the parenchyma in the pancreas in chabro chicken [3] in fowls also reported similar fact about the endocrine part of the pancreatic parenchyma. The islets of langerhans in the present study were in the form of small lightly stained pale areas between the acini (Fig. 1). Several islets were in the form of discrete units dispersed between the acini but many others were as developing islets formed by a cluster of acinar and islets cells; these appeared to be formed by the detached cells of the exocrine acini (Fig. 3). The islets varied in shape as many of these were oval and rounded while many others were irregular, elongated and quadrilateral in shape (Fig. 3). The shape of islets was roughly spherical in fowl [3], round or irregular in falcon [18], irregular in red jungle fowl [11] and oval or circular in golden eagle [1]. The occurrence of islets was relatively much higher in splenic lobe than the dorsal and ventral lobes (Fig. 1). According to [20] in coturnix quails, [23] in chickens and [14] in native chicken the islets were more frequently observed in splenic and third lobes.

In the present study the islets varied considerably in size. They were generally smaller in ventral lobe and larger in splenic lobe. The average diameter of oval and rounded islets in the pancreas of chabro chicken was $33.05 \pm 2.84 \mu\text{m}$ (Table -2). In dorsal, ventral and splenic lobe the average diameter of these islets was $41.42 \pm 2.77 \mu\text{m}$, $35.89 \pm 2.44 \mu\text{m}$ and $54.87 \pm 3.31 \mu\text{m}$, respectively (Table -2). The average size of the islets gradually increased from group 1 to group 4. In group-1 and group- 4 average diameter of oval and rounded islets was $33.58 \pm 3.83 \mu\text{m}$ and $52.02 \pm 6.25 \mu\text{m}$, respectively (Table -1). The size of the islets in various lobes gradually increased from group 1 to group 4. The statistical analysis of the data revealed that the increase in the diameter of islets was nonsignificant among the various groups of the present study. Similarly the increase in diameter of islets in dorsal and ventral lobes was also statistically non-significant but in the splenic lobe the increase in diameter of islets was statistically significant from group 1 to group 2. The islets were randomly distributed among the exocrine part of all the lobes as mentioned by [10] in common gull and guinea fowl but at some places, particularly in the splenic lobes, these were more concentrated in the central part than the peripheral part of the parenchyma where they often constituted the large central mass of endocrine tissue.

Most islets of Langerhans in the pancreas of chabro chicken were formed by the clustures of light colored oval, triangular, irregular, elongated and polyhedral cells, however, in splenic lobe some of these had dark and light cells (Fig. 2). Hence, two types of the islets were found in the present study viz. the were light islets formed by light cells and mixed islets which

had both light and dark cells. The occurrence of light islets was much higher than the mixed islets. Moreover, the beta islets were found in all the lobes but mixed islets were present only in splenic lobe [3] in duck and [13] in goose observed dark, light and mixed islets in avian pancreas. The light islets in the pancreas of chabro chicken could be referred as beta islets as reported by [14] in native chicken, [18] in falcon and [13] in goose. Most islets in all lobes of the pancreas were formed by the beta cells [20] in coturnix quails, [15] in chick and [9] in goose. Mixed islets were seen in Japanese quail [19] and pigeon [6]. The light or beta cells were relatively larger and had light eosinophilic relatively scanty cytoplasm (Fig. 2, 3, 4). These either had centrally placed or eccentric large vesicular nuclei with one or two nucleolus. Many of these cells lay very close to each other and overlapped, hence, often appeared multinucleated in the light microscope. Usually these were irregularly distributed within islets at some these were arranged linearly. The dark cells or alpha cells were spherical, elongated and irregular in shape and appeared relatively smaller than beta cells. These had dark eosinophilic cytoplasm with spherical and oval vesicular nuclei (Fig. 2) [10]. Observed that the alpha and beta cells were round to oval with prominent nucleolus in common gull and guinea fowl [6]. Observed in pigeons the beta cells of mixed islets were arranged in the form of cords or as irregular rows of polygonal cells. According to [11] in red jungle fowl and [1] in golden eagle the islets of Langerhans had smaller alpha cells and larger beta cells with dark large central nucleus. The islets having delta cells as well as the alpha cells were not found in the pancreas of chabro chicken [22] in ostrich, [13] in goose and [10] in common gull and guinea fowl the delta cells could not be observed. In present study beta cells as these stained blue while in alpha cells pink stained with Gomori's method for pancreatic islets cells (fig. 6).

Separate capsule around the islets was not observed in chabro chicken, however reticular fibers which encircled the adjacent acini formed almost continuous lining around the islets. According to [16] in mynah, [6] in pigeon, [10] in common gull and guinea fowl and [2] in early hatched goose the islets had no distinct border with the exocrine part. The developing and developed islets of present work had a rich vascular supply formed by the capillaries on their periphery which often encircled 1/3rd to 2/3rd part of the islets (Fig. 3, 4). The capillaries were also commonly observed inside islets, which sometimes formed dilated sinus like structures (Fig. 4) [9, 13] in goose, [22] in ostrich, [16] in mynah, [6] in pigeon and [10] in common gull and guinea fowl noticed that the islets had a very rich supply of blood capillaries. Moreover according to [3] in fowl the cells of islets were sharply defined from the serous acini by a very vascular areolar tissue and the anastomosing cell cords had wide blood vessels between them.

Table 1: Group wise values (Mean \pm SE) along with range of various micrometric parameters of dorsal, ventral and splenic lobes in pancreas of chabro chicken.

Parameters	Group 1	Group 2	Group 3	Group 4
Islets of Langerhans diameter (in μm) dorsal lobe	33.65 ± 4.38^a (14.76 -57.12)	37.38 ± 5.95^a (17.83 -77.79)	45.18 ± 5.44^a (20.59 -72.79)	49.50 ± 5.66^a (24.29 -75.65)
Islets of Langerhans diameter (in μm) ventral lobe	30.61 ± 3.13^a (20.93 -54.82)	34.82 ± 3.92^a (15.90 -54.85)	38.77 ± 5.75^a (10.92 -69.85)	40.75 ± 5.8^a (19.92 - 76.85)
Islets of Langerhans diameter (in μm) splenic lobe	36.50 ± 3.97^a (16.62 -56.35)	56.25 ± 5.40^b (18.53 - 76.79)	60.87 ± 6.00^b (28.62 - 89.39)	65.86 ± 7.30^b (28.62 - 98.25)
Average diameter of islets Langerhans (in μm)	33.58 ± 3.83^a	42.82 ± 5.05^{ab}	48.27 ± 5.73^b	52.02 ± 6.25^b

Note:

1. Values in parentheses indicate ranges.

2. Different superscript shows significant change in values and similar superscript shows non significant change in values between the groups.

Table 2: Values (Mean ± SE) of various micrometric parameters in the pancreas of chabro chicken along with the value in dorsal, ventral and splenic lobes.

Parameters	Dorsal lobe	Ventral lobe	Splenic lobe	Entire study
Islet mass diameter (in μm)	41.42 ± 2.77 (14.76 - 77.79)	35.89 ± 2.44 (10.92 - 76.44)	54.87 ± 3.31 (16.62 - 98.25)	33.05 ± 2.84 (10.92 - 98.25)

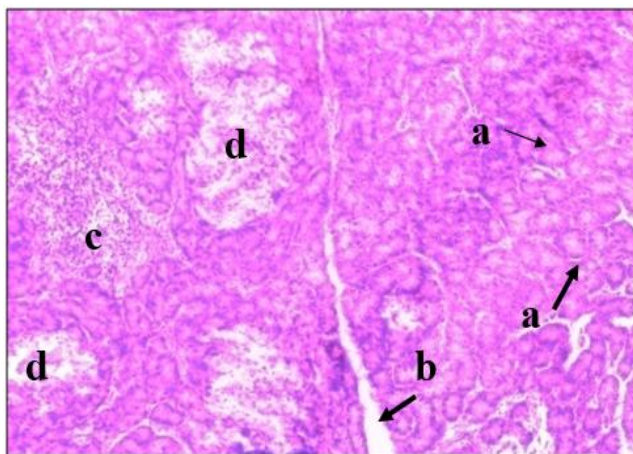


Fig 1: Photomicrograph of splenic lobe of pancreas in 60 days old chabro chicken showing acini (a), interlobular septum (b), lymphatic aggregation (c) and islets of Langerhans (d). H&E; X100

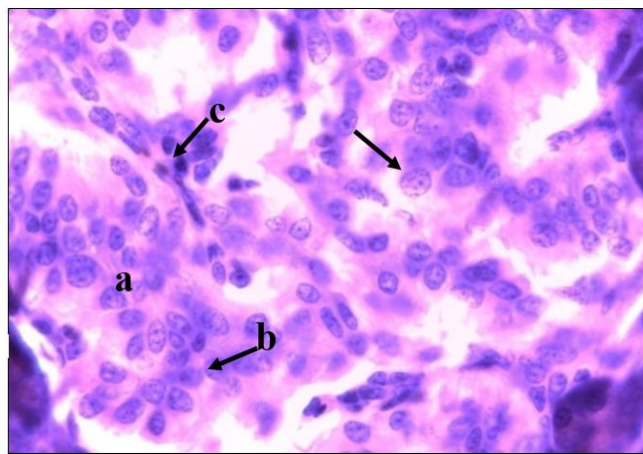


Fig 4: Photomicrograph of ventral lobe of pancreas in 60 days old chabro chicken showing light (beta) islets (a), beta cells of islets (b), nuclei of islets cells (arrow) and blood capillaries inside (c). H&E; X1000

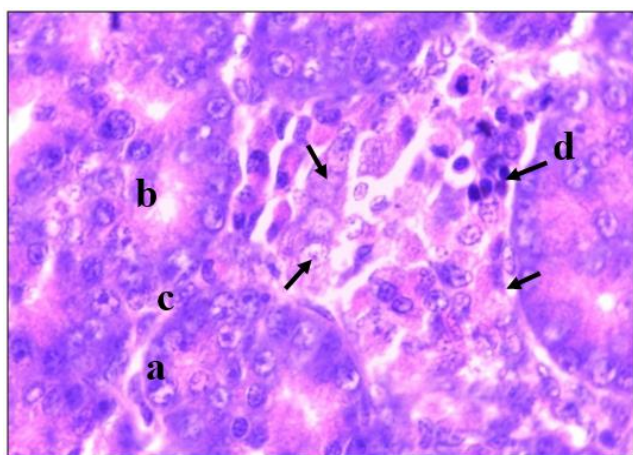


Fig 2: Photomicrograph of splenic lobe of pancreas in 0 day old chabro chicken showing acini (a), lumen of acini (b), light cells of islets of langerhans (c) and dark color cell of islets of langerhans (d). H&E; X1000

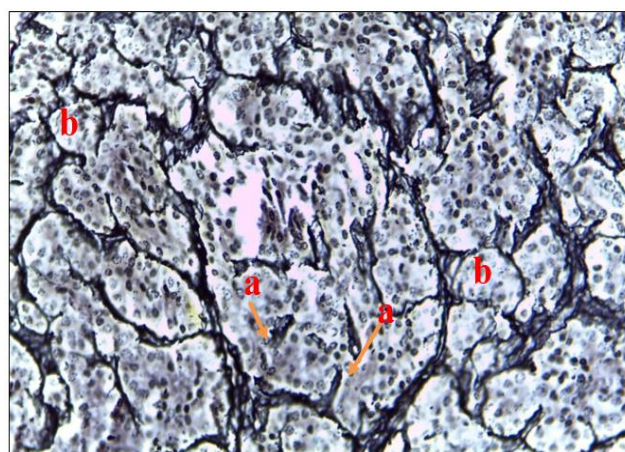


Fig 5: Photomicrograph of ventral lobe of pancreas in 60 days old chabro chicken showing reticular fibers inside islets of langerhans (a) and around the acini (b). Gordon and Sweet's Method; X400

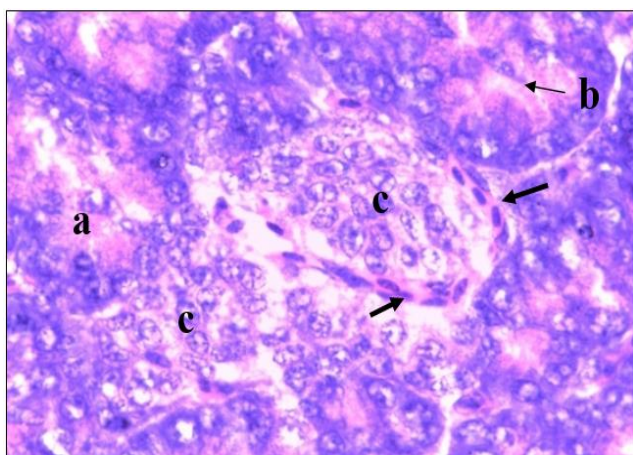


Fig 3: Photomicrograph of dorsal lobe of pancreas in 0 day old chabro chicken showing acini (a), lumen of acini (b) and islets of Langerhans (c) partially encircled by capillaries (arrow). H&E; X1000

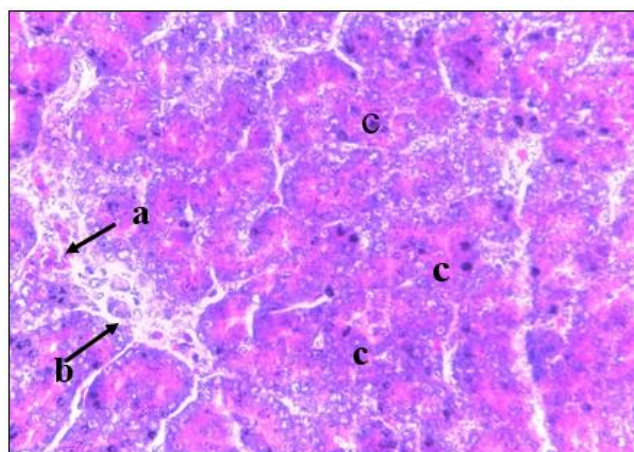


Fig 6: Photomicrograph of splenic lobe of pancreas in 0 day old chabro chicken showing pink colour alpha cells (a) and blue colour beta cells (b) in the mixed islets. Several exocrine acini (c) are also visible. Gomori's Method for Pancreatic Islets; X400

Conclusion

Islets of Langerhans in chabro chicken were usually oval and rounded in shape but some of these were also irregular, quadrilateral and elongated. Their occurrence was relatively much higher in splenic lobe. Some developing islets had a cluster of acinar and islets cells. Fully developed islets were beta and mixed types. Mixed islets consisted of beta and alpha cells and were found only in splenic lobe. Apha cells appeared relatively smaller than beta cells. The capillaries were commonly observed inside islets which, sometimes, formed dilated sinus like structures.

Reference

1. Al-Agele RAA, Mohammed FS. Architecture Morphology and Histological Investigations of Pancreas in Golden Eagles. Al - Anbar Journal veterinary Science. 2012; 5(2):149-155.
2. Al-Sharoot HA. Anatomical, histological and histochemical architecture of pancreases in early hatched goose (*Anser anser*). Kufa Journal of Veterinary Medical Science. 2016; 7(1):147-153.
3. Bradley OC, Grahame T. The Structure of the Fowl. Edn 4, Oliver and boyd, Edinburgh, London. 1960, 75-81.
4. Das A, Das RK, Parida S, Mishra UK, Solanki D. Histomorphological study on pancreas of duck (*Anas boscas*). Indian Journal of Animal Science. 2003; 73(6):598-599.
5. Denbow DM. Gastrointestinal Anatomy and Physiology. Sturkie's Avian Physiology. Edn 5, Academic Press, San Diego, 299-325.
6. Faris SA. Anatomical and Histological study of the Pancreas of Pigeon. Journal of College of Education. 2012; 2(4):64-72.
7. Frandson RD, Wilke WL, Fails AD. Anatomy and Physiology of Farm Animals. Edn 7, Wiley-Blackwell publishing Ch. 2009; 20:356-359.
8. Getty R. The anatomy of the domestic animals. Edn 5, W.B. saunders company Philadelphia. 1975, 1876-1878.
9. Gulmez N. Are glands present in goose pancreatic ducts? A light microscope study. Jop. 2003; 4(3):125-128.
10. Hamodi HM, Abed AA, Ameer MT. Comparative anatomical, histological and histochemical study of the pancreas in two species of birds. Research and reviews in Bioscience. 2013; 8(1):26-34.
11. Kadhim KK, Zuki AB, Noordin MM, Babjee SM, Zamri SM. Morphological Study of pancreatic duct in red Jungle fowl. African Journal Biotechnology. 2010; 9(42):7209-7215.
12. Luna LG. Manual of Histological Staining Methods of the Armed Forces Institute of pathology. Edn 3, McGraw Hill Book Company, New York, USA, 1968.
13. Mobini B. Histological studies on pancreas of Goose (*Anser Albifrons*). Veterinary Research Forum. 2011; 2(1):25-29.
14. Parchami A, Kusha S. Effect of sex on histomorphometric properties of Langerhans islets in native chickens. In Veterinary Research Forum. 2015; 6(4):327-330.
15. Rawdon BB. Morphogenesis and differentiation of the avian endocrine pancreas, with particular reference to experimental studies on the chick embryo. Microscopy Research and Technique. 1998; 43(4):292-305.
16. Saadatfar Z, Asadian M. Anatomy of pancreas in mynah (*Acridotheres tristis*). Journal of applied animal research. 2009; 36:191-193.
17. Scanes CG. Hormones and Metabolism in Poultry. In: Scanes C.G. Update on Mechanisms of Hormone Action Focus on Metabolism, Growth and Reproduction. Publisher In Tech., 2011, 111-132.
18. Simsek N, Bayraktaroglu AG, Altunay H. Localization of insulin immunopositive cells and histochemical structure of the pancreas in falcons (*Falco Anaumanni*). Ankara Universitesi Veteriner Fakultesi Dergisi. 2009; 56:241-247.
19. Sivakumar M, Kannan TA, Parida SN, Sathyamoorth OR, Vijayaragavan C. Histology and histochemistry of the ductular and stromal components of the post hatch exocrine pancreas of Japanese quail (*Coturnix coturnix japonica*). Journal of Veterinary and Animal Sciences. 2000; 31:44-46.
20. Smith PH. Pancreatic islets of the Coturnix quail. A light and electron microscopic study with special reference to the islet organ of the splenic lobe. Anatomical Record. 1974; 178(3):567-585.
21. Snedecor GW, Cochran WG. Statistical Methods. 8th Edn. Iowa state university press, Ames, Iowa, USA, 1994.
22. Stornelli MR, Ricciardi MP, Miragliotta V, Coli A, Giannessi E. Morpho-structural Study of the Pancreas and Pancreatic Duct in Ostrich (*Struthio camelus L.*). Acta Veterinaria Brunensis. 2006; 75(2):157-160.
23. Tomita T, Doull V, Pollock HG, Kimmell JR. Regional distribution of pancreatic polypeptide and other hormones in chicken pancreas: Recipocal relationship between pancreatic polypeptide and glucagon. General and comparative endocrinology. 1985; 58:303-310.