



E-ISSN: 2320-7078

P-ISSN: 2349-6800

JEZS 2019; 7(2): 254-256

© 2019 JEZS

Received: 01-01-2019

Accepted: 05-02-2019

Shailesh Kumar Patel
 Department of Veterinary Pathology,
College of Veterinary Science and
A.H., CGKV, Anjora, Durg,
Chhattisgarh, India
Poornima Gumasta
 Department of Veterinary Pathology,
College of Veterinary Science and
A.H., CGKV, Anjora, Durg,
Chhattisgarh, India
DK Jolhe
 Department of Veterinary Pathology,
College of Veterinary Science and
A.H., CGKV, Anjora, Durg,
Chhattisgarh, India
Megha Katare Pandey
 Department of Veterinary Pathology,
College of Veterinary Science and
A.H., CGKV, Anjora, Durg,
Chhattisgarh, India
Chandrabhas Sannat
 Department of Veterinary
Microbiology, College of Veterinary
Science and A.H., CGKV, Anjora,
Durg, Chhattisgarh, India
Nidhi Rawat
 Department of Veterinary
Microbiology, College of Veterinary
Science and A.H., CGKV, Anjora,
Durg, Chhattisgarh, India
Amit Kumar Gupta
 Department of Veterinary
Microbiology, College of Veterinary
Science and A.H., CGKV, Anjora,
Durg, Chhattisgarh, India
Mrunali Kamble
 Department of Surgery and
Radiology, College of Veterinary
Science and A.H., CGKV, Anjora,
Durg, Chhattisgarh, India
Md. Osamah Kalim
 Department of Surgery and
Radiology, College of Veterinary
Science and A.H., CGKV, Anjora,
Durg, Chhattisgarh, India
Correspondence**Poornima Gumasta**
 Department of Veterinary Pathology,
College of Veterinary Science and
A.H., CGKV, Anjora, Durg,
Chhattisgarh, India

Hydatidosis and associated pathological changes in Sahiwal cow

Shailesh Kumar Patel, Poornima Gumasta, DK Jolhe, Megha Katare Pandey, Chandrabhas Sannat, Nidhi Rawat, Amit Kumar Gupta, Mrunali Kamble and Md. Osamah Kalim

Abstract

A Sahiwal cow of age 9 years was presented for the post-mortem examination to the Department of Veterinary Pathology, College of Veterinary Science and A.H., CGKV, Anjora, Durg, Chhattisgarh. The animal was cachectic with pale mucous membranes. Upon necropsy various monolocular and multilocular hydatid cysts were grossly noticed in various organs viz. lung, liver and spleen. On incision many cysts with protoscolices inside, were found deep in the parenchyma of affected organs. Microscopic examination showed congestion, infiltration of mononuclear cells and fibrosis adjacent to the cyst.

Keywords: cattle, hydatidosis, gross pathology, *Echinococcus*, histopathology

Introduction

Hydatidosis is an important helminthic zoonotic disease that threatens human and animal health all over the world with a high prevalence in India. The disease occurs due to a cestode belonging to the genus *Echinococcus* of family Taeniidae. The important parasite species include *Echinococcus granulosus*, *E. multilocularis*, *E. oligarthrus* and *E. Vogeli* [1, 2]. The life cycle of organism involves two hosts. The definitive host is usually a dog and other carnivores while a number of herbivorous animals like bovine, swine, equine, camel etc. acts as intermediate hosts [3]. The cysts are mostly observed in liver and lungs but could be found in many other organs such as spleen, heart, kidneys and omentum. In hosts, like cattle and buffalo which also considered as intermediate hosts, the disease mostly remains asymptomatic and is detected at post mortem inspection more often. The hydatid cysts grow slowly and take several years to grow big enough and cause symptoms [4]. As the time persists the host creates a strong immune response and covers the cyst with a fibrous capsule. This prevents the eradication of the infection from body. As time persists these structures grow and forms liquid filled vesicles. Thousands of scolex were formed from the germination membrane inside the cyst by asexual reproduction. These cysts can be of two types 'unilocular' when there is only one cyst and 'multilocular' when there are cysts independent of each other [5, 6].

The liver and lung is more prone for hydatid cyst than any other visceral organs. Its association in hepatobiliary system is both mechanical and toxic. The presence of large-size hydatid cysts is responsible for substantial economic loss on account of reduced productivity and condemnation of visceral organs and carcasses [7].

In the present study severe parasitic infection with *Echinococcus spp.* in a Sahiwal cow has been reported.

Materials and Methods

A Sahiwal cow was presented for the post-mortem examination to the Department of Veterinary Pathology, College of Veterinary Science and Animal Husbandry, CGKV, Anjora, Durg, Chhattisgarh. The detailed necropsy examination was carried out and all the gross pathological changes were recorded carefully. Organs were further subjected for the histopathological examination. Representative samples from all the organs were collected in 10% neutral buffered formalin. Dehydration and clearing was done by using acetone and benzene followed by wax impregnation and sectioning at 5 μ . Hematoxylin and eosin staining was done as per standard procedure described by Gridley (1960).

Results and Discussion

History revealed that animal was dull, depressed and emaciated. Upon necropsy viscera were found pale with hydroperitonium and hydropericardium. The liver, lung and spleen of the animal showed variable sized unilocular and multilocular cysts. The multilocular type of cysts predominantly existed. Most of the cysts were protruding out from the surface but considerable numbers were also found deeply embedded in the parenchyma of the organ. Cysts were filled with clear watery fluid and cut surface of these cysts manifested cavities lined by a smooth membrane which could be easily peeled off.

Liver of the animal had multiple small to large sized cysts located superficial to deep in the liver parenchyma. The diameter of cysts ranged from 2-5 cm filled with fluid ranging from 5 to 40 ml. On cutting, multiple scolices were found attached with internal surface of the cysts. The wall of cyst appeared yellow in colour. The liver was showing cystic enlargements due to presence of multiple cysts deeply embedded in the parenchyma resulting in appearance of shrunken areas on the surface (Fig.1A and Fig.1D). On histopathological examination congestion, infiltration of mononuclear cells and fibrosis was observed (Fig.2A).

Lung of the cow was found shrivelled and enlarged with cysts of around 5 cm in diameter and filled with approximately 50 ml of clear fluid. Replacement of the lung parenchyma with cystic cavities might be responsible for altering the appropriate respiratory physiology (Fig.1C). On histopathological examination congestion of vessels, infiltration of mononuclear cells and moderate degree of fibrosis was noticed (Fig.2B).

Spleen of the animal was also found involved and a large sized cyst of around 15 cm in diameter and approximately 800 ml of clear fluid was noticed which might have been formed by fusion of the multiple small size cysts. The cyst was covered by a thick membrane and replaced around 60% of the spleen renders it very less functional (Fig.1B). Histopathology revealed presence of protoscolices along with laminated layer and fibrous tissue proliferation around it.

Our results are in accordance with the various researchers. Earlier workers^[8] discussed about a rare case of splenic hydatidosis in a buffalo. They reported a cyst protruding out from the splenic surface. On opening the cyst, clear watery fluid along with protoscolices came out. The inner surface of cyst contained white, thin, translucent membrane. Microscopic examination revealed germinal layer with many protoscolices. Fibrous connective tissue proliferation around the laminated layer and a mild depletion of the lymphoid cells in the surrounding white follicles has been noticed.

Singh *et al.*^[9] found cysts on liver and lung of the animals. Cysts were surrounded by outer fibrous layer over the inner germinal layer and filled with clear fluid. Echinococcal protoscolices were also noticed in some of the sections. Histologically, slight haemorrhage, leucocyte infiltration and mild hepatocellular degeneration in the liver was noticed. The adjacent hepatic parenchyma showed atrophy, variable degeneration and infiltration. The parenchyma adjacent to cysts was markedly congested and showed multiple small areas of haemorrhages. In lungs, there was proliferation of fibrous connective tissue and infiltration of mononuclear cells.

Ali Ibrahim and Gameel^[2] reported multiple cysts round in shape and of variable sizes, either protruding from the surface or found deep in lung or liver parenchyma. Cysts were found

filled with a clear or turbid fluid, caseated material and few were found calcified. They also discussed about variable sized cysts which were found embedded in lung of the animal. Verma and Swamy^[7] reported presence of variable sized typical cysts, unilocular and multilocular in nature, protruding on the surface and filled with clear watery fluid. Acioz^[10] noted hydatid cysts of different sizes in the liver along with acidity in abdominal cavity. Predominant type of cysts reported were multilocular type, encircled with fibrous capsules on cross section.

Conclusion

Cases of hydatidosis have got huge public health importance as human are involved as intermediate host and of great economic importance in animals as it can cause condemnation of organs and death in case of systemic involvement of various organs. These factors imply that control and preventive measure must be taken in the enzootic areas. The disease is chronic and proliferative making all the vital organs less efficient and even may lead to multiple organ failure resulting into the death of the animal. Routine deworming with suitable antiparasitic drugs and early diagnosis may reduce the incidence of hydatidosis.

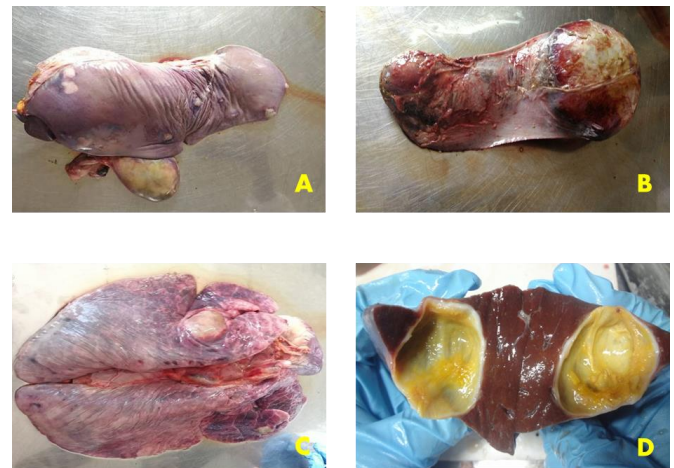


Fig 1 A: Liver showing multiple, variable sized hydatid cysts protruding out from the surface resulting into the wrinkling of surface; **B:** Spleen showing a large sized hydatid cyst replacing most of the splenic parenchyma; **C:** Lung showing shrivelled surface with a tennis ball sized hydatid cyst; **D:** Cut section of the liver showing hydatid cyst embedded in the liver parenchyma.

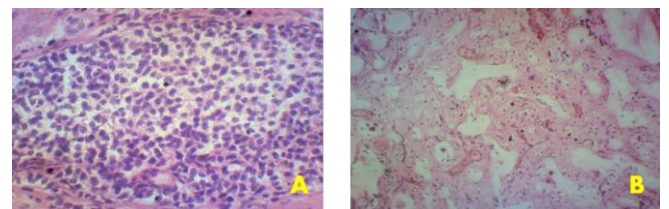


Fig 2: A Photomicrograph of liver showing severe infiltration of mononuclear cells. H&E x400; **B** Photomicrograph of lung showing fibrosis, congestion of vessels and infiltration of mononuclear cells in the areas adjacent to hydatid cyst. H&E x400.

References

1. Rausch RL. Taeniidae. In: Hubbert WF, McCulloch WF, Schurrenberger PR (eds) Diseases transmitted from animals to man. Thomas, Springfield, Illinois, 1975, 678-707.
2. Ali Ibrahim SE, Gameel AA. Pathological, Histochemical

- and Immunohistochemical Studies of Lungs and Livers of Cattle and Sheep Infected with Hydatid Disease. U. of K. Graduate College and Scientific Research. 2016. The 5th Annual Conference - Agricultural and Veterinary Research - February Khartoum, Sudan, Conference Proceedings. 2014; 2:328-344.
3. World Health Organization (WHO). Guidelines for surveillance, prevention and control of echinococcosis/hydatidosis. In Eckert J, Gemmell M, Matyas Z, Soulsby EJJ (eds). World Health Organization, Geneva, 1984, 1-147.
 4. WHO/OIE Manual on Echinococcosis in Humans and Animals: a Public Health Problem of Global Concern. 2001. Paris, France.
 5. Dziri C. Hydatid Disease: Continuous serious public health problem. World Journal of Surgery. 2001; 25:1-3.
 6. Bowman DD, Lynn RC. Geogis Parasitology for Veterinarians. 7 th WB. Philadelphia: Saunders company, 1999.
 7. Verma Y, Swamy M. Prevalence and Pathology of Hydatidosis in Buffalo Liver. Buffalo Bullatin. 2000; 28:207-211.
 8. Sreedevi C, Anitha Devi M, Annapurna P, Rama Devi V. A rare case of splenic hydatidosis in a buffalo: pathomorphological study. J Parasit Dis., 2014; 40(1):214-6.
 9. Singh BB, Sharma R, Sharma JK, Mahajan V, Gill JP. Histopathological changes associated with *E. granulosus* echinococcosis in food producing animals in Punjab (India). Journal of Parasitology Diseases. 2014; 40(3):997-1000.
 10. Acioz M, Celiksoz A, Ozçelik S, Degerli S. Prevalence of cyst hydatid in slaughtered cattle between April and May 2005 in Sivas. Turkish Journal of Parasitology. 2008; 32:205-207.