



E-ISSN: 2320-7078

P-ISSN: 2349-6800

JEZS 2019; 7(3): 1004-1006

© 2019 JEZS

Received: 12-03-2019

Accepted: 14-04-2019

Shongsir Warson Monsang

Associate Professor, Department of Surgery, College of Veterinary Sciences & A. H. R. K. Nagar, Tripura (W), India

Biplab Debroy

Assistant Professor, Department of Pathology, College of Veterinary Sciences & A. H. R. K. Nagar, Tripura (W), India

V Lalzawmliana

Assistant Professor, Department of Surgery, College of Veterinary Sciences & A. H. R. K. Nagar, Tripura (W), India

Sabyasachi Bhattacharya

Assistant Professor, Department of TVC (Surgery), College of Veterinary Sciences & A. H. R. K. Nagar, Tripura (W), India

Justin B William

Professor, Department of Surgery, College of Veterinary Sciences & A.H.R.K. Nagar, Tripura (W), India

Palpebral Conjunctivoplasty for dermoid cyst in a crossbred calf: A case report

Shongsir Warson Monsang, Biplab Debroy, V Lalzawmliana, Sabyasachi Bhattacharya and Justin B William

Abstract

Three months old crossbred calf was presented for unilateral haired masses on the right eye near the medial canthus of the eye since birth along with the clinical signs of epiphora and blepharospasms diagnostic of dermoid cyst. Following proper diagnosis, the case was surgically treated by removing the haired masses by means of full thickness wedge resection under adequate sedation with xylazine and auriculopalpebral nerve block using lignocaine hydrochloride (2%). The surgical wound healed completely by 10th day post operation without any signs of complications and recurrence.

Keywords: Dermoid, calf, sedation, auriculopalpebral

Introduction

Dermoid cyst is an uncommon developmental anomaly that occurred as single, solid, skin-like masses of tissue, adherent usually to the anterior surface of the eye, causing irritation and interfering with vision. They are usually observed in limbus, cornea, conjunctiva, corneoconjunctiva of the eye [7], and also sometime located in membranacitans and eyelid [11]. Dermoid containing hair follicle may caused irritation resulting in chronic inflammation of conjunctiva and cornea leading to visual impairment if it remains untreated for prolong period [9]. Therefore, the condition needs to be corrected as early as possible so as to prevent any damage to the underlying important structures of the eye and enhance the process of vision. Histologically, desmoids are lined with stratified epithelium resembling normal skin with adnexa and may be filled with keratinous material [10]. This paper reports a case of successful surgical correction of congenital conjunctival dermoid cyst in a crossbred calf.

2. Materials and Methods

Three months old crossbred calf was presented for unilateral haired masses on the right eye since birth along with excessive lacrimation and blepharospasms [Fig.1 (a)]. On physical examination, the calf was in good bodily condition and all the clinical parameters (heart rate, respiratory rate, rectal temperature) were within the normal physiological limits with normal complete blood count and serum chemistries. Clinical examination revealed presence of dermoid masses slightly on the ventral side of palpebral conjunctiva with tufts of irritating hairs [Fig.1 (b)]. Blinking, consensual and photomotor papillary reflexes were also tested and recorded intact. Based on anamnesis and clinical findings, the case was diagnosed as congenital palpebral-conjunctival dermoid cyst of the right eye. Surgical excision of the masses was recommended to prevent further ocular complications.

Following overnight fasting, the calf was first sedated with xylazine (@ 0.1mg/kg, IM) and restrained in left lateral recumbency with the affected side of the eye facing upward. After adequate sedation, auriculopalpebral nerve block was also performed by injecting lignocaine hydrochloride (2%) solution over the zygomatic area to block the movement of the globe and eyelids followed by thorough flushing of the affected eye with sterile normal saline solution. Under aseptic measures, the mass with tufts of hairs on the palpebral border of the conjunctiva was grasped and clamp at the base with a small mosquito forceps and excised by full thickness wedge resection [Fig.2 (a)]. The edge of surgical wound was sutured in single mattress suture pattern using non-absorbable suture material (vicryl no. 3-0). The excised mass was collected and submitted for histopathology after fixing in 10% neutral buffered formalin. Post-operatively, a course of antibiotic (ceftriaxone @10mg/kg, IM) and anti-inflammatory

Correspondence**Biplab Debroy**

Assistant Professor, Department of Pathology, College of Veterinary Sciences & A. H. R. K. Nagar, Tripura (W), India

(meloxicam @0.2mg/Kg, IM) drugs were given for five days along with local application of eyedrop (flurbiprofen, 2 drops TID) and eye ointment (ciprofloxacin, BID) locally until signs of inflammation was eliminated. The calf was reported with complete healing of the surgical wound without any other complications on 10th day of follow up observation [Fig.2 (b)].

3. Results and Discussions

Many breeds of cattle are reported to be affected with dermoid cyst which can be unilateral or bilateral in origin [13] which in our case is unilateral in nature. The precise developmental mechanisms involved in the pathogenesis of ocular dermoids are not known [4, 5, 14]. However, metaplasia of mesenchyme (of primarily neural crest origin) resulting in abnormal differentiation of the surface ectoderm is considered the most likely mechanism [2, 3]. The tissue or hair follicles of the dermoid cyst usually caused irritation of the eye which leads to epiphora, blepharospasm, subacute keratoconjunctivitis and visual impairment [8]. In the present case, signs of epiphora and blepharospasms were only observed without affecting the normal vision. Various methods of treatment of dermoid have been advocated such as enucleation, exenteration, evisceration, cryotherapy, lamellar kертotomy or combination of technique [12]. In our present

report, successful outcome with full thickness wedge resection of the mass is discussed. Histologically, the section revealed moderately hyperplastic, keratinized stratified squamous epithelium overlying a thick collagenous stroma resembling normal skin with well developed hair follicles, sebaceous glands and lumen filled with keratinous material similar to those reported in earlier literature by various authors [1, 6, 12]. Hence, the excised tissue was histologically confirmed as a conjunctival dermoid cyst in the present case [Fig.3 (a & b)].

4. Conclusion

Dermoid cyst irrespective of its location can be successfully treated with excellent outcome if the cases are presented in time before they caused visual impairment in chronic cases. Surgical intervention under adequate sedation combined with related nerve blocks is proved beneficial with good success rate.

5. Acknowledgement

The authors are thankful to the Principal, College of Veterinary Sciences & A.H., Tripura, for providing necessary facilities to carry out the work.

6. Figures

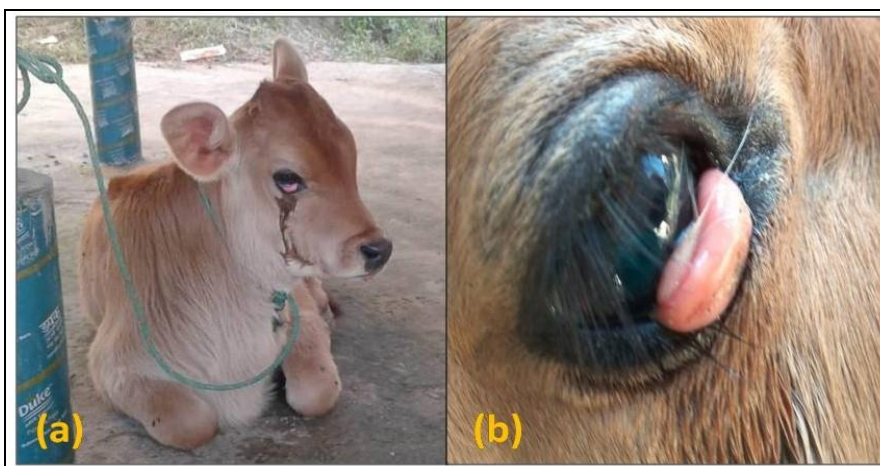

Fig 1 (a): Epiphora and blepharospasm of the right eye in the affected calf.
Fig 1 (b): Dermoid mass with hairs on lower palpebral conjunctiva.

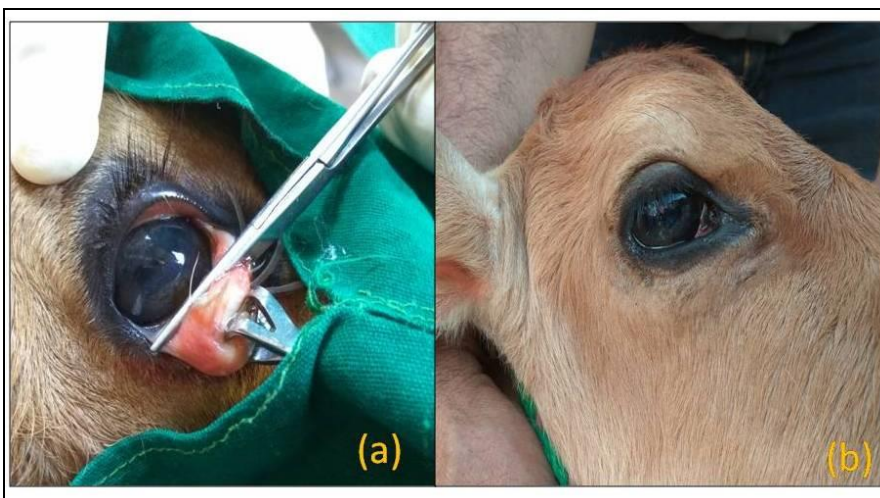


Fig 2 (a): Full thickness wedge resection of the dermoid mass.
Fig 2 (b): Complete healing of the surgical wound (10th day post operative follow up).

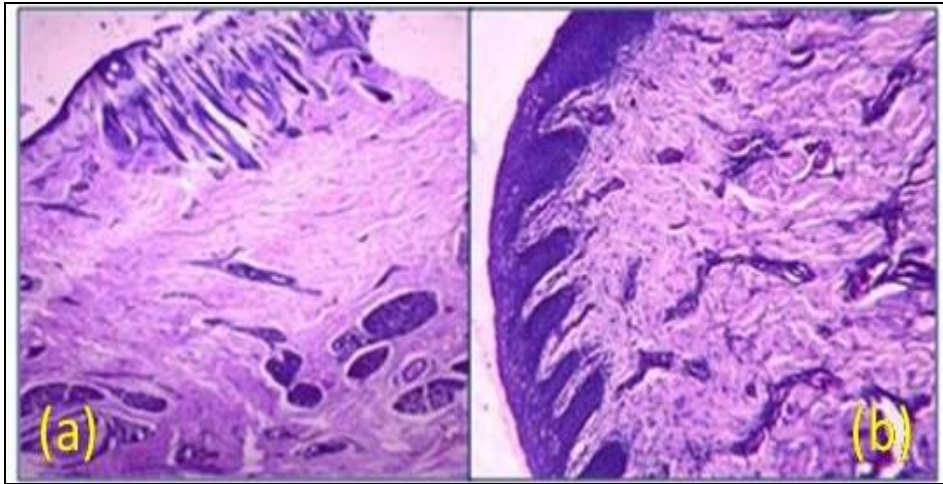


Fig. 3 (a & b): Keratinized stratified squamous epithelium resembling normal skin with well developed hair follicles and sebaceous glands (H & E, 50X).

7. References

1. Alam MM, Rahman MM. A three years retrospective study on the nature and cause of ocular dermoids in crossbred calves. *Open Veterinary Journal*. 2012; 2:10-14.
2. Castro JR, Hendrix DVH, Van Amstel SR. Ocular dermoids in cattle: a case report and review. *Bovine Practitioner*. 2006; 40(1):8-12.
3. Cook SC. Ocular embryology and congenital malformations. In: Gelatt K.N. (Ed). *Veterinary Ophthalmology*. 3rd edn. Philadelphia: Lippincott, Williams & Wilkins, 1999, 3-30.
4. Gelatt KN. Corneo-conjunctival dermoid cyst in a calf. *Veterinary Medicine/Small Animal Clinics*. 1972; 67:1217.
5. Greene HJ, Leipold HW, Huston K. Congenital defects in cattle. *Irish Veterinary Journal*. 1973; 27(1):37-45.
6. Jena B, Ahmed A, Pagrut NK. Surgical management of islands of ocular dermoids in a holstein friesian cross bred calf—a case study. *Journal of Livestock Science*. 2015; 6:1-3.
7. Lawson DD. Corneal dermoids in animals. *Veterinary Record*. 1975; 97(23):449-450.
8. Maggs DJ. Conjunctiva, Cornea and Sclera. In: Maggs, D.J., Miller, P., Ofri, R. (eds), *Slatter's Fundamentals of Veterinary Ophthalmology*, 4th Edition, Elsevier Health Sciences, St. Louis, Missouri, USA, 2008, 148-181.
9. Maggs DJ, Miller P, Ofri R. *Slatter's Fundamentals of Veterinary Ophthalmology*. 4th Edition, Elsevier Health Sciences, USA, 2012, 148-181.
10. Munoz E, Leiva M, Naranjo C, Pena T. Retrobulbar dermoid cyst in a horse: a case report. *Veterinary Ophthalmology*. 2007; 10:394-397.
11. Roh YS, Gi DB, Lim CW, Kim B. Asymmetrical ocular dermoid in native Korean cattle. *Journal of Animal and Plant Sciences*. 2014; 24(3):976-978.
12. Sarrafzadeh-Rezaei F, Farshid AA, Saifzadeh S. Congenital Ocular Dermoid Cyst in a River Buffalo (*Bubalus bubalis*) Calf. *Journal of Veterinary Medicine. A, Physiology, Pathology, Clinical Medicine*. 2007; 54:51-54.
13. Simon S, William BJ, Rao GD, Sivashanker R, Kumar RS. Congenital malformations in ruminants and its surgical management. *Veterinary World*. 2010; 3(3):118119.
14. Yeruham I, Perl S, Liberboim M. Ocular dermoid in dairy cattle - 12 years survey. *Revue de Médecine Vétérinaire*. 2002; 153(2):91-92.