



E-ISSN: 2320-7078

P-ISSN: 2349-6800

JEZS 2019; 7(4): 312-314

© 2019 JEZS

Received: 28-05-2019

Accepted: 30-06-2019

**S Solanki**

Department of Veterinary  
Microbiology, College of  
Veterinary & animal Science,  
Navania, Vallabh Nagar,  
Udaipur, Rajasthan, India

**K Purohit**

Department of Veterinary  
Pathology, College of Veterinary  
& animal Science, Navania,  
Vallabh Nagar, Udaipur,  
Rajasthan, India

## Case report: A heavily infected camel with both *Cystic echinococcosis* and *Oestrus ovis* larva

**S Solanki and K Purohit****Abstract**

A Unique post mortem case of a she-camel found to be heavily infected with both *Cystic echinococcosis* and *Oestrus ovis* larva is reported. The *Echinococcosis* cysts were found to be distributed all over the lungs and also the animal was infested with *Oestrus ovis* larva found in the trachea and lung. The animal showed respiratory distress and no other apparent clinical signs prior to death as reported in history.

**Keywords:** Camel, echinococcosis, *Oestrus ovis*, myiasis

**Introduction**

Numerous camels (*Camelus dromedarius*) are raised in the semi-arid regions in the eastern part and Sothern parts of the Rajasthan. Camel raisers basically keep the animals for milk and carry load purpose. Hydatidosis/cystic echinococcosis (CE), an important zoonotic helminthic disease, remains as a health problem with a large socioeconomic burden in many parts of the world, including the Middle East as reported [1-4]. Reported that there were different taxonomic differences in adult morphology, host specificity, and pathogenicity. *E. granulosus* with different strains of were identified to precisely portray their specificity for intermediate hosts (e.g., sheep, buffalo, horses, cattle, pigs, camels, and cervids). The larval stage of the parasite (metacestode) are maintained in nature by carnivores, which act as definitive hosts (a canine, felid, or hyeanid), and by intermediate hosts, which are usually herbivores (e.g., sheep, goats, cattle, camels, and cervids). The small intestine of the carnivore the adult egg-producing stage of the cestode. The definitive host can be infected with hundreds of worms, with each worm producing thousands of eggs each day. The eggs, which are shed in the stool of the definitive host, are infective upon release. The eggs can remain infective for months or up to a year depending on environmental conditions. The eggs are sensitive to desiccation and heat, but can survive very low temperatures [5].

The invasion of organs and tissues of humans or vertebrates by dipterous larvae, is defined as myiasis, which then feed upon the living or dead tissues for some period of time [6]. *Oestrus ovis* Linnaeus, 1758, or the sheep bot fly, deposits its first instar in or near the nasal passages of small ruminants, and the larvae subsequently develop within the nasal fossae and cranial sinuses [7].

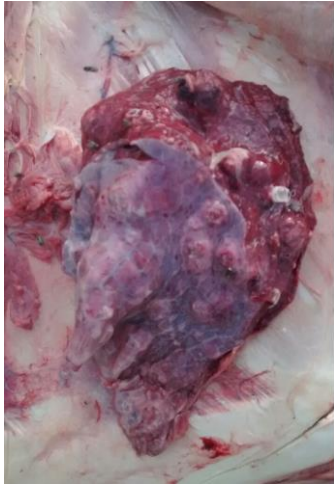
A severe stress condition in natural desert habitat makes them susceptible to many diseases and ailments [8]. Parasitic diseases either lower their working efficiency or even may result in death in camels. The disease that is not readily apparent to the farmers, but of considerable economic and public health importance occurring in many countries [9].

**Case history and observations**

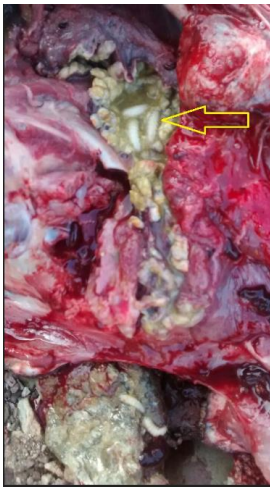A post mortem case of camel was conducted in field condition as reported by the owner, with antemortem with history of dyspnea and no other clinical signs were present. Postmortem was conducted and lungs showed *Echinococcosis* cysts of different diameters, and the varying size of these cysts was found to be distributed all over lungs (Fig. 1) along with hemorrhages.. After cut, opening the lungs showed bilateral hemorrhagic pneumonia with the presence of *Oestrus ovis* larva (Fig.2). Upon further inspection of the upper respiratory system, intact dipterous larvae were discovered in the trachea (Fig. 3) and Many larvae were still active and crawling about freely, however, while some were loosely attached, others adhered firmly to the trachea by their hooks and when removed, firm reddish nodules marked the sites of attachment the trachea was fully congested and hemorrhagic and no other lesions were observed during the postmortem of the animals.

**Correspondence****S Solanki**

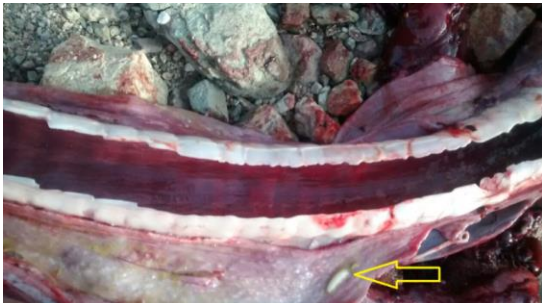Department of Veterinary  
Microbiology, College of  
Veterinary & animal Science,  
Navania, Vallabh Nagar,  
Udaipur, Rajasthan



**Fig 1:** Lung of Camel with generalised Hydatid cysts



**Fig 2:** *Oestrus ovis* larvae in lungs.



**Fig 3:** *Oestrus ovis* larvae in trachea.

### Discussion

*Cystic echinococcosis*, an important helminthic disease, remains as a health problem in animals in many parts of the world, but not yet reported in India. The presence of cyst and variation in number has also been reported by investigators and found a variation in the prevalence of camel hydatidosis for different areas having different environmental and climatic conditions [10]. This variation may be explained by better environmental conditions that are conducive to the perpetuation of the parasite [11-12]. The *Cystic echinococcosis* might be related to the practices keeping female camel around the homesteads in the backyard for the milk production purpose. Hence, they were exposed to the contaminated environment with shedding of the gravid segment of *Echinococcus granulosus* by infected dogs [13]. Moreover, female camels remain longer than males for reproductive

purposes in the area and this justifies the probability of having higher, prevalence and mean intensity in females than in males. The congested and hemorrhagic observed in the trachea might be due to the pathogenicity of *O. ovis* and is believed to be the result of mechanical trauma induced by larval hooks and spines reported [14].

This case suggests that camels are able to serve as accidental hosts for the *O. ovis* species of bot fly. The history was presented dyspnea and respiratory stridor probably contributed towards establishing a state of relative immunosuppression. It is likely that these parasitic larvae were able to develop in the camel because of its compromised immunological state also reported [15]. These flies can thrive in a wide range of environmental temperatures, and despite their specificity as parasites of sheep and goats, *O. ovis* has been reported in a variety of hosts as discussed [16]. In spite of the high incidence of camel nasal botfly, little is known about its clinical and pathological effects. Except in severe infestations, few symptoms are reported to be the outcome of this larval infection reported [17]. The changes may occur concurrently in the same animal because of the prolonged irritation and feeding activities of the larvae. Considering the facts that the infestation can be massive, that other organs may be involved and that the larvae may remain in situ for almost a whole year

Despite the high incidence of nasopharyngeal myiasis and *Cystic echinococcosis* in many camel rearing countries, very few epidemiological surveys have been carried out to study the prevalence and the influence of seasonal variation on the prevalence of the infestation.

### Conclusion

The above study showed that camel with simultaneous nasopharyngeal myiasis and *Cystic echinococcosis* must have been due to the reason, it belonged to particular community which are rearers of camels and other small ruminants side by side.

### References

1. Budke CM, Deplazes P, Torgerson PR. Global socioeconomic impact of *Cystic echinococcosis*. *Emerging Infectious Disease*. 2006; 12(2):296-303.
2. Fasihi Harandi M, Budke CM, Rostami S. The monetary burden of *Cystic echinococcosis* in Iran. *PLOS Neglected Tropical Diseases*. 2012; 6(11):e1915.
3. Sadjjadi SM. Present situation of echinococcosis in the Middle East and Arabic North Africa. *Parasitology International*. 2006; 55:S197-20.
4. Nakao M, Lavikainen A, Yanagida T, Ito A. Phylogenetic systematics of the genus *Echinococcus* (Cestoda: Taeniidae). *International Journal for Parasitology*. 2013; 43:1017-1029.
5. Eckert J, Gemmel MA, Meslin FX, Pawłowski ZS. (ed). WHO/OIE manual on echinococcosis in humans and animals: a public health problem of global concern. World Organisation for Animal Health (Office International des Epizooties), Paris, France, and World Health Organization, Geneva, Switzerland, 2001.
6. Hall M, Wall R. Myiasis of humans and domestic animals. *Advances in Parasitology*. 1995; 35:257-334.
7. Heath AC, Johnston C. Nasal myiasis in a dog due to *Oestrus ovis* (Diptera: Oestridae). *New Zealand Veterinary Journal*. 2001; 49(4):164.
8. Abbas B, Saint-Martin G, Planchenaut D. Constraint to

- camel production in Eastern Sudan: a survey of pastoralist conception. Sudan Journal of Veterinary Science and Animal Husbandry. 1993; 32(1):31-41.
9. Taylor MA, Coop RL, Wall RL. Veterinary Parasitology, 3rd edn. Blackwell Publishing, Oxford, 2007.
  10. Ibrahim MM. Study of *Cystic echinococcosis* in slaughtered animals in Al Baha region, Saudi Arabia: interaction between some biotic and abiotic factors. Acta Tropica. 2010; 113:26-33.
  11. Njoroge EM, Mbithi PMF, Gathuma JM, Wachira TM, Gathura PB, Magambo JK *et al.* A study of *Cystic echinococcosis* in slaughter animals in three selected areas of northern Turkana, Kenya. Veterinary Parasitology. 2002; 104:85-91.
  12. Wachira TM, Macpherson CNL, Gathuma JM. Release and survival of *Echinococcus* eggs in different environments in Turkana, and their possible impact on the incidence of hydatidosis in man and livestock. Journal of Helminthol. 1991; 65:55-61.
  13. Parija SC. Medical Parasitology, Protozoology and Helminthology text and Atlas, 2nd edn. Medical Books Publisher, Chennai, 2004, 221-229.
  14. Dorchie PH, Tabouret G, Hoste H, Jacquiet P. Larval-host parasite relationships Part D: Oestrinae host-parasite interactions. In: Colwell, DD. Hall, MJ. Scholl, PJ. Editors. The Oestrid flies: Biology, host – parasite, relationships, impact and management. Cambridge: CABI Publishing, 2006, 191-200.
  15. Luis Antonio Gomez-Puerta, Karen Ann Alroy, Daniel Santiago Ticona, Maria Teresa Lopez-Urbina, Armando Emiliano Gonzalez. A case of nasal myiasis due to *Oestrus ovis* (Diptera: Oestridae) in a llama (*Lama Glama*). Revista Brasileira de Parasitologia Veterinária. 2013; 22(4):608-610.
  16. Biggs HC, McClain E, Muller GL, Anthonissen M, Hare KM. A prediction model for strike in the sheep nasal fly, *Oestrus ovis*, in Namibia. Preventive Veterinary Medicine. 1998; 33(1-4):267-282.
  17. Hadani A, Rauchbach K. The occurrence of myiasis in domestic animal in Israel. Deutsche Tierärztliche Wochenschrift. 1973; 80:137-139.