



E-ISSN: 2320-7078

P-ISSN: 2349-6800

JEZS 2019; 7(4): 876-879

© 2019 JEZS

Received: 27-05-2019

Accepted: 29-06-2019

**KB Ashok Kumar Reddy**

PG scholar, Department of  
Veterinary Pathology, College of  
Veterinary Science,  
Rajendranagar, P.V. Narsimha  
Rao Telangana Veterinary  
University, Hyderabad, India

**M Lakshmi Namratha**

PG scholar, Department of  
Veterinary Pathology, College of  
Veterinary Science,  
Rajendranagar, P.V. Narsimha  
Rao Telangana Veterinary  
University, Hyderabad, India

**Y Ravi Kumar**

Assistant professor, Department  
of Veterinary Pathology, College  
of Veterinary Science,  
Rajendranagar, P.V. Narsimha  
Rao Telangana Veterinary  
University, Hyderabad, India

**S Soujanya**

Assistant professor, Department  
of Veterinary Pathology, College  
of Veterinary Science, Korutla,  
P.V. Narsimha Rao Telangana  
Veterinary University,  
Hyderabad, India

**M Lakshman**

Professor & Office in-charge of  
Ruska labs, Department of  
Veterinary Pathology, College of  
Veterinary Science, Korutla,  
P.V. Narsimha Rao Telangana  
Veterinary University,  
Hyderabad, India

**Correspondence****S Soujanya**

Assistant professor, Department  
of Veterinary Pathology, College  
of Veterinary Science, Korutla,  
P.V. Narsimha Rao Telangana  
Veterinary University,  
Hyderabad, India

## Marek's disease outbreak among vaccinated flock of broad breasted white turkey breed

**KB Ashok Kumar Reddy, M Lakshmi Namratha, Y Ravi Kumar, S Soujanya and M Lakshman**

### Abstract

Twenty (20) dead broad breasted white turkey birds of eighteen (18) months old were presented for routine post mortem examination during October to December 2018 from poultry experimental station to the Department of Veterinary Pathology, College of Veterinary Science, PVRNTVU, Rajendranagar, Hyderabad. On necropsy, the gross lesions observed were hepatomegaly, splenomegaly, enlarged pancreas and thickened proventriculus. Multiple greyish white nodular growths around 5 – 10 cm diameter were also observed on pancreas, spleen and intestines. Impression smears from liver and spleen were prepared for cytological examination. Liver, spleen, pancreas and proventriculus were collected in 10% neutral buffered formalin for histopathological examination. Cytology and histopathology of the visceral organs showed the presence of numerous proliferating pleomorphic lymphocytes is suggestive of Marek's disease.

**Keywords:** Marek's disease, cytology, histopathology, pleomorphic lymphocytes, broad breasted white turkey, nodular growths

### Introduction

Marek's disease is a lymphoproliferative and neuropathic disease of domestic chickens and less commonly observed in turkeys, quails and pheasants characterised by enlargement of visceral organs in acute form and enlargement of one or more peripheral nerves in classical form [1, 2]. It is named after Jozsef Marek, a Hungarian veterinarian. It is a highly contagious viral neoplastic disease caused by Marek's disease virus (MDV) serotype 1 of the family Herpesviridae, subfamily Alpha Herpesvirinae, genus *Mardivirus* and species *Gallid herpesvirus 2* [3]. MDV is a strictly cell associated virus except in feather follicle epithelium, where the cell free virus is produced. Feather follicle cells are the important source of infection and infected dander is readily disseminated in premises and inhaled by susceptible birds [4]. MDV causes infiltration of lymphocytes in peripheral nerves, iris, skin and visceral organs resulting into development of tumours in visceral organs and immune suppression. In MDV infection, clinical signs include anorexia, weight loss, paralysis of legs, wings and neck, grey eye, vision impairment, blindness, skin lesions and poor performance. MDV causes huge economic losses to the poultry industry because it is an immunosuppressive disease which increases susceptibility to other infections [5]. MDV is currently distributed worldwide including India. Waterfowls act as reservoir of MDV for other avian species since they are involved in transmission of the virus without showing any clinical signs [6]. Turkey is an unusual host for MDV [7]. Recently, cases of Marek's disease in turkeys have been reported by some authors [7, 8, 9].

Present communication describes the rare occurrence of Marek's disease in turkeys of Rajendranagar, Hyderabad.

### 2. Materials and Methods

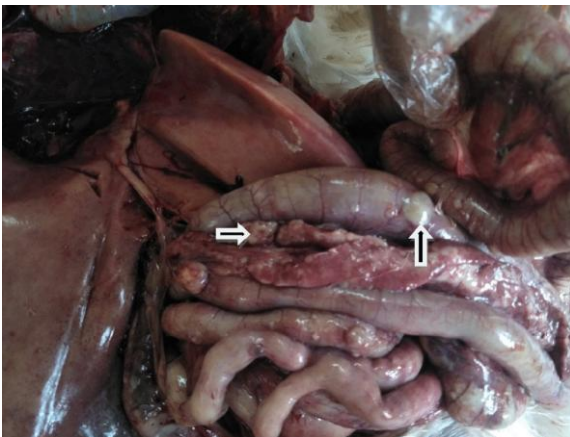
20 dead broad breasted white turkeys from poultry experimental station were presented for necropsy to the Department of Veterinary Pathology, College of Veterinary Science, Rajendranagar during October to December 2018. Postmortem of dead birds was done and gross lesions were noted. Impression smears of liver and spleen were taken and stained with Leishman's stain for cytology. Tissues like proventriculus, liver, spleen and pancreas were collected in 10% neutral buffered formalin for histopathology. Then tissues were washed under running tap water for overnight and further dehydrated in alcohol, embedded in paraffin

and 5 microns thick sections were cut with the microtome. Then sections were stained with Hematoxylin and Eosin (H&E) and examined under microscope [10].

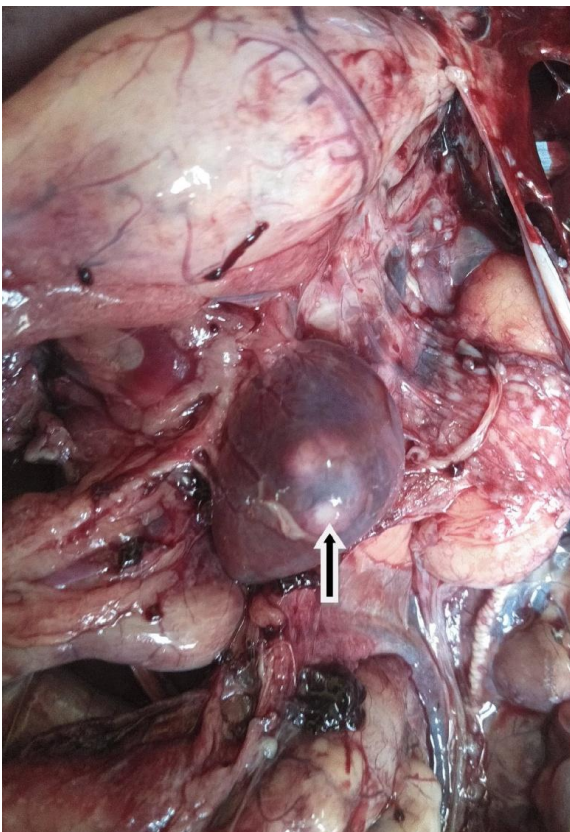
### 3. Results

Marek's disease was diagnosed in 15 broad breasted white turkeys out of 20 from commercial growing unit based on gross lesions, cytology and histopathology.

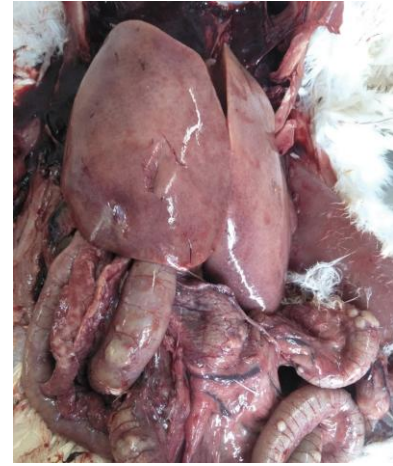**3.1 Gross lesions:** Multiple greyish white nodular growths around 5 – 10 cm diameter were observed on pancreas, spleen, and intestines. Cut section of the nodule was grey colored, smooth and firm. Diffusely enlarged liver, spleen and pancreas were noticed. Surface of the liver was granular. Thickened proventriculus was seen in few turkeys (Fig 1, 2, 3).



**Fig 1:** Multiple creamy white nodular growths on pancreas and intestines (arrow)



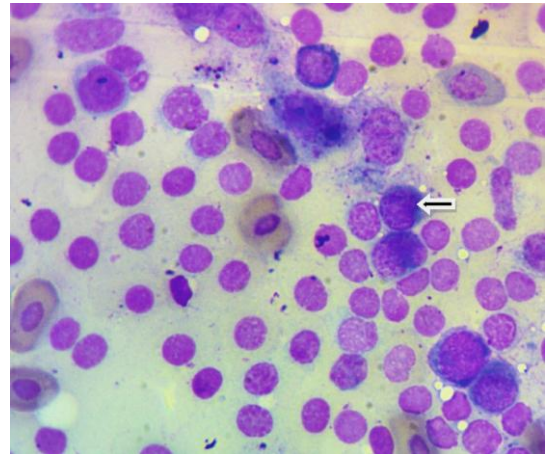
**Fig 2:** Spleen showing greyish white nodular growth projecting from capsular surface (arrow) and diffusely enlarged proventriculus.



**Fig 3:** Diffuse enlargement of liver in Marek's disease

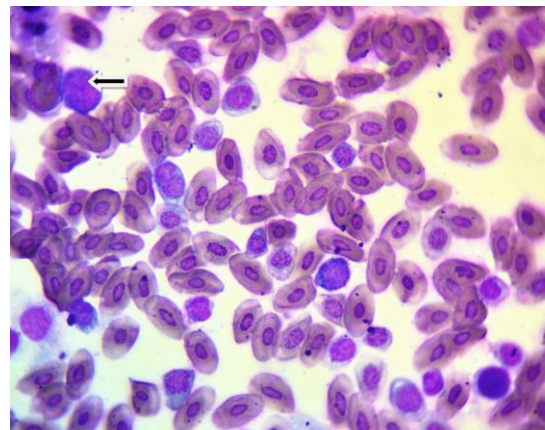
### 3.2 Cytological examination:

**Liver:** The stained liver impression smears revealed proliferating pleomorphic lymphocytes (Fig 4). Tumour cells showed round to oval, dark, vesicular and hyperchromatic nuclei and scanty eosinophilic cytoplasm. Mitotic figures were seen.



**Fig 4:** Liver impression smear showing population of neoplastic pleomorphic lymphocytes (arrow). Leishman's stain.

**Spleen:** Touch impression smears from the tumours of the spleen showed pleomorphic lymphocytic cell population (Fig 5). The neoplastic cells having large, irregular, dark and hyperchromatic nuclei and scanty cytoplasm.

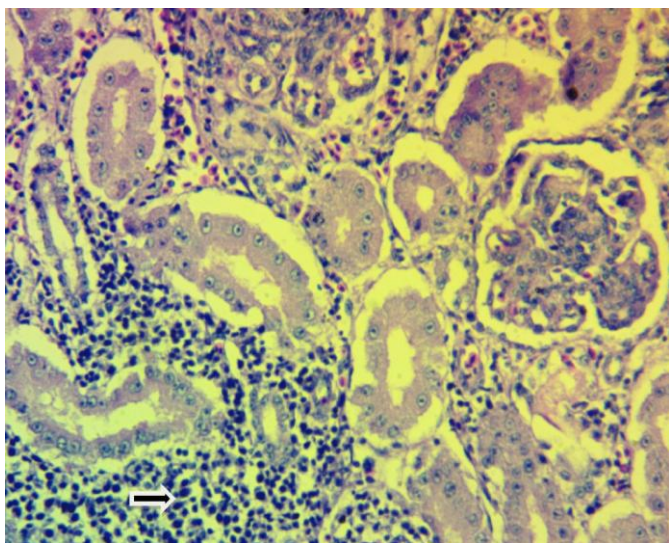


**Fig 5:** Spleen impression smear showing population of neoplastic pleomorphic lymphocytes (arrow). Leishman's stain.



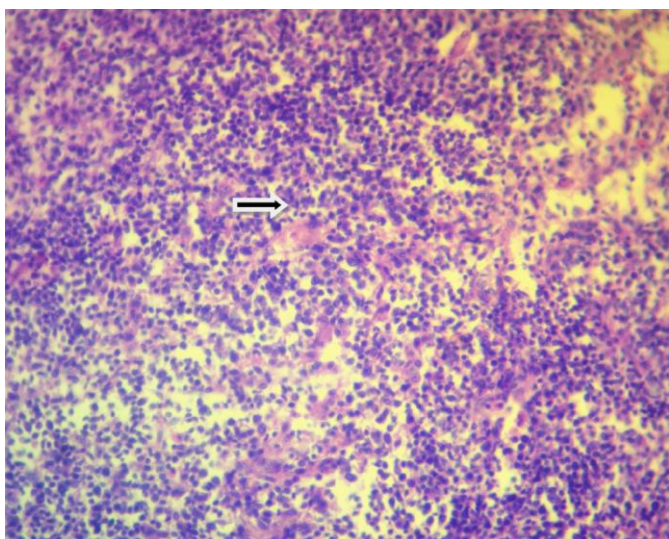
### 3.3 Histopathological examination

**Pancreas:** Sections of pancreas showed pleomorphic mononuclear cell infiltration into the interstitium and degenerative changes in the exocrine pancreatic acini and islets of langerhans (Fig 6). There is atrophy of some of the pancreatic acini and infiltration of heterophils was noticed



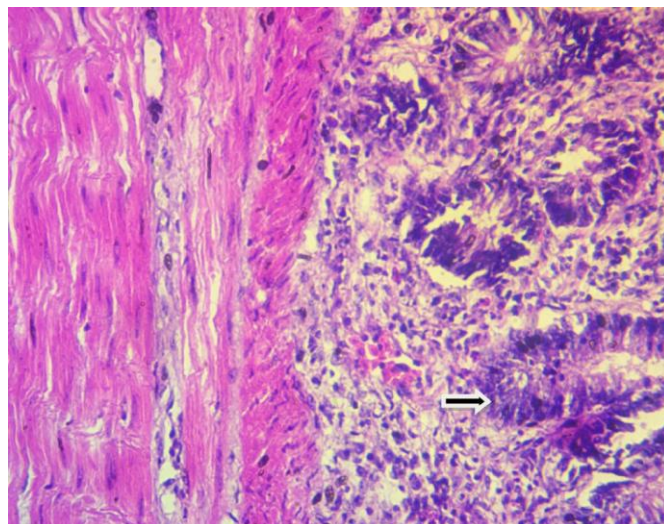
**Fig 6:** Section of pancreas showing prominent lymphoid infiltration into the interstitium with degenerative changes in the exocrine pancreatic acini and islets of langerhans (arrow) (HE x 40X)

**Spleen:** Sections of spleen revealed diffuse infiltration of large lymphoblasts in to the parenchyma and there is loss of normal architecture of the spleen (Fig 7). There is depletion of lymphocytes, splenic blood vessels were congested and areas of necrosis were seen



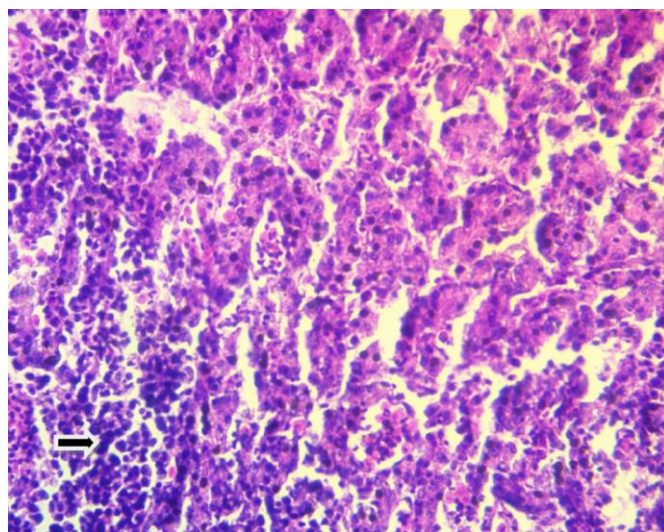
**Fig 7:** Splenic parenchyma showing diffused infiltration of lymphoid cells (arrow) (HE x 40X)

**Proventriculus:** Sections of proventriculus showed prominent aggregates of pleomorphic lymphoid cells in mucosa and muscularis resulting in thickening of the muscular layer. Degenerative changes were noticed in glandular epithelium and there is disruption of the mucosal glands (Fig 8). Focal areas of necrosis and haemorrhages were seen in submucosa.



**Fig 8:** Proventriculus section showing prominent lymphoid proliferation with degenerative changes in glandular epithelium (arrow) (HE x 40X)

**Liver:** Pleomorphic mononuclear cell infiltration into the sinusoidal spaces and cloudy swelling of the hepatocytes was noticed in sections of the liver (Fig 9). There is replacement of hepatic parenchyma with pleomorphic population of small lymphocytes, lymphoblasts and plasma cells. Tumour cells showed large vesicular hyperchromatic nuclei and numerous mitotic figures.



**Fig 9:** Liver section showing prominent pleomorphic lymphocytic infiltration with cloudy swelling (arrow) (HE x 40X)

### 4. Discussion

In present study, diffuse infiltration of lymphoproliferative cells may be resulted in enlargement of the various visceral organs like liver, spleen and pancreas. Splenomegaly may also be due to the viral replication. Thickened proventriculus may be due to the deposition of aggregates of pleomorphic small lymphocytes, lymphoblasts and plasma cells in the mucosa and glands. Similar gross lesions of Marek's disease in turkeys [9, 11] and in chicken [12, 13] were reported by previous authors. In present study, cytology and histopathology of various visceral organs revealed diffuse proliferation of pleomorphic lymphocytes. Similar cytological and histopathological observations were noticed by earlier authors [6, 9, 11, 14]. Visceral lymphomas are common in more virulent forms of the disease [15]. In present study, lymphomas are

noticed on various visceral organs which indicates that it was caused by more virulent MDV strain and the increasing virulence of MDV due to mutations may be the reason for the outbreak of Marek's disease in vaccinated turkey farm. There is necrosis of lymphoid organs like spleen which may be resulted in immune suppression and death in turkeys.

### 5. Conclusion

In conclusion, the present study describes the outbreak of Marek's disease among the vaccinated flock of broad breasted white turkey which was diagnosed on the basis of characteristic gross, cytological and microscopic changes in tissues.

### 6. Acknowledgement

Authors were highly grateful to PVNRTVU, Rajendranagar, Hyderabad for providing facilities to carry out the present case study.

### 7. References

1. Payne LN, Venugopal K. Neoplastic diseases: Marek's disease, avian leukosis and reticuloendotheliosis. *Revue Scientifique et Technique-Office International des Epizooties*. 2000; 19(2):544-560.
2. Antonio Zanella. *Poultry disease manual. Characteristics and Control of infections*. 2010, 33.
3. Murata S, Hayashi Y, Kato A, Masayoshi I, Sarah T, Misao O *et al*. Surveillance of Marek's disease virus in migratory and sedentary birds in Hokkaido, *The Veterinary Journal*. 2012; 192(3):538-540.
4. Schat KA, Nair V. Marek's disease. In: Saif YM, Barnes HJ, Glisson JR. *Diseases of poultry*. Edn. 12, Ames: State Press, Iowa, 2008, 458-520.
5. Shambhu DS, Rajamani B, Asok Kumar, Rajib D, Amit Kumar V, Kuldeep D. Recent Trends in Diagnosis and Control of Marek's Disease (MD) in Poultry. *Pakistan Journal of Biological Sciences*. 2012; 15(20):964-970
6. Vahid RR, Monire K. Marek's Disease in A Peafowl (*PavoMutilus*); Pathological, Immunohistochemical and Molecular Studies. *Approaches in Poultry, Dairy and Veterinary Sciences*. 2018; 4(1):310-313.
7. Davidson I, Malkinson M, Weisman Y. Marek's disease in turkeys. I. A seven-year survey of commercial flocks and experimental infection using two field isolates. *Avian Diseases*. 2002; 46(2):314-321.
8. Pennycott TW, Venugopal K. Outbreak of Marek's disease in a flock of turkeys in Scotland. *The Veterinary Record*. 2002; 150:277-279.
9. Blake-Dyke C, Baigent S. Marek's disease in commercial turkey flocks. *Veterinary Record*. 2013; 173(15):376-376.
10. Luna GLHT. *Manual of histological and special staining techniques*. Edn 2, The Blakistone Divison McGraw-Hill Book Company, New York, Toronto London, 1968; 1-5:9-34.
11. Hughes K, Archer J, Constantino-Casas F, Wozniakowski GJ, Baigent S. Diagnostic investigation of Marek's disease in a turkey. *Veterinary Record Case Reports*. 2016; 4(1):291.
12. Zhuang X, Zou H, Shi H. Outbreak of Marek's disease in a vaccinated broiler breeding flock during its peak egg laying period in China. *BMC Veterinary Research*. 2015; 11:157.
13. Gong Z, Zhang L, Wang J. Isolation and analysis of a

very virulent Marek's disease virus strain in China. *Virology Journal*. 2013; 10:155.

14. Deuchande R, Murphy A, Otter A, Baigent S, Wood A, Irvine RM. Marek's disease in turkeys. *Veterinary Record*. 2012; 171(23):602.
15. Schat KA, Nair V. Neoplastic diseases; Marek's Disease. In: Glisson LR, Dougald MC, *Diseases of poultry*. Edn. 13, John Wiley and Sons Inc., Hoboken, NJ, 2013, 515-539.