



E-ISSN: 2320-7078

P-ISSN: 2349-6800

JEZS 2019; 7(4): 1035-1037

© 2019 JEZS

Received: 09-05-2019

Accepted: 13-06-2019

SM Tamuli

Department of Pathology, CVSc,
AAU, Khanapara, Guwahati,
Assam, India

KJ Dutta

Department of Pathology, CVSc,
AAU, Khanapara, Guwahati,
Assam, India

P Konch

Department of Pathology, CVSc,
AAU, Khanapara, Guwahati,
Assam, India

K Kakoty

Division of Animal Health,
ICAR Research Complex for
NEH Region, Umroi Road,
Umiam Barapani, Meghalaya,
India

E Vise

Division of Animal Health,
ICAR Research Complex for
NEH Region, Umroi Road,
Umiam Barapani, Meghalaya,
India

S Das

Division of Animal Health,
ICAR Research Complex for
NEH Region, Umroi Road,
Umiam Barapani, Meghalaya,
India

TNU Padhyaya

Department of Pathology, CVSc,
AAU, Khanapara, Guwahati,
Assam, India

Correspondence

KJ Dutta

Department of Pathology,
CV Sc, AAU, Khanapara,
Guwahati, Assam, India

Mycobacterium tuberculosis complex (MTC) detection in a beetal goat from Assam

SM Tamuli, KJ Dutta, P Konch, K Kakoty, E Vise, S Das and TN Upadhyaya

Abstract

In the genus of *Mycobacterium* which has recently been reclassified into four different genera, *Mycobacterium tuberculosis* is the best known pathogen known to cause Tuberculosis (TB) mainly in humans and also in animals. Zoonotic tuberculosis is primarily caused by *Mycobacterium bovis* while the genetically related other members of these group known as the *Mycobacterium tuberculosis* Complex (MTC) comprising of *M. caprae*, *M. africanum*, *M. pinnipedii*, *M. canetti*, *M. mungi*, *M. microti* and *M. orygis* causes TB in several other animal species and human. A carcass of 3 year old female goat was presented in our department which was subjected for post mortem examination. The carcass was in debilitated and cachectic condition. During necropsy the lungs revealed grayish white nodular growths of various sizes. Impression smears from the cut surfaces of the nodules revealed acid fast bacilli with Ziehl Neelsen staining. Histopathology of the lung showed typical tuberculous granulomatous lesion. The tissue was subjected to molecular analysis by amplification of hsp65 gene (441 bp) for *Mycobacterium* Genus confirmation. Further, IS6110 region was targeted (123bp) for confirmation of the MTC group.

Keywords: Tuberculosis, *Mycobacterium tuberculosis* complex (MTC), Zoonosis, Goat, Tuberculous granuloma

Introduction

Pathogenic mycobacteria are known to cover a wide range of hosts. In animals, *M. bovis*, *M. avium* and *M. avium* subsp. *paratuberculosis* are the principle mycobacterial pathogens. *M. bovis* causes bovine tuberculosis and is known to be zoonotic in nature. *M. avium* and *M. paratuberculosis* are classified under opportunistic pathogens and *M. avium* is often associated with diseases in poultry and pigs, while *M. paratuberculosis* leads to Johne's disease in cattle (Gavin *et al.*, 2018) [7]. The global incidence of Tuberculosis (TB), caused by *M. tuberculosis*, in 2017, stands at 10 million new cases per 100, 000 population and India holds the highest burden of the global TB cases with approximately 2.74 million cases and 0.4 million mortality (WHO, 2018) [15]. Tuberculosis is also an important zoonotic infection caused by members of the *Mycobacterium tuberculosis* complex which affects domestic as well as wild and captive animals (Gavier-Widen, 2016). Although eradication policy of zoonotic TB was started all over the world, TB still remains endemic in most of the countries (Zanardi *et al.*, 2018). According to the census of 2012, the goat population in India stands at over 135 million contributing to important source of protein and textile resource (www.nddb.coop). Infections by members of MTC such as *M. bovis* and *M. caprae* possess a growing threat to goat farming that produces severe exudative lesions with cavitation in the lungs with significant implication for public health causing a significant economic burden (Crawshaw *et al.*, 2008., Zanardi *et al.*, 2013; Pesciaroli *et al.*, 2014) [2, 16, 9]. Being zoonotic in nature, transmission to humans mainly veterinarians, abattoir workers or livestock and crop farmers are also documented (Rodríguez *et al.*, 2009) [10]. Although there are reports on *M. bovis* infection in goat (Domingo *et al.*, 2009; Hiko *et al.*, 2011; Romha *et al.*, 2018) [4, 8, 11] documented literature of tuberculosis in goat is almost nonexistent from Assam. Report of *M. tuberculosis* and other mycobacteria from bovine is available in the region which indicates the presence of these pathogens in livestock (Vise *et al.*, 2017) [14]. The present study records a case of tuberculosis in a Beetal goat caused by *Mycobacterium tuberculosis* complex and was confirmed by path morphology, Ziehl Neelsen (ZN) staining, and molecular identification.

Materials and Methods

A three year old female Beetal goat was presented in the department of pathology, CVSc, AAU, Guwahati. A detailed post mortem examination was conducted. This involved visual inspection, palpation, incision of the carcass and internal organs. Samples of lungs, liver, kidneys, lymph nodes were examined. The organs were incised and inspected for the presence of abscess, cheesy masses and tubercles. Lung tissues suspected for TB were fixed in 10% buffered formalin for histopathology. Impression smears were taken from the incised nodule of the lungs. The heat-fixed smears were stained for observation of acid fast bacilli as per the standard protocol. For bacteriological culture confirmation, the suspected lung tissue was collected in sterile containers and processed as per earlier described (van Ingen *et al.*, 2010) [13]. Briefly, the surface of the excised lung sample was decontaminated in boiling water and triturated. The homogenized tissue was then decontaminated with 3 volume parts of 6% H₂SO₄ and centrifuged at 12000 rpm for 10 minutes. The sediment was inoculated separately in two Lowenstein Jensen (LJ) slants containing sodium pyruvate and glycerol respectively. The tubes were inoculated at 37°C for upto 8 weeks.

Simultaneously, the lung sample was subjected to molecular analysis through PCR for mycobacterial detection. DNA was extracted from the triturated lung sample using column-based tissue DNA isolation kit (D Neasy, Qiagen, USA). Initial confirmation of *Mycobacterium* genus was done using the established primers for partial amplification of the *hsp65* gene (Telenti *et al.*, 1993) [12]. Another PCR amplification was done for the *IS6110* region (Eisenach *et al.*, 1990) [5] which is known to be specific for *Mycobacterium tuberculosis* complex (MTC). Controls such as *M. bovis*, *M. tuberculosis*, *M. vaccae*, were used for these two PCR.

Result and Discussion

The Beetal goats were procured from Punjab, most of which died due to haemonchosis and enterotoxaemia. This single goat presented symptoms of tuberculosis. The goats were transported from low humid (70-75%) to high humid areas (85-90%) which due to stress might have made them susceptible to various diseases. The macroscopic feature of granulomas was characterized by the presence of dry nodules in varying sizes ranging from 0.5 to 3 mm. All the nodules almost were similar in sizes, protruding from the lung parenchyma (Figure 1). The appearance of the nodules indicated milliary tuberculosis. The color of the nodules was grayish white and consistency was hard on palpation. Upon incision of the nodules, cheese like materials with gritty substances were observed. Staining of tissue smear from lung revealed presence of rod shaped, acid fast bacilli indicating the presence of *Mycobacterium* cells (Figure 2). Microscopically, the multiple tuberculosis nodules revealed foci of eosinophilia homogenous masses of caseation with dark blue colored areas of calcification (Figure 3). A zone of cellular reaction was observed around the caseo necrotic areas. Degenerated neutrophils, macrophages, epithelioid cells and lymphocytes were admixed in the areas. The typical Langhan' stype of giant cells were evident in the lesions (Figure 4). The complete granuloma was surrounded by fibrous connective tissue capsule. Sections of lungs also revealed highly dilated and congested blood vessels, edema and emphysema in the alveoli. Although culture was attempted, isolation was unsuccessful due to gross

contamination.

Molecular investigation through PCR provided rapid confirmation of tuberculosis infection. The partial mycobacterial *hsp65* gene, also called the 'Telenti fragment' is conserved in nature and is widely used for successful mycobacterial identification (Devallois *et al.*, 1997; Brown-Elliott *et al.*, 2018) [3, 1]. The tested lung sample confirmed presence of *Mycobacterium* pathogen showing amplification at 441bp (Fig 5). To further ascertain the origin, insertional sequence *IS6110* was used for the detection of MTC as *hsp65* is unable to differentiate the members of MTC from other species of the Genus. Amplification of 123 bp (Fig 6) which confirmed the presence of MTC.

The subject of tuberculosis eradication could be compromised by non-reporting and weak surveillance of tuberculosis cases in other animals including goats. As goats are known to be susceptible to both *M. tuberculosis* and *M. bovis* alike, close observation may be necessary (Crawshaw *et al.*, 2008, Rodríguez *et al.*, 2011) [2]. Disease monitoring through immunological assays and molecular identifications are vital for understanding the epidemiology of the MTC members as the facilities for confirming through culture is not always available. Mandatory testing and slaughter policy in the country is lacking which adds to the threat of outbreak and spillovers. Strict quarantine practices along with extension activities to create of awareness remains some much needed interventions for effective prevention and control measures.

Acknowledgement

authors are grateful to the Head, Division of Animal Health, ICAR Research Complex for NEH Region, Meghalaya, for providing the facilities to carry out the work.

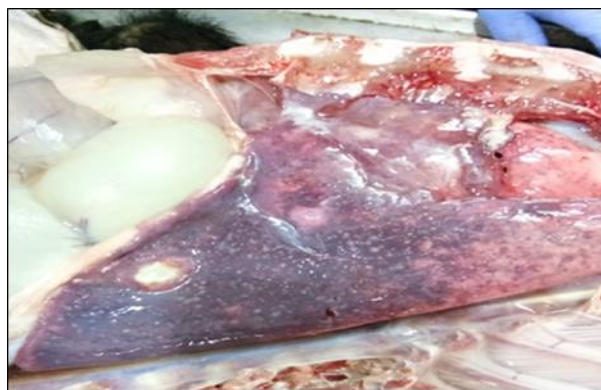

Fig 1: Greyish white nodules in the lung (.5-3mm)

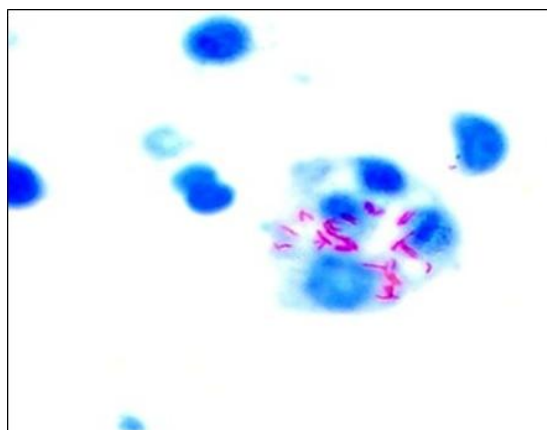


Fig 2: Demonstration of acid fast organisms in impression smear (Z-N stain)

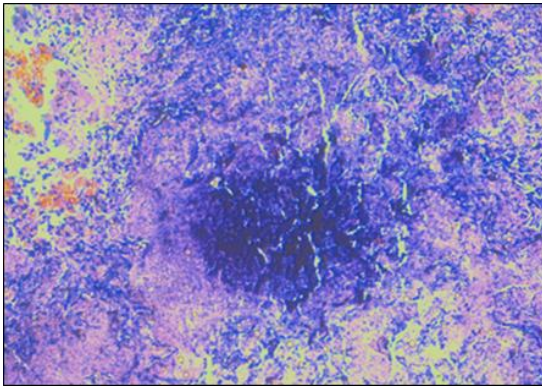


Fig 3: Lung section showing a typical granuloma with central area of calcification, H&E 20X




Fig 4: Lung section showing typical Langham's giant cells, H&E 40X

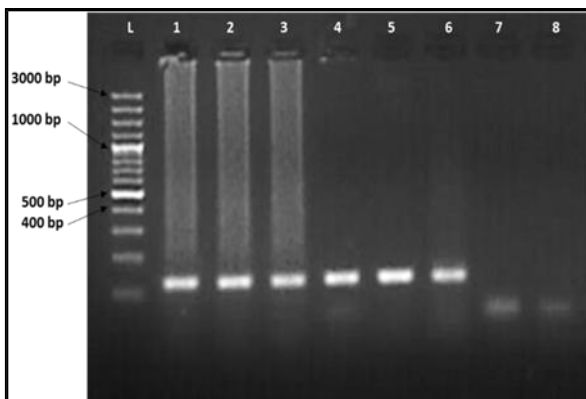


Fig 5: Genus confirmation by *hsp65* gene amplification (441bp). Lane L- Ladder (100plus bp marker). Lanes 1 to 3-Caprine lung sample; Lane 4- *M. bovis*; Lane 5&6- *M. tuberculosis*; Lane 7- *M. vaccae*; Lane 8- Negative control; Lane 9- NTC.

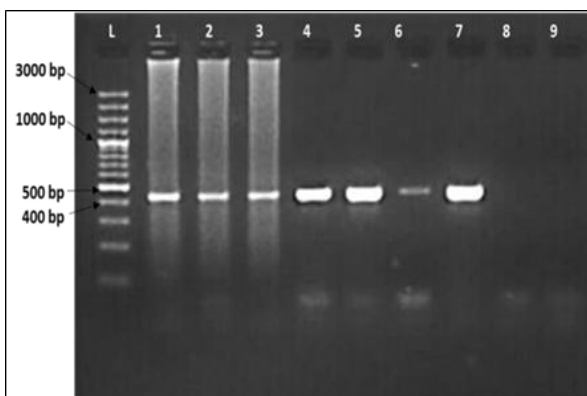


Fig 6: *Mycobacterium tuberculosis* complex (MTC) detection by IS6110 region amplification (123bp). Lane L-Ladder (100bp plus marker). Lane 1 to 3-Caprine lung sample; Lane 4- *M. bovis*; Lane 5&6- *M. Tuberculosis*; Lane 7- *M. vaccae*; Lane 8- Negative control

References

1. Brown-Elliott BA, Simmer PJ, Trovato A, Hyle EP, Droz S, Buckwalter SP *et al.* *Mycobacterium decipiens* sp. nov., a new species closely related to the *Mycobacterium tuberculosis* complex. *International journal of systematic and evolutionary microbiology.* 2018; 68(11):3557-3562.
2. Crawshaw T, Daniel R, Clifton-Hadley R, Clark J, Evans H, Rolfe S *et al.* TB in goats caused by *Mycobacterium bovis*. *Veterinary Record.* 2008; 163(4):127-127.
3. Devallois A, Goh KS, Rastogi N. Rapid identification of mycobacteria to species level by PCR-restriction fragment length polymorphism analysis of the *hsp65* gene and proposition of an algorithm to differentiate 34 mycobacterial species. *Journal of Clinical Microbiology.* 1997; 35(11):2969-2973.
4. Domingo M, Gil O, Serrano E, Guirado E, Nofrarias M, Grassa M *et al.* Effectiveness and safety of a treatment regimen based on isoniazid plus vaccination with *Mycobacterium tuberculosis* cells' fragments: field-study with naturally *Mycobacterium caprae*-infected goats. *Scandinavian Journal of Immunology.* 2009; 69:500-507.
5. Eisenach KD, Donald Cave M, Bates JH, Crawford JT. Polymerase Chain Reaction Amplification of a Repetitive DNA Sequence Specific for *Mycobacterium tuberculosis*. *Journal of Infectious Diseases.* 1990; 161(5):977-981. doi:10.1093/infdis/161.5.977
6. Gavier-Widen D. the spectrum of pathology of tuberculosis in different host species: a diagnostic challenge. *J Comp. Path.* 2016; 154:72.
7. Gavin WG, Porter CA, Hawkins N, Schofield MJ, Pollock JM. Johne's disease: a successful eradication programme in a dairy goat herd. *Veterinary Record.* 2018; 182(17):483-483.
8. Hiko A, Agga GE. First-time detection of *Mycobacterium species* from goats in Ethiopia. *Tropical Animal Health and Production.* 2011; 43(1):133-139.
9. Pesciaroli M, Alvarez J, Boniotti MB, Cagiola M, Di Marco V, Marianelli C *et al.* Tuberculosis in domestic animal species. *Research in veterinary science.* 2014; 97:78-85.
10. Rodríguez E, Sánchez LP, Pérez S, Herrera L, Jiménez MS, Samper S *et al.* Human tuberculosis due to *Mycobacterium bovis* and *M. caprae* in Spain, 2004-2007. *The International Journal of Tuberculosis and Lung Disease.* 2009; 13(12):1536-1541.
11. Romha G, Gebru G, Asefa A, Mamo G. Epidemiology of *Mycobacterium bovis* and *Mycobacterium tuberculosis* in animals: Transmission dynamics and control challenges of zoonotic TB in Ethiopia Author links open overlay panel. *Preventive Veterinary Medicine.* 2018; 158:1-17.
12. Telenti A, Marchesi F, Balz M, Bally F, Böttger EC, Bodmer T. Rapid identification of mycobacteria to the species level by polymerase chain reaction and restriction enzyme analysis. *J. Clin. Microbiol.* 1993; 31(2):175-8.
13. Van Ingen J, Wisselink HJ, van Solt-Smits CB, Boeree MJ, van Soolingen D. Isolation of mycobacteria other than *Mycobacterium avium* from porcine lymph nodes. *Veterinary microbiology.* 2010; 144(1-2):250-253.
14. Vise E, Garg A, Ghatak S, Karam A, Bhattacharjee U, Sen A *et al.* Molecular Speciation of Mycobacterial Isolates from Raw Cow Milk Reveals Predominance of *Mycobacterium chelonae*. *Proceedings of the National Academy of Sciences, India Section B: Biological Sciences.* 2018; 88(4):1623-1628.
15. WHO. Global tuberculosis report 2018. Geneva: World Health Organization, 2018. Available at www.who.int
16. Zanardi G, Boniotti MB, Gaffuri A, Casto B, Zanon M, Pacciarini ML. Tuberculosis transmission by *Mycobacterium bovis* in a mixed cattle and goat herd. *Research in Veterinary Science.* 2013; 95:430-433.