



E-ISSN: 2320-7078

P-ISSN: 2349-6800

JEZS 2020; 8(1): 1041-1043

© 2020 JEZS

Received: 06-11-2019

Accepted: 10-12-2019

**R Divisha**

Veterinary Consultant,  
Kanchipuram, Tamil Nadu,  
India

**C Soundararajan**

Department of Veterinary  
Parasitology, Madras Veterinary  
College, Tamil Nadu Veterinary  
and Animal Sciences University,  
Chennai, Tamil Nadu, India

**M Arul Prakash**

Post Graduate Research  
Institute in Animal Sciences,  
Kattupakkam, TANUVAS,  
Kanchipuram, Tamil Nadu,  
India

## Therapeutic management of concurrent Sarcoptic and Psoroptic mange infestation in rabbits

**R Divisha, C Soundararajan and M Arul Prakash**

**Abstract**

Thirty-six adult male New Zealand White rabbits were infested with mange at a private rabbit farm in Kanchipuram district, Tamil Nadu. Microscopically examined skin scrapings showed many mites and ova of *Sarcoptes scabiei* and *Psoroptes cuniculi*. Based on the site of lesions, the mange infested rabbits were grouped into three as Group I – lesions on body, Group II – lesions on ear and Group III – lesion on legs, each consisting of 10 rabbits. All the groups were treated with Ivermectin @ 0.4mg/kg b.wt. subcutaneously at weekly intervals for 4 weeks and topical application of 25% benzyl benzoate every day. Complete recovery was noticed after 18<sup>th</sup> day, 22<sup>nd</sup> day and 28<sup>th</sup> day on ears, legs and body, respectively.

**Keywords:** *Mange infestation*, *Sarcoptes*, *Psoroptes*, rabbit, ivermectin

**Introduction**

Scabies caused by burrowing and non-burrowing mites, is a major constraint in large rabbit colonies due to prevailing extreme humid conditions <sup>[1]</sup>. Among the various species of mites identified, the *Sarcoptes scabiei* is one which burrows deep into the epidermis causing pruritus with crust formation, thickening and wrinkling of skin in affected areas <sup>[2, 3]</sup>. *Psoroptes cuniculi*, the common ear mite of rabbits is known to cause ear canker and extra-auricular mange characterized by erythema, crusting, ulceration of the pinnae and pruritus spreading over the body <sup>[4, 5]</sup>. The mite infestations are contagious and cause huge mortality in young and debilitated animals <sup>[6]</sup>. Both Sarcoptic and Psoroptic mange are common in rabbits and difficult to eliminate completely <sup>[7]</sup>. Clinically, ivermectin has been used to control mange infestation in rabbits <sup>[8, 9]</sup>. The present report deals with the incidence of Sarcoptic and Psoroptic mange in intensively reared rabbits and its therapeutic management.

**Materials and Methods**

A total of 36 rabbits from a private rabbit farm at Kanchipuram, Tamil Nadu showed mange lesions with an itchy skin, painful crusty ears and alopecia on loin and saddle regions. Clinical examination revealed thickened crusts on ear margins, limbs and dry scales on the back region (body). Improper husbandry was noticed in the animal environment. Skin scrapings from ears, limbs, back and tail regions were collected and treated with 10% sodium hydroxide before microscopical examination <sup>[10]</sup>. Following confirmatory diagnosis, the mange infested rabbits were grouped based on the site of lesions into Group I – lesions on body, Group II – lesions on ear and Group III – lesions on legs, each consisting of 10 rabbits, and treated with 1% Ivermectin @ 0.4 mg/kg b.wt. subcutaneously at weekly intervals for 4 weeks. 25% benzyl benzoate lotion was topically applied once daily. Vitamin B complex supplements were administered orally as supportive therapy.

**Results**

Prior to treatment, a detailed clinical examination of the affected rabbits revealed severe crusty lesions on the margins of pinnae, flaky scales, sores and alopecia on the back region with dry pruritic skin. The rabbits which were housed in poor living conditions with lack of proper nutrition exhibited irregular head shaking due to unmanageable itching. The affected rabbits were isolated from other rabbits owing to the contagiousness of the infestation between affected and healthy animals. Microscopically examined skin scrapings showed numerous mites of *Sarcoptes scabiei* and *Psoroptes cuniculi* (Plate 1).

Subcutaneous injection of Ivermectin and topical application of Benzyl benzoate were initiated

**Corresponding Author:****R Divisha**

Veterinary Consultant,  
Kanchipuram, Tamil Nadu,  
India

along with supportive therapy. Complete recovery was noticed after 18<sup>th</sup> day, 22<sup>nd</sup> day and 28<sup>th</sup> day on ears, legs and body, respectively. The rabbits showed a marked clinical improvement from 2<sup>nd</sup> week onwards with lesions reducing on ears, legs and body. The dry crusts started disappearing by the 3<sup>rd</sup> week and complete recovery was noticed on the body after 4 weeks of treatment. Anorexia and alopecia were fully resolved with disappearance of scales, itchy skin and hair growth (Plate 2).

### Discussion

The Psoroptic mange caused by *Psoroptes cuniculi* is more common in rabbits than the *Sarcoptes scabiei* var. *cuniculi* infestation [11]. While *Psoroptes* live in the external auditory canal causing ear canker in rabbits [12], the *Sarcoptes* produce mechanical damage and irritation to the skin due to allergic reactions induced by its secretions or extracellular products such as interleukin-I (IL-1) [13]. Some earlier reports by Soundararajan and Iyue [14] and Panigrahi *et al.*, [15] revealed mixed infestation of *Sarcoptes* and *Psoroptes* spp in rabbits. The infested rabbits could have possibly had an impaired immune status, as crusted scabies usually occurs with

impaired-cell mediated immunity [16]. Factors like relocating, early weaning, sudden change in diet, improper handling, inappropriate husbandry such as small sized cage, overcrowding, infrequent changing of bedding and high humidity could also contribute to their immunosuppression.

Treatment with Ivermectin @400µg/kg b.wt at weekly intervals is effective against Sarcoptic mange [17]. The drug acts by selectively binding to glutamate-gated and gamma-amino-butyric-acid (GABA) gated chloride channels in the nervous system of mites causing paralysis and death of the mites [18, 19]. In naturally infested rabbits, a single dose of long acting Ivermectin (3.15% w/v) at 700 mcg/kg b.wt was reported to be appropriate in completely eliminating *Sarcoptes scabiei* mites [20]. Benzyl benzoate which exerts its toxic effects on mite ova is an alternative agent for topical treatment of scabies [21]; it was applied diluted to reduce irritation on dented skin. Appropriate topical dosage of benzyl benzoate has a comparatively lower order of toxicity except local irritation and allergic skin sensitivity; hence its prolonged use can cause contact dermatitis [22]. Disinfection of rabbit cages and surroundings with blow lamp is said to be effective in controlling mite infestation in rabbits [23].

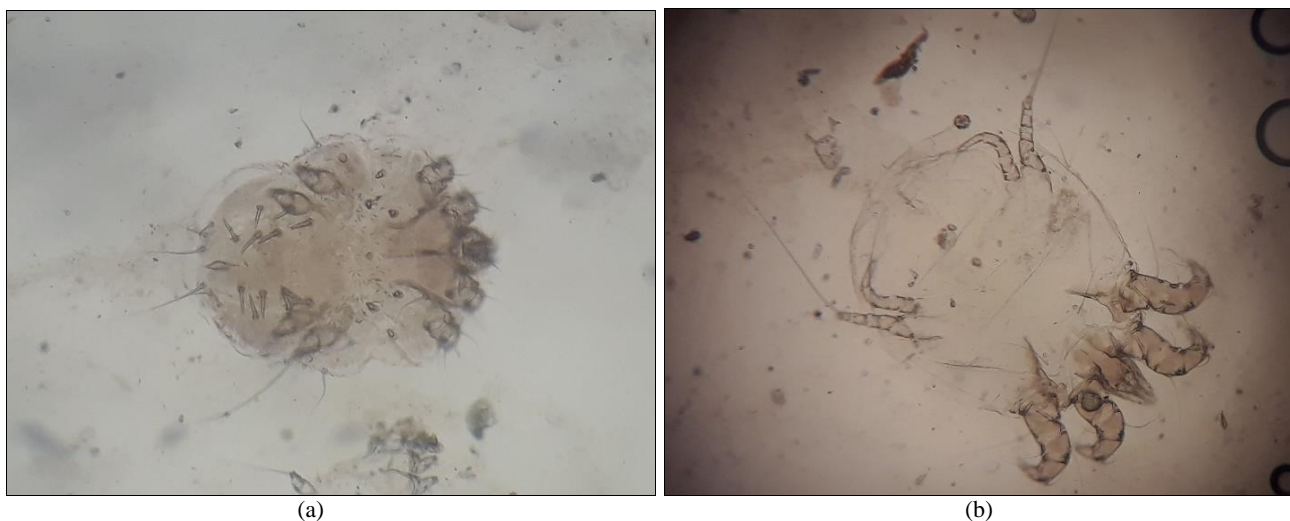


Plate 1: a) *Sarcoptes scabiei* and b) *Psoroptes cuniculi* mites from skin scrapings

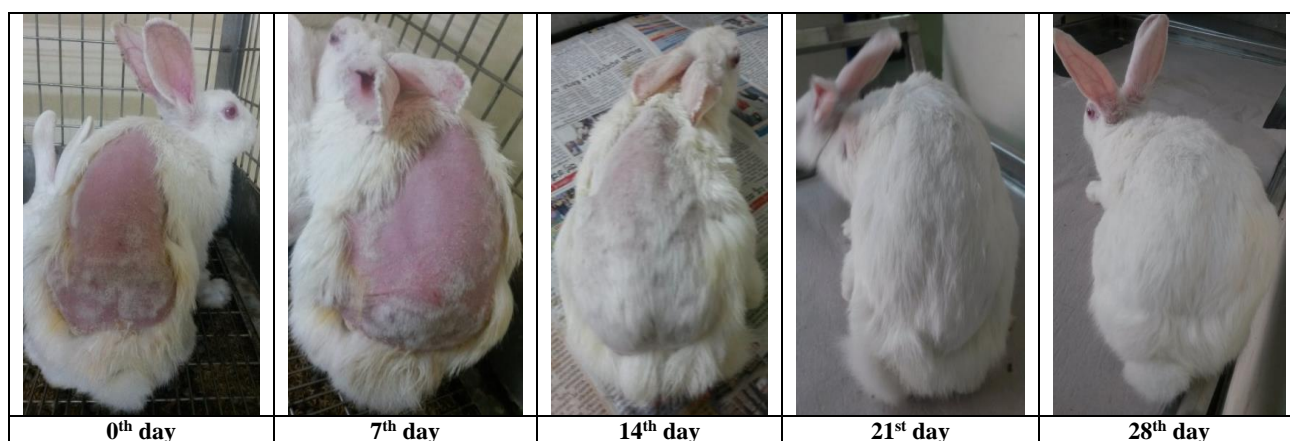


Plate 2: Skin and ear lesions of mite infested rabbits before and after treatment

### Conclusion

Conclusively, isolation of mite infested rabbits, treatment with ivermectin, topical application of benzyl benzoate on regions of alopecia, and improving management practices can effectively control mange in rabbits.

### References

1. Prakash MA, Soundararajan C, Nagarajan K, Tensigh P, Ramesh VS. Sarcoptic mange infestation in rabbits in an organized farm at Tamil Nadu. Journal of Parasitic Diseases. 2017; 41(2):429-432.

2. Hendrix C, Robinson Ed. Diagnostic Parasitology for Veterinary Technicians 4<sup>th</sup> Edition, 2012.
3. Larry GA, Morgan MS. A review of *Sarcoptes scabiei*: past, present and future Parasites & Vectors. 2017; 10:29.
4. Kyung-Yeon E, Oh-Deog K. Psoroptic Otocariasis associated with *Psoroptes cuniculi* in Domestic Rabbits in Korea, Pakistan Veterinary Journal. 2010; 30(4):251-252.
5. Swarnakar G, Sharma D, Sanger B, Roat K. Infestation of ear mites *Psoroptes cuniculi* on farm rabbits and its anthroponosis in Gudli village of Udaipur Dt, India. International Journal of Current Microbiology & Applied Biosciences. 2014; 3(3):651-656.
6. Bornstein SMT, Samuel WM. Parasitic diseases of wild mammals. Iowa State University Press, Ames, Iowa, 2001, 107-119.
7. Aiello SE. Merck Veterinary Manual. New Jersey, Merck, Inc, 1998, 1386-96.
8. Soundararajan C, Iyue M. Comparative efficacy of anti-parasitic agents in the treatment of mange in rabbits. The Indian Journal of Field Veterinarians. 2006; 1(3):19-20.
9. Sharun K, Anjana S, Sidhique SA, Panikkassery S. Treatment of Sarcoptic mange infestation in rabbits with long acting injectable ivermectin. Journal of Parasitic Diseases. 2019; 43(4):733-736.
10. Soulsby E.J.L. Helminths, Arthropods and protozoa of domesticated animals. 7<sup>th</sup> edn. ELBS. BailliersTindall. London 1982, 490.
11. Radi ZA. Outbreak of sarcoptic mange and Malasseziasis in rabbits (*Oryctolagus cuniculus*). Comparative Medicine. 2004; 54(4):434-7.
12. Bulliot C, Mentre V, Marignac G, Bruno P, Rene C. A case of atypical Psoroptic mange in a domestic rabbit. Journal of Exotic Pet Medicine. 2013; 22(4):400-404.
13. Wall R, Shearer D. Veterinary Entomology. 1<sup>st</sup>ed. Chapman and Hall, London, 1997.
14. Soundararajan C, Iyue M. Incidence of mange infestation in rabbits. Journal of Veterinary Parasitology. 2005; 19(2):161-162.
15. Panigrahi PN, Mohanty BN, Gupta AR, Patra RC, Dey S. Concurrent infestation of Notoedres, Sarcoptic and Psoroptiacariosis in rabbit and its management. Journal of Parasitic Diseases. 2016; 40(3):1091-1093.
16. Hengge UR, Currie BJ, Jäger G, Lupi O, Schwartz RA. Scabies: a ubiquitous neglected skin disease. Lancet Infectious Diseases. 2006; 6:769-779.
17. Panigrahi PN, Gupta AR. Therapeutic management of concurrent Sarcoptic and Psoroptic acariasis in rabbits. Intas Polivet. 2013; 14(11):319- 321.
18. Lovell RA. Ivermectin and piperazine toxicoses in dogs and cats. Veterinary Clinics of North America Small Animal Practice. 1990; 20:453-68.
19. Aulakh GS, Singla LD, Singla N. Pathology and therapy of natural Notoedric acariasis in rabbits. Journal of Veterinary Parasitology. 2003; 17:127-129.
20. Ayodhya S. Ear canker and its clinical management in Rabbits. International Journal of Current Microbiology and Applied Biosciences. 2013; 2(11):66- 71.
21. Larranaga MD, Lewis RJ, Lewis RA. Hawley's Condensed Chemical Dictionary 16<sup>th</sup> Edn, Wiley and Sons, 2016, 159.
22. Bethesda MD. American Society of Health-System Pharmacists Clinical Drug Information, 2018.
23. Darzi MM, Mir MS, Shahardar RA, Pandit BA. Clinicopathological, histochemical and therapeutic studies on concurrent Sarcoptic and Notoedric acariasis in rabbits (*Oryctolagus cuniculus*). Veterinarski Arhiv. 2007; 77:167-75.