Journal of Entomology and Zoology Studies

Available online at www.entomoljournal.com

E-ISSN: 2320-7078
P-ISSN: 2349-6800
www.entomoljournal.com
JEZS 2020; 8(2): 39-42

Received: 25-01-2020
Accepted: 27-02-2020

S Senthilkumar
PhD Scholar, Dept. of Veterinary Anatomy, Madras Veterinary College, Chennai, Tamil Nadu, India

TA Kannan
Professor, Dept. of Veterinary Anatomy, Madras veterinary College, Chennai, Tamil Nadu, India

R Gnanadevi
Assistant professor, Dept. of Veterinary Anatomy, Madras Veterinary College, Chennai, Tamil Nadu, India

Geetha Ramesh
Professor and Head, Dept. of Veterinary Anatomy, Madras Veterinary College, Chennai, Tamil Nadu, India

C Balan
Assistant Professor, Dept. of Animal Husbandry Statistics and Computer Applications, Madras veterinary College, Chennai, Tamil Nadu, India

Corresponding Author:
S Senthilkumar
PhD Scholar, Dept. of Veterinary Anatomy, Madras Veterinary College, Chennai, Tamil Nadu, India

Gross morphometric findings of udder and teat in madras red ewes

S Senthilkumar, TA Kannan, R Gnanadevi, Geetha Ramesh and C Balan

Abstract
The objective of the present study was to assess the morphology and morphometric measurements in lactating and non-lactating (n=15 each) Madras Red ewes. In both the groups, udder was located in the inguinal region. It consisted of two mammary glands (right and left halves) divided by an intermammary groove and each had a single teat. In Madras Red ewes, udder circumference (UC) and inter-teat distance (ITD) showed statistically significant difference between lactating and non-lactating ewes. Udder length (UL), width of right (R-UW) and left (L-UW) quarter, udder thickness (UT), Right and left teat length (TL), teat diameter at base (TDB), teat diameter at tip (TDT), teat to floor distance (TFD), teat end to floor distance (TEFD) does not shown any statistical difference between lactating and non-lactating animals.

Keywords: Madras red ewe, gross morphometry, udder, teat

Introduction
The small ruminant sector plays an important role in the rural economy at the national level. They have a significant role in ensuring food and nutritional security for the families of millions of poor households. As a mean of income and employment generation for these households, rearing of small ruminants helps in alleviating poverty and regularizes income distribution[1]. Madras Red sheep (*Ovis aries*) is a medium-sized meat type breed, native to the Kanchipuram and Madras districts of Tamil Nadu. Their Udder is medium in size and demarcated from the body with well-defined teats [2]. It develops during pregnancy and early lactation and regresses very quickly after dry-off [3]. The udder traits are highly useful in selecting the dams for breeding programmes and also helpful in assessing the quality characters in udder and teat. The present study was aimed to assess the udder morphology and morphometric traits in lactating and non-lactating Madras Red ewes that are rearing in semi-intensive system.

Materials and Methods
Morphological study
For the gross morphological study, udder samples (n=6 each) were collected from adult, healthy Madras Red ewes brought to corporation slaughter house, Chennai. After collection, samples were fixed in 10 per cent neutral buffered formalin. Morphological observations of gland and teat cistern were performed by dissecting the glands after a fixation period of 48 hours.

Morphometric study
Udder
The gross morphometric measurements of udder and teat were taken from thirty healthy Madras Red ewes. Animals were divided into two groups based on physiological status as lactating and non-lactating (n=15 each) group. The gross anatomical parameters of mammary gland such as udder length (UL) (from base of the gland to the base of the teat along the intermammary groove, width of right (R-UW) and left (L-UW) quarter (distance between two lateral borders of the gland to the intermammary groove), udder thickness (UT) (the distance between cranial and caudal borders of the gland at base) and udder circumference (UC) at base were measured using measuring tape [4].

Teat

The gross anatomical parameters of teats *viz*., (TL) teat length (distance between base and tip), teat diameter at base (TDB), teat diameter at tip (TDT), the inter-teat distance (ITD) at the base was measured using a measuring tape and vernier caliper [4]. (TDB) Teat to floor distance (distance between the bases of the teat to the ground) and (TEFD) teat end floor distance (distance between the tip of the teat to the ground) for both right and left teats was recorded by using measuring tape [5].

Data analysis

The data and measurements of all specimens were recorded and analysed by using SPSS software to calculate mean and standard deviation [15].

Results and Discussion

Morphology - Udder

In the present study, the udder was located in the inguinal region in both the groups of ewes. It consisted of two mammary glands (right and left halves) and each had a single teat. Externally, the mammary groove indicated the division of udder into two mammary glands. The division was more distinct in lactating ewes when compared to non-lactating ewes. Each half was located on either side of the mid-ventral line and was found to be symmetrical. Each gland was covered by the skin which was continuous with the skin covering the mid-ventral aspect of the inguinal region. In ewes, fleece covering the mammary gland skin were coarser and denser at the base of the gland which gradually became thinner and less dense towards the base of the teat. These findings were similar to the observations made by Turner, Small wood in sheep [6, 7] and goat and Dyce in ruminants [8]. The differences in the external appearance might be due to breed variation.

Teat

In the present study, each mammary gland was continuous with a single teat. Each teat consisted of three parts such as base, body and apex / tip of the teat. Teat cistern within the body of the teat was a direct continuation of the gland cistern. Distally the teat cistern continued as the narrow passage - streak canal which opened externally through the teat orifice. The teat was shorter and less cylindrical in ewes, the skin was firmly attached with the underlying smooth muscle layer and possessed fine hairs along the entire length of the teat except the tip. The tip of the teat showed a single teat orifice and pointed in ewes.

Gland and teat cistern

In the present study, each mammary gland consisted of a wide pouch-like gland cistern with irregular outline, numerous lactiferous ducts opened into this gland cistern. The size and shape of the gland cistern varied between individuals as observed in cows [9]. The gland cistern continued distally as single teat cistern in each teat. The mucosa lining the teat cistern showed fine longitudinal folds in both the species. This is in total agreement with the findings of Atyia in small ruminants [10]. Teat cistern continued as a narrow teat canal / streak canal / ductus papillaris (Fig 1) which opened through a single teat orifice. Size of the teat cistern was found to be smaller in ewes [7]

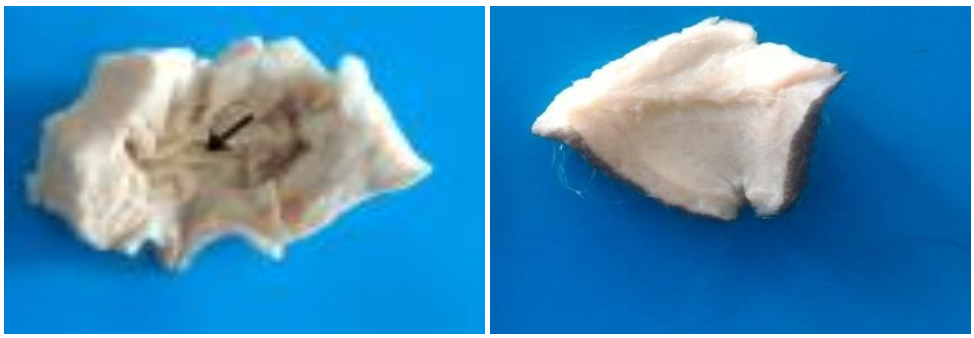

Fig 1: Photograph of the udder (left) showing gland cistern (arrow) and teat (right) in Madras Red ewe

Morphometry

Gross morphometric parameters such as UT (cm), UL (cm), R-UW (cm), L-UW (cm) and UC (cm), ITD (cm), R-TFD (cm), L-TFD (cm), R-TEFD (cm), L-TEFD (cm), R-TL (cm), L-TL (cm), R-TDB (cm), L-TDB (cm), R-TDT (cm), L-TDT (cm) were recorded in lactating and non-lactating Madras Red ewes were given in Table 1. Of these parameters, a highly significant difference ($P \leq 0.01$) was observed in UC between lactating (24.85 ± 0.82) and non-lactating (20.41 ± 0.96) groups in ewes. These findings were in agreement with the Martinez in Chilota [11] and Suffolk Down sheep breeds, Abu in West African Dwarf goats [12] and Upadhyay in local goats of Rohilkhand [13]. This might be due to increased udder volume during lactation in globular shaped udder of Madras Red ewes. No significant difference was observed in udder thickness (UT) between lactating and non-lactating groups, which is in accordance with the findings of Paramasivan in ewes [14]. In this study, udder length in Madras Red ewes revealed no significant difference between both the groups. The udder length in lactating ewes was found to be lesser in in Manchega, Lacaune breeds [2] and Chilota, Suffolk Down breeds [9]. No significant difference was observed in UW-R and UW-L between lactating and non-lactating groups. A similar observation was made West African Dwarf goats reared under semi-intensive system [12].

Table 1: Mean ± SE of various gross morphometric measurements in the udder of Madras Red ewes

Parameters (cm)	Mean ± SE		t value
	Lactating (N=15)	Non-lactating (N=15)	
UT	10.07 ± 0.53	8.25 ± 0.78	1.96^{NS}
UL	12.35 ± 0.74	12.0 ± 1.02	0.28^{NS}
R-UW	6.72 ± 0.59	5.60 ± 0.19	1.67^{NS}
L-UW	7.00 ± 0.53	5.83 ± 0.45	1.62^{NS}
UC	24.85 ± 0.82	20.41 ± 0.96	3.50**
ITD	8.85 ± 0.40	7.30 ± 0.43	2.63*
R-TFD	39.64 ± 1.10	38.66 ± 0.42	0.77^{NS}
L-TFD	39.71 ± 1.52	37.83 ± 0.58	1.07^{NS}
R-TEFD	36.92 ± 0.99	36.26 ± 0.51	0.55^{NS}
L-TEFD	35.64 ± 1.97	35.40 ± 0.56	0.11^{NS}
R-TL	2.71 ± 0.18	2.4 ± 0.13	1.32^{NS}
L-TL	2.64 ± 0.14	2.43 ± 0.22	0.79^{NS}
R-TDB	1.23 ± 0.90	1.14 ± 0.80	0.74^{NS}
L-TDB	1.08 ± 0.03	1.89 ± 0.07	1.29 ^{NS}
R-TDT	0.60 ± 0.03	0.67 ± 0.06	0.97^{NS}
L-TDT	0.48 ± 0.04	0.53 ± 0.06	0.62^{NS}

^{NS} - No significant difference between lactating and non-lactating groups ($P \geq 0.05$)
* - Significant difference between lactating and non-lactating groups ($P \leq 0.05$)
* - Highly significant difference between lactating and non-lactating groups ($P \leq 0.01$)

In Madras Red ewes, the inter teat distance showed a significant difference between lactating and non-lactating groups. In lactating ewes, an increased ITD (8.85 ± 0.40) was recorded. This is in accordance with the findings in Manchega and Lacaune sheep breeds [2]. Who reported that the distance between teats did not show any changes in the first six week of lactation, and after that size of the teat and inter teat distance reduced after the weaning of lambs (non-lactating stage). This suggested that the productive capacity of the ewe is related to the distance between teats. No significant difference ($P \geq 0.05$) recorded in teat length (both right and left) between lactating and non-lactating animals. In both lactating and non-lactating groups, the teat floor distance revealed no significant difference. These findings were in total agreement with the findings in West African Dwarf goats [12]. No significant difference was observed in teat end floor distance between lactating and non-lactating groups of ewes. This is in agreement with the earlier findings in cows [5]. No significant difference ($P \geq 0.05$) was observed in right teat diameter at base (R-TDB), left teat diameter at base (L-TDB), right teat diameter at tip (R-TDT) and left teat diameter at tip (L-TDT) between the lactating and non-lactating animals [14].

Conclusion

It is concluded that that lactating Madras Red ewes showed more (UC) udder circumference and ITD (Inter teat distance) than the non-lactating ewes. Width of right (R-UW) and left (L-UW) udder, udder thickness (UT), teat length (TL), teat diameter at base (TDB), teat diameter at tip (TDT) does not differ between lactating and non-lactating animals.

References

1. Karim SA, Joshi A, Sankhyan SK, Shinde AK, Shakyawar DB, Naqvi SMK *et al*. Climate change and stress management: sheep and goat production, Sathish Serial Publishing House, Delhi. 2010, 691.
2. Rovai M, Such X, Piedrafita J, Caja G, Pujol MR. Evolution of mammary morphology traits during lactation and its relationship with milk yield of Manchega and Lacaune dairy sheep. In: Milking and milk production of dairy sheep and goats. EAAP Publication, Wageningen Pers, Wageningen. 1999, 107-109.
3. Caja G, Such X, Rovai M. Udder morphology and machine milking ability in dairy sheep. Unitat de Produccio Animal. 2001, 1-24.
4. Paramasivan S. Gross anatomical and histomorphological studies on hypothalamo-hypophysio-mammary axis of sheep (*Ovis aries*). (Ph.D thesis), TANUVAS – Chennai, India. 2007, 45-46.
5. Venkatesan M. Evaluation of milk flow disorders and associated mastitis status in dairy cattle. (M.V.Sc thesis), Chennai, India. 2017, 74.
6. Turner CW. The mammary gland - The Anatomy of the udder of cattle and domestic animals. Lucas brothers Publishers, Columbia. 1952, 35.
7. Smallwood JG. A Guided Tour of Veterinary Anatomy. W.B. Saunders Company. 1993, 109-112.
8. Dyce KM, Sack WO, Wensing CJG. Textbook of Veterinary Anatomy. 3rd edition., Saunders Elsevier, USA. 2002, 723-731.
9. Yogita P, Taluja JS, Vaish R, Pandey A, Gupta N, Kumar D. Gross anatomical structure of the mammary gland in cow. Journal of Entomology and Zoology Studies. 2018; 6(4):728-733.
10. Atyia MA. Anatomical, histological and radiographical study of the mammary gland of small ruminants. Bas J Vet Res. 2009; 8(2):10-22.
11. Martinez E, Calderon C, Barra RDL, Fernando de la fuente L, Gonzalo L. Udder morphological traits and milk yield of chilota and Suffolk down sheep breeds. Chilean journal of agricultural research. 2010; 71(1):90-95.
12. Abu AH, Mhomga LI, Akogwu EI. Assessment of udder characteristics of West African Dwarf (WAD) goats reared under different management systems in Makurdi, Benue State, Nigeria. African journal of agricultural research. 2013; 8(25):3255-3258.
13. Upadhyay D, Patel BHM, Kerketta S, Kaswan S, Sahu S, Bhushan B *et al*. Study on udder morphology and its relationship with production parameters in local goats of Rohilkhand region of India. Indian journal of veterinary research. 48(6): 615-619.
14. Paramasivan S, Geetha Ramesh, Ushakumary S, Basha

SH, Kannan TA and Kumaravel A. Gross and microscopic anatomy of teat in Madras Red sheep. Indian veterinary journal. 2013; 90(4): 44-47.
15. Senthilkumar S, Gnanadevi R, Kannan TA, Arunaman CS and Geetha Ramesh. Microanatomical observations of hair in domestic animals: A comparative study. Journal of Entomology and Zoology Studies. 2018; 6(5):1925-1929.