



E-ISSN: 2320-7078

P-ISSN: 2349-6800

www.entomoljournal.com

JEZS 2020; 8(2): 1113-1114

© 2020 JEZS

Received: 16-01-2020

Accepted: 18-02-2020

Abhinav Kumar Reddy G

M.V.Sc Scholar, Department of
Veterinary Medicine, College of
Veterinary Science,
Rajendranagar, Hyderabad,
Telangana State, India

Ambica G

Assistant Professor, Department
of Veterinary Medicine, College of
Veterinary Science,
Rajendranagar, Hyderabad,
Telangana State, India

Babji BR

M.V.Sc Scholar, Department of
Veterinary Medicine, College of
Veterinary Science,
Rajendranagar, Hyderabad,
Telangana State, India

Satish Kumar K

Professor & University Head,
Department of Veterinary
Medicine, College of Veterinary
Science, Rajendranagar,
Hyderabad, Telangana State,
India

Corresponding Author:**Abhinav Kumar Reddy G**

M.V.Sc Scholar, Department of
Veterinary Medicine, College of
Veterinary Science,
Rajendranagar, Hyderabad,
Telangana State, India

Therapeutic management of sarcoptic mange in a rabbit: A case presentation

Abhinav Kumar Reddy G, Ambica G, Babji BR and Satish Kumar K

Abstract

Dermatological problems are one of the most common clinical entities in domestic pets especially rabbits are highly susceptible to sarcoptic mange. A rabbit of 6 months age was presented to Veterinary Clinical Complex, Rajendranagar, Hyderabad with the complaint of anorexia, dullness, generalized alopecia and intense itching with erythematous and dry crusty lesions on both ear margins and was not dewormed regularly. Routine clinical examination revealed normal temperature, pulse and respirations. The case was suspected for mites and deep skin scraping were taken from ear and analysed for presence of mites and was found positive for *Sarcoptes scabiei* mites. Rabbit was treated with the subcutaneous injection of Ivermectin two doses at weekly interval along with topical Ascabiol lotion application twice daily over the lesions. Rabbit also received treatment with antihistamines, vitamin supplements and was started showing improvement from day two onwards and recovered completely by two weeks without any presence of skin lesions and the recovery was confirmed by negative result of deep skin scrapping from ear.

Keywords: Rabbit, Intense itching, sarcoptic mange, ivermectin and Ascabiol lotion

Introduction

Dermatological problems are one of the most common clinical entities in domestic pets and fur bearing animals [1] and among them, Sarcoptic mange is a highly contagious, non-seasonal, pruritic skin condition in rabbits and is caused by mite *Sarcoptes scabiei*. Overcrowded living conditions and poor hygiene are significant factors for infection with *Sarcoptes scabiei* mites [2] and is frequently found on the sparsely haired parts of the body such as the face, ears and legs [3], causing intense itching, pruritus, crust formation, scale production, thickening and wrinkling of skin of affected area [4]. It is most obstinate, persistent and zoonotically important contagious disease [5]. The traditional treatment of sarcoptic mange includes external application of organophosphates, pyrethroid compounds or Amitraz, but its use may be problematic in that it needs frequent and careful application and may have side effects. The Avermectin drug group includes ivermectin, abamectin, doramectin, eprinomectin and selamectin which can be used to treat rabbits that are naturally infested with *Sarcoptes scabiei* and because of its long acting effect and easier to apply have therefore replaced the conventional dips, rinses and aerosol sprays [3, 6]. Ivermectin is used as a broad spectrum parasiticide in domestic animals and is also recommended for treatment of ear mange in rabbits [7].

History and Clinical Examination

A non-descript rabbit was presented to Veterinary Clinical Complex, College of Veterinary Science, Rajendranagar, Hyderabad, Telangana with the history of dullness, anorexia, skin lesions and intense itching of ears. Routine clinical examination revealed normal temperature, pulse and respiration. Detailed clinical examination revealed erythema, alopecia on ears with white indurate dry crust like lesions on ears pinna was observed (Fig.1). Confirmatory diagnosis was done by deep skin scrapping examination as per the standard method [8]. Sample of skin scrapping was collected aseptically from affected sites in 10% potassium hydroxide solution. The mixture was boiled for 10 minutes to digest the skin epithelium and was centrifuged after cooling. Supernatant fluid was discarded and few drops of sediment were placed on a glass slide for direct microscopic examination. Under 10 X magnification, the examination of samples revealed the presence of *Sarcoptes scabiei* mange mites (Fig.2).

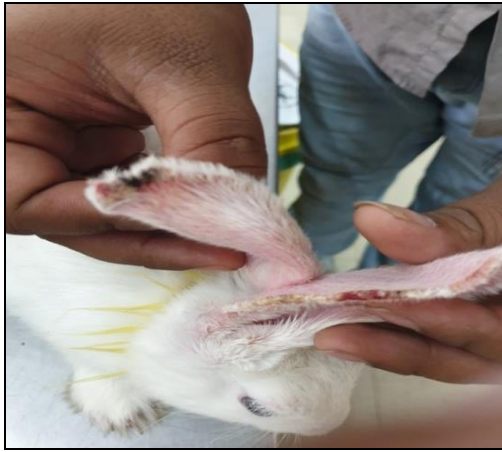

Fig 1: Picture showing severe dry crusty

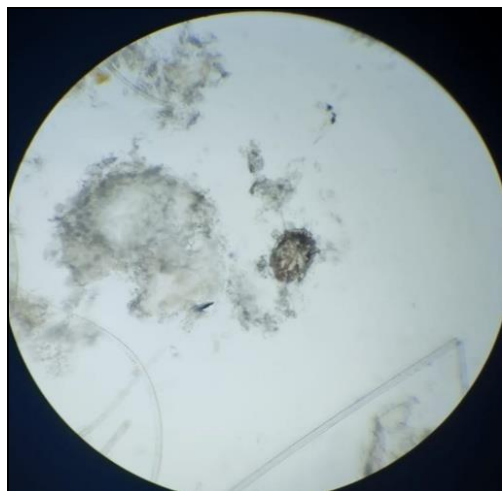


Fig 2: *Sarcoptes* spp. under microscope. lesions on ears.

Treatment and discussion

The affected rabbit was treated with Injection Ivermectin @ 400 µg/kg body weight subcutaneously weekly interval for two weeks, topical application of Ascabiol lotion regularly twice a day for 2 weeks, Injection ADE-VIT @ 0.2 ml intramuscularly on first day and was repeated thrice on alternate days in half doses, Injection Melonex @ 0.3mg/kg body weight intramuscularly and Injection Chloril @ 0.5mg/kg body weight intramuscularly. Rabbit started recovering from second day onwards. There was marked improvement in skin condition with hair growth in previously infested areas and the signs of alopecia and itching were also resolved completely after two weeks. Again skin scrapings were taken and examined and tested negative for the mites.

Mange caused by *Sarcoptes* species is more common in rabbits and diagnosis is usually confirmed by microscopic skin scraping examination. Demonstration of mange under microscope along with skin lesions was sufficient for confirmatory diagnosis of sarcoptic mange [4]. Clinical manifestations such as development of scales, scabs, crusts and alopecia along with *Sarcoptes scabiei* below crusts as observed in present study were in accordance with the previous findings [3, 9]. Ivermectin, at a dosage of 0.2-0.4 mg/kg of body weight administered subcutaneously once every 2 weeks for 2-3 treatments is usually a simple, safe, effective treatment [4, 8]. Treatment was carried out with Ivermectin @ 400 µg/kg body weight, subcutaneously at weekly interval for three weeks was found to be effective in treating sarcoptic mange as per the previous studies [3, 5].

Also reports suggested that Ivermectin given @ 400 µg/kg body weight subcutaneously was an effective treatment for the sarcoptic mange [8, 10, 12]. Ivermectin given subcutaneously selectively binds to glutamate gated and gamma-aminobutyric acid (GABA) gated chloride channels in the mites nervous system, resulting in hyper polarization of cells, paralysis and finally death of mites [13]. Hence, the present clinical case indicates ivermectin therapy coupled with external application of Ascabiol lotion along with supportive treatment is effective in treating mange in rabbits.

Conclusion

In the present clinical case, it is concluded that *Sarcoptes scabiei* mange in rabbit has a major constraint and characterized by intense pruritus, alopecia along with the skin lesions mostly over the ears. Rabbit sarcoptic mange can be treated successfully with ivermectin as weekly injection given two weeks along with topical application of Ascabiol lotion along with other supportive medications with antihistamines and vitamin supplementation.

References

1. Deshmukh VV, Varshney JP, Chaudhary PS, Desai SN. Clinical management of scabies in rabbit bunnies. *Intaspolivet*. 2010; 11:112-114.
2. McCarthy J, Kemp D, Walton S, Currie B. Scabies: more than just an irritation. *Postgrad. Med. J.* 2004; 80:382-87.
3. Kaplaywar S, Jyothi J, Murthy Srinivasa GS. Resolving Sarcoptic mange infection in a New Zealand white rabbit. *The Pharma Innovation Journal*. 2017; 6(11):641-642.
4. Singh B, Gupta D, Tiwari A, Shukla PC. Therapeutic management of sarcoptic mange in rabbit- A case Report. *G.J.B.B.* 2017; 6(2):398-399.
5. Kumar P, Sahay MN, Sinha VK, Samantaray S. Comparative efficacy of the some acaricides against mange in dog. *Indian Vet. J.* 2002; 79:828-830.
6. Campbell WC. Ivermectin, an update. *Parasitology Today*. 1985; 1:10-16.
7. Thakre BJ, Parmar Vijay L, Kumar Binod, Joseph JP, Patel JS. Therapeutic management of Dermatitis in Rabbits. *The Indian Journal of Veterinary Sciences & Biotechnology*. 2017; 13(1):88-90.
8. Soulsby E.J.L. *Helminths, arthropods and protozoa of domesticated animals*, 7th Ed. Bailliere Tindall, London, 2001.
9. Oraon B, Thakur DK, Singh SK, Gupta MK. Clinicopathological changes in pigs experimentally infected with *Sarcoptes scabiei*. *Indian J. Anim. Sci.* 2000; 70:405-406.
10. Richardson VCG. *Rabbits: Health, husbandry and diseases*. Blackwell publication, U.S.A., 2000, 34.
11. Mitra J, Shikari RN, Das AK, Roy BB, Mitra M. Therapeutic management of sarcoptic mange in rabbit with ivermectin. *Exploratory Animal and Medical Research*. 2014; 4(1):119-122.
12. White SD, Bourdeau PJ, Meredith A. Dermatologic problems of rabbits. *Compend. Contin. Educ. Pract. Vet.* 2003; 25:90-101.
13. Kachhawa JP, Kachhawa S, Srivastava M, Chahar A, Singh NK. Therapeutic management in rabbits. *Intas Polivet*. 2013; 14(11):306-308.
14. Aulakh GS, Singh JLD, Singla LD, Singla N. Pathology and therapy of natural notodricacariosis in rabbits. *Journal of Vet Parasitology*. 2003; 17:127-129