



E-ISSN: 2320-7078

P-ISSN: 2349-6800

www.entomoljournal.com

JEZS 2020; 8(2): 1424-1429

© 2020 JEZS

Received: 13-01-2020

Accepted: 15-02-2020

Jayashree PattarAnimal Science, KVK, Dharwad,
Karnataka, India**Shridhar NB**Department of Veterinary
Pharmacology and Toxicology,
Veterinary College, Bengaluru,
KVAFSU, Bidar, Karnataka,
India**Suhasini K**Department of Veterinary
Pharmacology and Toxicology,
Veterinary College, Bengaluru,
KVAFSU, Bidar, Karnataka,
India**Satyanarayana ML**Department of Veterinary
Pathology, Veterinary College,
Bengaluru, KVAFSU, Bidar,
Karnataka, India**Corresponding Author:****Jayashree Pattar**Animal Science, KVK, Dharwad,
Karnataka, India

Protective role of diatomaceous earth (DAE) on combined mycotoxicosis of aflatoxin B1 and ochratoxin a in coloured broiler (RAJA II) chickens

Jayashree Pattar, Shridhar NB, Suhasini K and Satyanarayana ML

Abstract

The study was conducted to evaluate the effect of diatomaceous earth (DAE @ 0.5 g, 1 g) on combined aflatoxin B1 (AFB1) and ochratoxin A (OTA) @ 0.5, 1 ppm in coloured broiler chickens for a period of 42 days. The combined AFB1 and OTA (1 ppm) resulted in severe reduction of BW gain (0.37 kg), poor FCR (3.15%), reduced feed intake and increased mortality (21.21%). A significant increase in the relative weight of liver and kidney, marked changes in gross, histopathology and biomarker enzymes of liver and kidney were also noticed, which were indicating AFB1 and OTA have a synergistic toxic effect on growth performance. Supplementation of DAE to combined AFB1 and OTA contaminated feed ameliorated the deleterious effects of these mycotoxins, resulted in improvement of BW gain (1.26 kg), FCR (2.18%), feed intake and reduced mortality (1.51%) thereby showing a protective role of DAE against combined mycotoxicosis.

Keywords: Synergistic, combined mycotoxins, diatomaceous earth, aflatoxin, ochratoxin

1. Introduction

Mycotoxins are heat stable lipophilic compounds, co-occurrence of different mycotoxins on agriculture commodities are common thereby adding more potential risk of additive or synergistic toxic effects in human, animals and poultry. In spite of using good manufacturing and good agriculture practice their occurrence is usually not completely preventable. Today, mycotoxins are believed to play an important role in food safety and hygiene next to bacterial and viral agents^[12]. Hence, monitoring of mycotoxins in food and in feeds are very important issues with respect to animal and human health, agriculture production and economical concern. Among mycotoxins, aflatoxin B1 and Ochratoxin A are the major mycotoxins of public health importance, have detrimental effects on both animal and human health. AFB1 produced mainly by *Aspergillus* species such as *flavus*, *parasiticus* etc. Aflatoxins are potent liver carcinogenic, mutagenic and immunosuppressive compounds. Ochratoxin A is produced mainly by *Aspergillus ochraceus* (*Aspergillus allutaceus* var. *allutaceus*) and is a potent nephrotoxic mycotoxins, which also has hepatotoxic, teratogenic, embryotoxic, genotoxic, neurotoxic, immunosuppressive and carcinogenic effects^[13, 27]. AFB1 and OTA were classified as potent human carcinogen Group 1B and possible human carcinogen Group 2B respectively^[11].

Diatomaceous earth (DAE, diatomite, or kieselgur/kieselguhr) is a naturally occurring, soft, siliceous sedimentary rock with high adsorption capacity. As it is small mass (0.5-0.8 g/cm³), with high porosity and high content of silicon (86%), sodium (5%), magnesium (3%) and iron oxide (2%)^[33, 19]. It is used as anti-caking agent, as well as an insecticide in agriculture for grain storage^[18]. The binding capacity of mycotoxin binder was affected by various factors like pH, molecular arrangement and its geographic region of origin^[32]. In the present study, DAE is used as adsorbent, mycotoxin binder for combined mycotoxins, as diatomaceous earth has shown the potential *in vitro* to bind aflatoxin, sterigmatocystin, T-2 toxin, zearalenone and ochratoxin^[20], also prevalence of co-occurrence of different mycotoxin is increasing and has severe detrimental synergistic effect on both animal and human population. Hence, the study was conducted to protect the combined mycotoxicosis in poultry by using DAE as toxin binder.

2. Materials and Methods

2.1 Mycotoxin production

Culture of *Aspergillus flavus* (MTCC 2798) and *Aspergillus ochraceus* (MTCC 10276, Institute of Microbial Technology (IMTECH), Chandigarh) were inoculated on Potato Dextrose Agar (PDA) slants and incubated at 28 °C for 7 days separately. These aflatoxin and ochratoxin cultures were inoculated on rice and wheat for the production of aflatoxin and ochratoxin respectively.

2.2 Experimental birds and diet

The study was conducted in coloured broilers (RAJA-II obtained by crossing PB1 cock with the PB2 hen) which were procured from the Department of Poultry Science, Veterinary College, Bangalore, KVAFSU, India. The approval of the Institute Animal Ethics Committee (IAEC) was obtained prior to start the experiment. The basal diet was formulated and compounded to meet the nutritional requirements of broilers based on the recommendations of Bureau of Indian Standards during the starter and finisher period was presented in Table 1. The feed sample was tested for aflatoxin and ochratoxin level before conducting the experiment, level of mycotoxins in feed was corrected and desired level of contamination of experimental feed with AFB1 and OTA was maintained. Diatomaceous earth (Sigma Aldrich, USA, purity of $\geq 95\%$) was used as mycotoxin binder for aflatoxin and ochratoxin.

Table 1: Composition and nutrient value of the experimental diets

Feed ingredients (in kg)	Starter (1-21 day)	Finisher (21-42 day)
Yellow maize	300	300
Soybean meal	185	62
Mineral mixture	15	18
DORB	-	120
Feed additives (kg/500kg)	Starter (1-21 day)	Finisher (21-42 day)
DL-methionine	0.900	0.300
Salt	2.0	2.0
Vit AB ₂ D ₃ K	0.125	0.125
Vitamin B complex	0.100	0.100
Cygro	0.250	0.375
ALBMD	0.150	0.150
Liv- 52	0.500	0.500

2.3 Experimental design

Day old chicks were individually weighed (48 ± 0.4 g), wing banded, randomly assigned as negative control group (G1) and six experimental groups (G2 to G7). Each group consist of 66 birds with four replicates of 16-17 birds each and exposed to dietary treatment for 42 days (Table No.2). All chicks were placed in battery cage and housed in an environmentally controlled house equipped with central heating and provided *ad libitum* water and feed.

Table 2: Different experimental groups and their treatment

Groups	Basal diet	Aflatoxin B1 (ppm)	Ochratoxin A (ppm)	Diatomaceous earth (g/kg)
G 1	+	-	-	-
G 2	+	-	-	0.5
G 3	+	-	-	1
G 4	+	0.5	0.5	-
G 5	+	1	1	-
G 6	+	0.5	0.5	0.5
G 7	+	1	1	1

2.4 Parameters studied

Feed intake, bodyweight, feed conversion ratio (FCR) were calculated on weekly basis. Also clinical signs, mortality and morbidity were recorded daily. Weekly six birds from each group were selected randomly and sacrificed. Blood samples were collected for serum biochemical analysis was done by using clinical chemistry analyzer - Microlab 300 (Vitalab Scientific, Netherland) following the use of commercially available diagnostic kits from ERBA Mannheim (Transasia Biomedicals Ltd, HP). The liver and kidney samples were collected for gross and histopathology study. The relative weight of internal organ was calculated by the following formula: Relative weight=organ weight (g)/Body weight (kg)

2.5 Statistical analysis

Statistical analysis was carried out using software "GraphPad Prism" and Bonferroni post-test was used for multiple comparisons ($P \leq 0.05$) when the analysis indicated significant differences among treatments. Mean values and standard deviation were calculated and all the values were expressed as Mean \pm SD.

3. Result and Discussion

3.1 Clinical signs, growth performance and mortality

Birds in G1 (negative control), G2, and G3 remained normal, active and alert throughout the period of the experiment. Marked depression, reduced feed intake, reduced feathering, reduced growth rate, leg weakness, increased water consumption and manure moisture were observed in G4 and G5 which were progressive and in a dose related manner. Highest mortality rate was noticed in combined mycotoxin groups i.e G4 and G5 (12.21 and 21.21% respectively) as compared to G6 and G7 (1.51 and 1.51% respectively) treated with DAE binder (Table No.3). During the first three weeks of experimental period, 5% mortality rate was noticed in all treated groups.

In the present study, marked reduction in bodyweight gain, feed intake and poor FCR ($P < 0.001$) in combined mycotoxin fed broilers are in agreement with the similar findings due to combined feeding of broilers with aflatoxin and ochratoxin were reported by many researcher [8, 9, 23, 24]. The decrease in growth performance upon feeding aflatoxin and ochratoxin was attributed to impaired protein metabolism and energy utilization [25, 29, 3] which impaired nutrient absorption and decreased pancreatic digestive enzyme production and consequently decrease in feed intake [21]. Further, Creepy *et al.* [6] and Huff *et al.* [10] who reported that OTA compete with phenylalanine for binding sites on the phenylalanine tRNA synthetase enzyme, thus inhibiting the protein synthesis leading to decrease in the body weight gain.

Clinical signs of mycotoxicosis and highest mortality rates were noticed in combined mycotoxin groups in the present study are due to potential toxic effect of aflatoxin and ochratoxin, also OTA being the most toxic during early life, which could be the cause of mortality in young bird and also has long lasting effects as compared to aflatoxin [22, 7, 9].

Supplementation of DAE in combined mycotoxins contaminated feed to coloured broiler significantly improved the detrimental effect of combined aflatoxin and ochratoxin on bodyweight, feed intake and FCR, thereby showing protective role of DAE on growth performance in combined mycotoxin toxicity in broilers (Table No.3). These findings are supported by similar observations made by author who found that treating AFB1 (1 mg/kg) with DAE (30 mg/kg)

from 1 day to 42 day old age broilers improved the body weight gain, feed intake and FCR [19]. Also supplementation of DAE (400 and 800 mg/kg) to ochratoxin induced toxicity (0.5 and 1 ppm) ameliorated the deleterious effect of ochratoxin A on growth performance and feed conversion in broilers [1].

3.2 Relative organ weight and pathological changes

3.2.1 Liver and Kidney:

On 42 day old birds, a significant increase ($P<0.01$) in relative weight of liver and kidney were noticed in G4 and G5 as compared to G1, G2, G3, G6 and G7 in the present study (Table No.4). Grossly, liver and kidneys showed marked paleness, swollen, friable in consistency was noticed in both G4 and G5 (Fig.A1 & A3). Microscopically in liver, revealed degenerative changes in liver parenchyma, including severe congestion, swollen hepatocytes, infiltration of lymphocyte

and heterophils and diffuse areas of necrotic changes in liver parenchyma with glandular arrangement of the hepatocytes, bile duct epithelial hyperplasia were noticed in both G4 and G5 (Fig. A2).

Whereas in kidney severe tubular distension, occlusion of lumen, inter tubular hemorrhages, swollen tubular epithelium with degenerative changes and desquamation of epithelial cells, in some of the tubules deposition of urate crystals were also noticed microscopically in both G4 and G5 (Fig. A4). All these changes were progressive in dose dependent manner. In the first three weeks, gross and histopathological examination of liver showed milder paleness and milder congestion in G6 and G7 treated with DAE toxin binder, later these changes were disappeared in subsequent week of experimental period, it shows DAE has effective toxin binding capacity (Fig. B1 & B3).

Table 3: Effect of diatomaceous earth (DAE) and combined mycotoxins on growth performance of 42 day old coloured broiler chickens

Item	Group 1	Group 2	Group 3	Group 4	Group 5	Group 6	Group 7
BW gain (g)	1401±6.5	1385±2.5	1373±3.5	472.8±1.5***	370.6±2.5***	1290±9.7***	1260±8.7***
Feed intake (g)	3014±4.2	2998±6.5	2960±8.5	1387±3.0***	1169±7.5***	2800±8.0***	2750±5.5***
FCR (%)	2.15±0.08	2.16±0.15	2.15±0.24	2.93±0.03***	3.15±0.17***	2.17±0.13***	2.18±0.05***
Mortality (%)	-	-	-	12.21***	21.21***	1.51***	1.51***

Values with different superscripts within a row indicate significant differences (* $P<0.05$, ** $P<0.01$, *** $P<0.001$)

Table 4: Effect of diatomaceous earth (DAE) and combined mycotoxins on relative organ weight (g/100 g) of 42 day old coloured broiler chickens

Item	Group 1	Group 2	Group 3	Group 4	Group 5	Group 6	Group 7
Liver	2.41±0.12	2.29±0.23	2.27±0.26	4.02±0.19***	4.17±0.39***	2.51±0.21**	2.40±0.14**
Kidney	0.90±0.06	0.91±0.08	0.90±0.06	2.84±0.16***	3.16±0.36***	1.07±0.18**	1.14±0.12**

Values with different superscripts within a row indicate significant differences (* $P<0.05$, ** $P<0.01$, *** $P<0.001$)

Table 5: Effect of diatomaceous earth (DAE) and combined mycotoxins on serum biochemistry of 42 day old coloured broiler chickens

Item	Group 1	Group 2	Group 3	Group 4	Group 5	Group 6	Group 7
SGOT (U/L)	161.33±3.9	162.38±4.1	160.46±4.6	219.08±5.3***	287.75±3.4***	167.03±2.9**	168.75±7.8**
SGPT (U/L)	16.13±0.39	16.10±0.34	16.04±0.46	19.15±0.29***	19.48±0.24***	16.82±0.93**	16.86±0.89**
GGT (U/L)	23.01±0.16	23.00±0.12	23.05±0.11	26.91±0.60***	28.25±0.55***	23.47±0.50**	23.36±0.37**
CR (mg/dL)	0.38±0.04	0.38±0.01	0.38±0.03	0.50±0.01***	0.55±0.01***	0.39±0.01**	0.39±0.03**
UA (mg/dL)	6.40±0.00	6.41±0.02	6.41±0.05	9.50±0.04***	10.54±0.01***	6.51±0.2**	6.63±0.1**

Values with different superscripts within a row indicate significant differences (* $P<0.05$, ** $P<0.01$, *** $P<0.001$)

A. Gross appearance and histopathological changes (H&E, X200). in a 42 day old chicken fed with (high dose) combined mycotoxins (AFB1 and OTA)

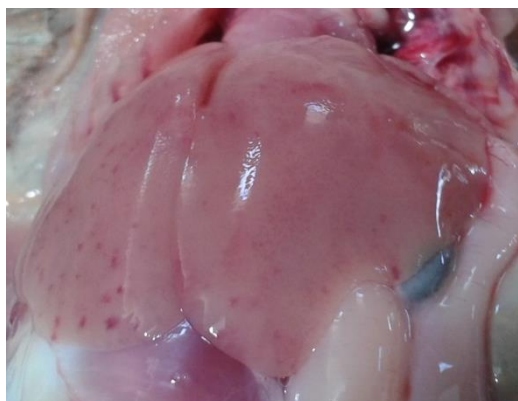

Fig A1: Liver showing marked paleness, presence of congestion and hemorrhages

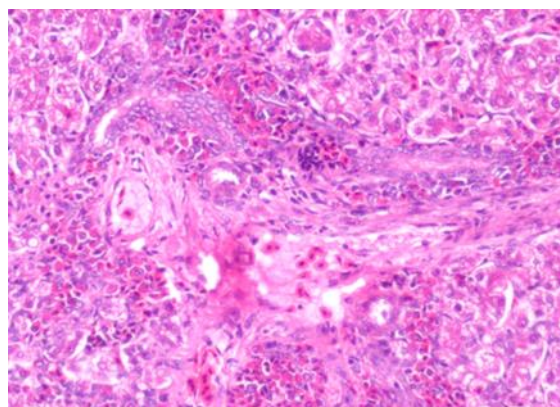


Fig A2: Degenerative and necrotic changes in parenchyma, bile duct hyperplasia and congestion and hemorrhages

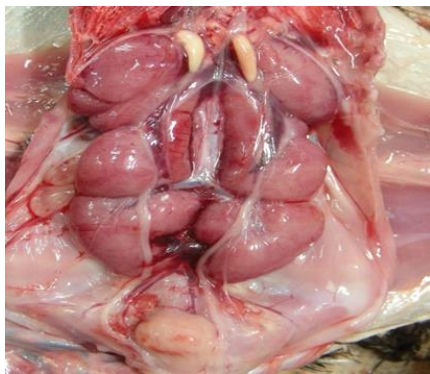

Fig A3: Kidney showing swollen and distended parenchyma, paleness and mottled appearance

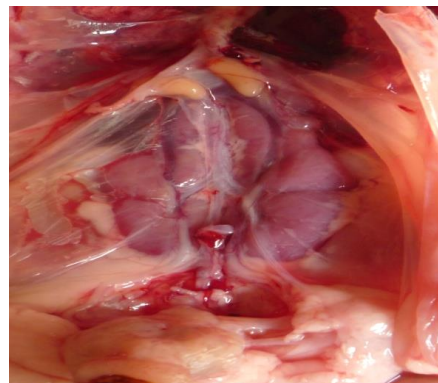


Fig B3: Normal appearance of kidney with mild congestion

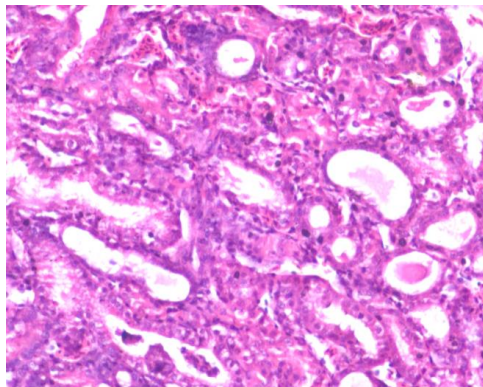


Fig A4: Kidney: Massive degenerative changes & total desquamation of tubules, inter tubular hemorrhages and appearance of hyaline casts in lumen of tubules

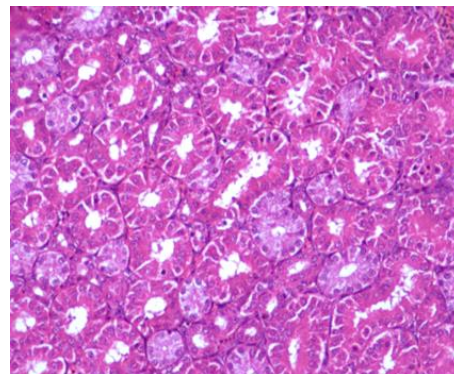


Fig B4: Kidney; Normal architecture of tubular epithelium

B. Gross appearance and histopathological changes (H&E, X200) in a 42 day old chicken fed with (high dose) combined mycotoxins (AFB1 and OTA) supplemented with DAE

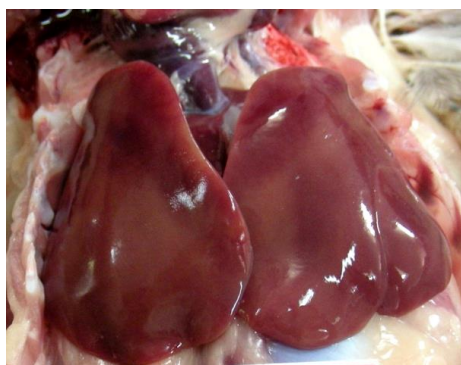

Fig B1: Liver normal appearance with mild congestion

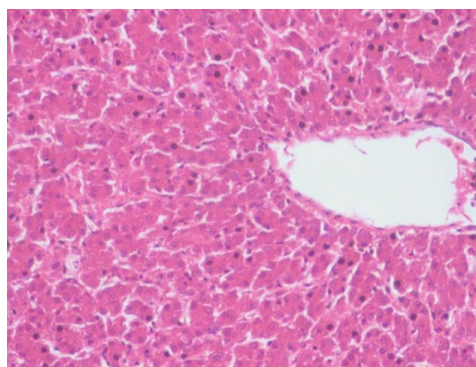


Fig B2: Liver: normal architecture of parenchyma

In the present study, a significant increase ($P < 0.001$) in relative weight of liver and kidney in G4 and G5 were supported by similar observation due to feeding of aflatoxin and ochratoxin in birds by many researchers [8, 17, 22, 23, 29, 30, 31]. Increase in the relative weight of liver and kidney may be attributed to the hepatotoxic and nephrotoxic effect of aflatoxin and ochratoxin respectively, thereby impairment in liver and kidney function, accumulation of lipids and proteins [26]. Also, in the present study marked paleness, friable, petechial hemorrhages and less fatty changes in liver and in kidney marked dilatation of ureter, severe enlargement of kidney and presence of urate crystals, severe tubular degeneration and desquamation of epithelium, intertubular hemorrhages were observed in aflatoxin and ochratoxin groups, these findings agree with data of many worker [14, 23, 24, 16, 34].

Supplementation of DAE to aflatoxin and ochratoxin contaminated diet reversed the pathological changes in liver and kidney of G6 and G7 (Fig. B2 & B4). These findings were supported by author who reported that addition of OchraTox (5 g/kg) to OTA (2 mg/kg) contaminated feed in layer hens ameliorated the pathological changes in ochratoxin [4]. Similarly, the present study agree with the findings of author who found that addition of AflaDetox (1, 2 and 5 g/kg) to AFB1 (1 mg/kg) contaminated feed in broiler protected the pathological changes in aflatoxin [5]. These findings are supported by similar observations made by researchers, where supplementation of DAE in aflatoxin (0.5 and 1 ppm) contaminated feed from 1 to 42 day old broilers significantly improved the detrimental effect of aflatoxin on pathological changes in liver and kidney thereby showing protective role of DAE in combined mycotoxin toxicity in broilers [16,17].

3.2.2 Serum parameters

A significant increase ($P < 0.001$) in the activity of liver functional biomarker enzymes aspartate aminotransferase (AST or SGOT) and alanine aminotransferase (ALT or SGPT) were noticed in G4, G5 as compared to G1, G2, G3, G6 and G7 in the present study (Table No. 5). Increase in SGPT and SGOT in G4 and G5 were in agreement with similar findings of many researcher with various dietary levels of aflatoxin and ochratoxin combination indicates severe liver damage by aflatoxin and ochratoxin [14, 23, 24, 28, 15]. Marked increase in gamma glutamyl transferase (GGT) activity was noticed in birds fed with Afla-Ochratoxin induced G4, G5 as compared to G1, G2, G3, G6 and G7 in the present study and was highly suggestive of bile duct injury, many authors reported increase in GGT activity in dietary aflatoxicosis [5, 15] and ochratoxicosis of birds [3]. Consequently, increase in the activities of SGPT, SGOT and GGT are primarily indicating hepatic damage by aflatoxin and ochratoxin.

Significant increase ($P < 0.001$) in serum creatinine and uric acid levels were observed in G4 and G5 groups. The present study on increase serum creatinine and uric acid level in combined mycotoxicosis were supported by similar findings of many authors [14, 23, 24, 28, 34] where increase in serum creatinine and uric acid may be suggestive of inflammatory or degenerative changes in the kidney.

Supplementation of DAE in combined aflatoxin and ochratoxin contaminated feed in coloured broiler significantly hampered the increase in SGPT, SGOT, GGT creatinine and uric acid (Table no.5) thereby showing protective role of DAE on serum biochemistry in combined mycotoxin toxicity in broilers. These findings are supported by similar observations made many workers who found that supplementation of DAE (400 and 800 mg/kg) to individual aflatoxin [15] and individual ochratoxin induced toxicity [2] ameliorated the deleterious effect of aflatoxin and ochratoxin A on liver and kidney biomarker enzymes in broilers.

4. Conclusion

In our present study, diatomaceous earth (DAE) showed marked protection against combined mycotoxin toxicity *in vivo*, thereby proving to be non toxic at 0.5 and 1 g/kg. DAE ameliorated the detrimental effect of combined aflatoxin and ochratoxin A (0.5 and 1 ppm each) on growth performance, relative weight of organs, serum biochemical parameters and pathological changes in coloured broilers. Hence DAE can be safely used as toxin binders and anti-caking agent in poultry feed to reduce the prevalence and incidence of mixed mycotoxins associated disorder conditions in poultry industry.

5. Acknowledgment

The authors are very much thankful to the Department of Poultry Science and Department of Pathology, Veterinary College, Bangalore for providing necessary facilities for conducting research work

6. References

- Anand VP, Lakkawar AW, Narayanaswamy HD, Sathyanarayana ML. Study on efficacy of diatomaceous earth on growth parameters in experimental ochratoxicosis in broiler chickens. *International Journal of Veterinary Sciences and Animal Husbandry*. 2018; 3(1):10-14.
- Anand VP, Lakkawar AW, Narayanaswamy HD, Sathyanarayana ML. Serum biochemical changes in ochratoxin induced toxicity and its amelioration using diatomaceous earth in broiler chicken. *International Journal of Chemical Studies*. 2018; 6(1):673-679.
- Bailey CA, Gibson RM, Kubena LF, Huff WE, Harvey RB. Ochratoxin A and dietary protein. 2: Effects on hematology and clinical chemistry measurements. *Poultry Science*. 1989; 68:1664-1671.
- Denli M, Blandon JC, Guynot ME, Salado S, Perez JF. Efficacy of a new ochratoxin binding agent (Ocratox) to counteract the deleterious effects of ochratoxin A in laying hens. *Poultry Science*. 2008; 87(11):2266-2272.
- Denli M, Blandon JC, Guynot ME, Salado S, Perez JF. Effect of dietary AflaDetox on performance, serum biochemistry, histopathological changes and aflatoxin residues in broiler exposed to aflatoxin B1. *Poultry Science*. 2009; 88(7):1444-1451.
- Creepy EE, Schlegel M, Roschenthaler R, Dirheimer G. Phenylalanine prevents acute poisoning by Ochratoxin A in mice. *Toxicology Letters*. 1980; 6(2):77-80.
- Elaroussi MA, Mohamed A, Elgendy MS, Elbarkouky EM, Abdoul AM, Hatab MH. Ochratoxicosis in broiler chickens: Functional and histological changes in target organs. *International Journal of Poultry Science*. 2008; 7(5):414-422.
- Huff WE, Doerr JA. Synergism between aflatoxin and ochratoxin in broiler chickens. *Poultry Science*. 1981; 60(3):550-555.
- Huff WE, Doerr JA, Wabeck CJ, Chaloupka GW, May JD, Merkley JW. The individual and combined effects of aflatoxin and ochratoxin A on various processing parameters of broiler chickens. *Poultry Science*. 1984; 63(11):2153-2161.
- Huff WE, Kubena LF, Harvey RB, Doerr JA. Mycotoxin interactions in poultry and swine. *Journal of Animal Science*. 1988; 66(9):2351-2355.
- IARC. Monographs on the evaluation of carcinogenic risks to humans: Some naturally occurring substances, food items and constituents, heterocyclic aromatic amines and mycotoxins. *International Agency for Research on Cancer*. 1993; 56:489-521.
- Inger V, Schroer EM, Claus PC. The carry-over of mycotoxins in products of animal origin with special regard to its implications for the European food safety legislation. *Food and Nutrition Sciences*. 2011; 2:852-867.
- JECFA (Joint FAO/WHO Expert Committee on Food Additives). Safety Evaluation of Certain Mycotoxins in Food. *WHO Food Additives Series 47, FAO Food and Nutrition Paper*. 2001, 74
- Kalorey DR, Kurkure NV, Ramgaonkar JS, Sakhare PS, Shubhangi W, Nigot K. Effects of polyherbal feed supplement "Growell" during induced aflatoxicosis, ochratoxicosis and combined mycotoxicoses in broilers. *Asian-Australasian Journal of Animal Science*. 2005; 18(3):375-383.
- Lakkawar AW, Narayanaswamy HD, Sathyanarayana ML, Sugunaroo S, Yathiraj, Isloor SK *et al*. Efficacy of diatomaceous earth in amelioration of aflatoxin induced toxicity in broiler chicken. *Indian Journal of Animal Research*. 2016; 50:529-536.
- Lakkawar AW, Narayanaswamy HD, Sathyanarayana ML. Study on efficacy of diatomaceous earth to ameliorate aflatoxin induced patho-morphological changes in

- kidneys of broiler chicken. *Journal of Entomology and Zoology Studies*. 2017; 5(6):2122-2127.
17. Lakkawar AW, Narayanaswamy HD, Satyanarayana ML. Study on Efficacy of Diatomaceous Earth to Ameliorate Aflatoxin Induced Patho-Morphological Changes in Liver and Intestines of Broiler Chicken. *International Journal of Livestock Research*. 2017; 7(8):71-84.
 18. Lartigue EC, Rossanigo CE. Insecticide and anthelmintic assessment of diatomaceous earth in cattle. *Veterinaria Argentina*. 2004; 21(209):660-674.
 19. Mehrdad M, Behzad M, Ali RK, Mohammad MK, Parvaneh K, Mohsen F *et al*. Effect of diatomaceous earth on the performance and blood variables of broiler chicks during experimental aflatoxicosis. *Journal of the Science of Food and Agriculture*. 2008; 88(4):626-632.
 20. Natour RM, Yousef SM. Adsorption efficiency of diatomaceous earth for mycotoxin. *Arab Gulf Journal for Scientific Research*. 1998; 16(1):113-127.
 21. Osborne DJ, Hamilton PB. Decreased pancreatic digestive enzymes during aflatoxicosis. *Poultry Science*. 1981; 60:1818-1821
 22. Raju MV, Devegoda G. Influence of esterified glucomannan on performance and organic morphology, serum biochemistry and haematology in broilers exposed to individual and combined mycotoxicosis (aflatoxin, ochratoxin and T-2 toxin). *British Poultry Science*. 2000; 41(5):640-650.
 23. Sakhare PS, Harne SD, Kalorey DR, Warke SR, Bhandarkar AG, Kurkure NV. Effect of Toxiroak® polyherbal feed supplement during induced aflatoxicosis, ochratoxicosis and combined mycotoxicoses in broilers. *Veterinarski arhiv*. 2007; 77(2):129-146.
 24. Sawarkar AR, Sonkusale PM, Kurkure NV, Jangade CR, Maini S, Ravikanth K. Experimental afla and ochratoxin induced mixed mycotoxicosis in broilers and its amelioration with herbomineral toxin binder 'Toxiroak Gold'. *International Journal of Poultry Science*. 2011; 10(7):560-566.
 25. Smith JW, Hamilton PB. Aflatoxicosis in broiler chickens. *Poultry Science*. 1970; 49:207-215.
 26. Sumit R, Kim J, Coulombe R. Aflatoxin B₁ in poultry: Toxicology, metabolism and prevention. *Research in Veterinary Science*. 2010; 89(3):325-331.
 27. Turner NW, Bramhmbhatt H, Szabo VM, Poma A, Coker R, Piletsky SA. Analytical methods for determination of mycotoxins: An update (2009-2014). *Analytica Chimica Acta*. 2015; 901:12-33.
 28. Umar S, Arshad A, Ahmad B, Arshad M. Clinico-biochemical and haematological changes in broilers induced by concurrent exposure to aflatoxin B₁ and ochratoxin A. *Journal of Public Health and Biological Sciences*. 2012; 1(3):79-85.
 29. Valchev I, Grozeva N, Lazarov L, Kanakov D, Hristov TS, Binev R *et al*. Investigations on kidney function in mulard ducklings with experimental aflatoxicosis. *Journal of Agricultural Science and Technology*. 2013; 5(3):282-289.
 30. Valchev D, Kanakov TS, Hristov L, Lazarov R, Binev N, Grozeva Y *et al*. Effects of experimental aflatoxicosis on renal function in broiler chicken. *Bulgarian Journal of Veterinary Medicine*. 2014; 17(4):314-324.
 31. Verma J, Swain BK, Johri TS. Effect of various levels of aflatoxin and ochratoxin A and combinations thereof on protein and energy utilisation in broilers. *Journal of the Science of Food and Agriculture*. 2002; 82:1412-1417.
 32. Vieira SL. Nutritional implication of mould development in feed stuff and alternatives to reduce the mycotoxins problem in poultry feed. *World Poultry Science Journal*. 2003; 59:111.
 33. Whitlow LW. Evaluation of mycotoxin binders. 4th Mid-Atlantic Nutrition Conference (Zimmerman, N.G. ed.), Proceedings. 2006, 132-143.
 34. Yildirim E, Yalchinkaya I, Kanbur M, Çnar M, Oruc E. Effects of yeast glucomannan on performance, some biochemical parameters and pathological changes in experimental aflatoxicosis in broiler chickens. *Revue de Médecine Vétérinaire*. 2011; 162:413-420.