



E-ISSN: 2320-7078

P-ISSN: 2349-6800

www.entomoljournal.com

JEZS 2020; 8(5): 929-933

© 2020 JEZS

Received: 15-06-2020

Accepted: 18-08-2020

Shashi Kumar

Department of Veterinary
Anatomy and Histology, College
of Veterinary and Animal
Science, Navania, Vallabh Nagar,
Udaipur, Rajasthan, India

Balwant Meshram

Department of Veterinary
Anatomy and Histology, College
of Veterinary and Animal
Science, Navania, Vallabh Nagar,
Udaipur, Rajasthan, India

Corresponding Author:**Shashi Kumar**

Department of Veterinary
Anatomy and Histology, College
of Veterinary and Animal
Science, Navania, Vallabh Nagar,
Udaipur, Rajasthan, India

Gross anatomical and histomorphological studies of pineal gland (*Epiphysis cerebri*) in guinea fowl (*Numida meleagris*)

Shashi Kumar and Balwant Meshram

Abstract

The gross anatomy and histomorphology of pineal gland (*Epiphysis cerebri*) in Guinea fowl (*Numida meleagris*) was studied in 12 samples of pineal gland. The pineal gland was located within the triangular space formed between both the cerebral hemispheres and the cerebellum. The average length and thickness of pineal gland were observed as 6.549 mm and 0.949 mm, respectively. Microscopically, the pineal gland was surrounded by a thin tunic of connective tissue. Lacunae facilitated the formation of different lobes. Blood vessel was visualized in the trabecular region. Two types of cells were differentiated depending upon their shape and the containment of chromatin material. Rounded pinealocytes and irregularly cylindrical shaped glial cells, the astrocytes were observed. Bulk of the pinealocytes was detected with four different type's viz. P1, P2, P3 and P4. In respect of the astrocytes, depending upon the variability in size, two types of cells was observed as A1 and A2.

Keywords: Pineal gland, guinea fowl, lacunae, pinealocytes, astrocytes

Introduction

The pineal gland (*Epiphysis cerebri*), also known as the "third eye" of the body that is located deep in the center of the brain. This gland is structurally very diverse among the avian species that have been examined by researchers. In some birds, especially Owls, the pineal is virtually absent. The pineal gland performs some basic function including secretion of the melatonin hormone and maintenance of circadian rhythm along with reproductive cycle [1].

Sympathetic innervation is provided by projections from the superior cervical ganglia. Several cell types are present in the pineal body, among which large cells are associated with lamellar bodies that are commonly considered to be the abortive or vestigial photoreceptors. Diurnal cycles of serotonin and melatonin content of the pineal are responsive to photoperiod and there is a tiny evidence that the avian pineal may serve as a pacemaker for diurnal rhythms of activity. Pinelectomy indicated a role for body in controlling gonadal function, but their confirmation is not consistently observed as documentation. However, the physiological significance of the gland is far from fully understood and in many other aspects the publicly placed data of information on the same is scarce and till now it can be the axial point of thrust of researchers. It will be the attempt to explore important structural dependent linkage between functional aspects of the study model. This will be a small stepping stone towards increasing its acquaintance and to provide some useful literature about its microarchitectural features.

Materials and Methods

Twelve Guinea fowl (*Numida meleagris*) birds without discriminating on the basis of their sex were identified at the meat shops. The heads of these predetermined birds were procured from those who have procured and slaughtered the birds at meat shops for meat purpose. The procured heads of birds were carried on ice at laboratory for further routine desired process of investigation.

The craniums of heads were broken down carefully while exposing the brain. After its removal the morphometric measurements of brain were recorded. The pineal glands were separated carefully from the brain and preferred to be fixed in different fixatives as per the requirement of histological studies [2-5].

During the routine histological procedure the pineal glands were fixed in 10% neutral buffered formalin for 24 hours. The pineal gland were washed in running tap water for overnight,

dehydrated through a series of ascending grades of alcohol and was cleared in xylene, infiltrated in melted paraffin at 60 °C by giving four changes each of one hour duration and embedded in paraffin as per Singh and Sulochana (1996) [2].

The prepared paraffin blocks were stored in refrigerator and were cut into 5-8 µm thickness on automatic rotary microtome and then it were taken on water floating bath at 45 °C. The sections were collected on albumin coated slides, dried at 37 °C on hot plate and were preserved for staining procedure. Paraffin sections were stained by Haematoxylin and Eosin method.

Results

GROSS: The pineal gland was observed lying in a triangular space formed between both the cerebral hemispheres and the cerebellum and was found attached with its covering meningeal components (Fig. 1, 2 & 3).

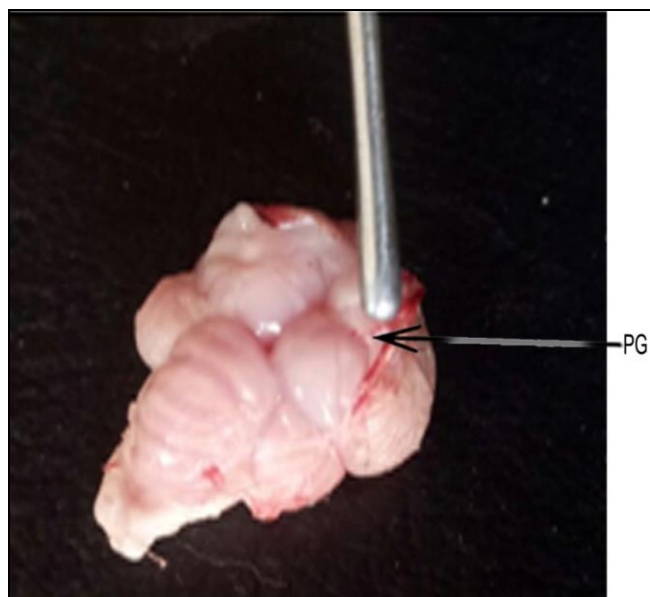


Fig 1: The minute Pineal Gland (PG) after piercing the duramater from transverse fissure.

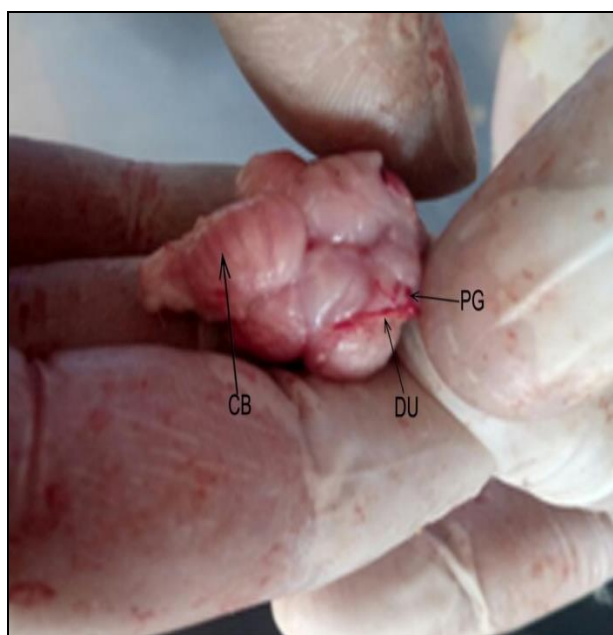


Fig 2: The Pineal Gland (PG) attachment in brain connected to the Duramater (DU). Convolutions on the Cerebellum (CB) are also seen.




Fig 3: The individual Pineal Gland. It is showing Total Length (L), Thickness (T), and its parts, Body (B), Shaft (S), Apex (A) and Root (R).

Table 1: Different micrometrical observations pertaining to Pineal gland (*Epiphysis cerebri*)

Sample	Length/mm	Width/ mm
1	5.16	1.15
2	5.31	0.64
3	8.64	1.13
4	5.39	1.14
5	5.6	0.55
6	6.74	0.94
7	7.91	1.06
8	6.42	0.82
9	5.71	1.1
10	6.19	0.73
11	7.29	1.02
12	8.23	1.11
Mean	6.549167	0.949167
SD	1.213323	0.212152
SE	0.350256	0.061243

SD: Standard Deviation, SE: Standard Error

The average length and thickness of pineal gland were observed as 6.549 mm and 0.949 mm, respectively.

Histology

Microscopically the pineal gland was observed. The pineal body was observed surrounded by a thin tunic of connective tissue. The surrounding thin connective tissue septum was observed entering into the parenchyma of gland. But, the thin structured tunics which enter into the parenchyma does not allow the formation of complete parenchymal lobulation. Instead, the lacunae were observed facilitating the formation of different lobes. Lacunae became the reason by which the pineal body doesn't remain as the compact gland (Fig. 4, 5 and 6). In majority of cases the horizontal lobes were occurred in pineal bodies with parallel orientation of lamellae of different cells. Lacunae may be the comparable structure with vesicles which were encountered into the pineal body and functions for the provision of brain sand. It might be the similar packaging structure helps to maintain the horizontal lobes to have the pineal body in shape. The trabeculae were also shown the presence of blood vessels (Fig. 7).

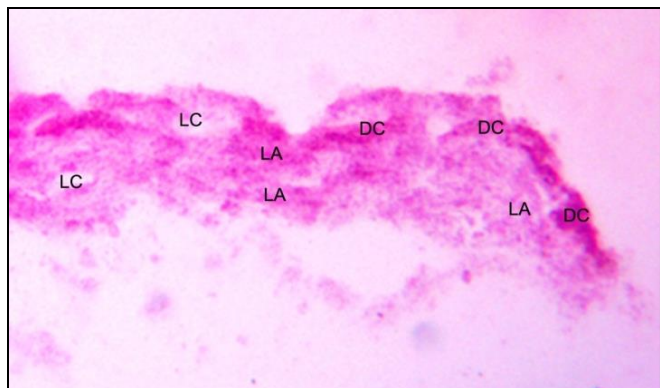


Fig 4: Photomicrograph showing the histological structure of pineal gland. Different cells (DC), Lamellae (LA) and Lacunae (LC). Haematoxylin and Eosin 40X.

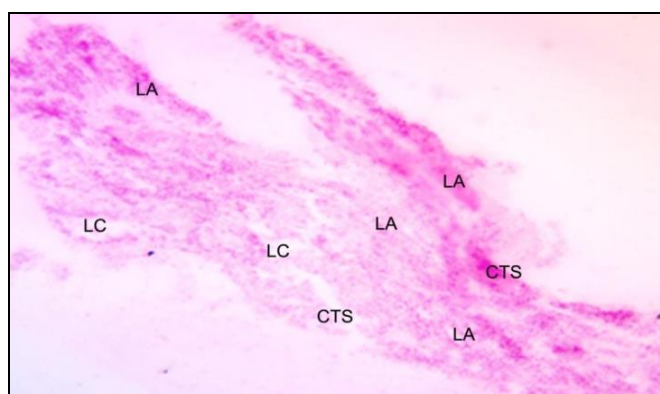


Fig 5: Photomicrograph showing the histological structure of pineal gland. Lamellae (LA), Lacunae (LC) and Connective tissue septa (CTS). Haematoxylin and Eosin 100X.

Histomorphologically the different cells were observed with vigorous occurrence at periphery of the pineal bodies. The cells were differentiated depending upon their shape and the containment of chromatin material. Randomly distributed rounded pinealocytes and cylindrical but irregular shaped glial cells, the astrocytes were observed.

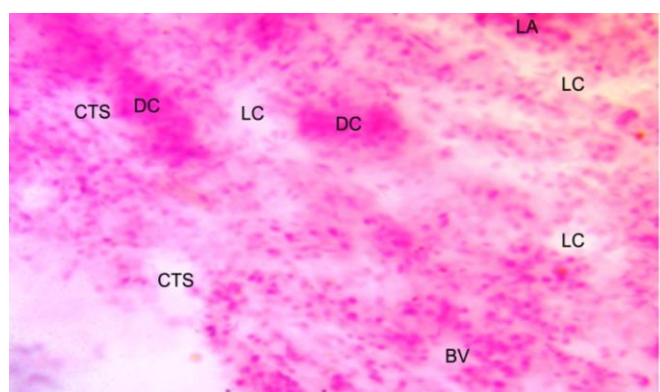


Fig 6: Photomicrograph showing the histological structure of pineal gland. Lamellae (LA), Lacunae (LC), Different cells (DC), Blood Vessels (BV) and Connective tissue septa (CTS). Haematoxylin and Eosin 400X.

These different types of pinealocytes were the rounded shaped but different sized cells. It had variable amount of the chromatin material. Bulk of the pinealocytes was detected with four different types. The first type of pinealocytes (P1) was shown the small sized cells with euchromatic cytoplasm. The second (P2) types of cells were large sized and with the

euchromatic cytoplasm. The third types of pinealocytes (P3) were shown heterochromatic cytoplasm while the fourth types of cells (P4) were in extreme faint presentation in respect of the chromatin material content of cells. In respect of the astrocytes, depending upon the variability in size two types of cells were observed viz. discovered as A1 and A2. The first astrocytes (A1) were observed in elliptical shape but with pointed end while another (A2) cells were observed as completely elliptically cylindrical (Fig. 7).

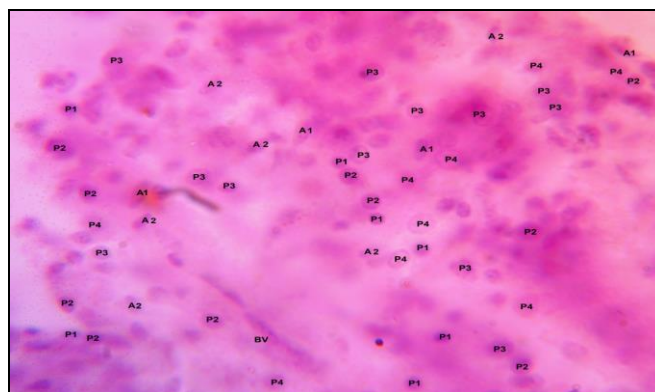


Fig 7: Photomicrograph showing the histological structure of pineal gland. Different types of Pinealocytes (P1), (P2), (P3), (P4) and Astrocytes, (A1), (A2) and Blood Vessels (BV). Haematoxylin and Eosin 1000X.

Discussion

Grossly, the pineal gland was observed lying in a triangular space formed between both the cerebral hemispheres and the cerebellum and was found attached with its covering or the meningeal components. The pineal gland was found to attach with the meningeal components. Barcelos *et al.* (2015) [6] identified the outermost component as duramater in the pineal gland of penguin. The length and thickness of pineal gland were calculated as 6.549 ± 0.350 mm and 0.949 ± 0.061 mm, respectively. Matsunaga *et al.* (2011) [7] revealed the morphologic analysis of Swiss mice's pineal gland. The outline of pineal gland was found to resemble characteristic tonsillar shape with a stalk. The location of pineal gland was visualized on the basis of internal sagittal structure of the midbrain. The pineal gland was located below the splenium of the corpus callosum, inferior to the third ventricle and superior and dorsal to the habenular commissure, to which it was intimately related. The gland was visualized coated by a ciliated cylindrical epithelium arising from the pia-mater. However Barcelos *et al.* (2015) [6] in pineal gland of the penguins was more near to the present finding which was similarly observed in location and close to the cavernous sinus. They reported the geometry of the pineal gland similar to the bludgeon-shaped structure. The average length and thickness of the pineal gland of the penguins were calculated as 11.16 mm and 1.69 mm, respectively. These variations were due to the large size of brain and body weight in comparison to guinea fowl. The distal section included within the duramater and the proximal section extending of the choroid plexus. Peng *et al.* (2008) [8] reported a small rod-shaped, bottom up tuber, nomeclatured as the conarium or in common terminology the pineal body, at the juncture of the transverse sulcus and the 2 cerebral hemispheres in the brain of African ostrich.

Microscopically the pineal gland was observed surrounded by a thin tunic of connective tissue. The surrounding thin connective tissue septum was observed entering into the

parenchyma of gland. Similar observations were found in the pineal gland of pig as observed by Kumar and Kumar (2011)^[9] as the pineal gland was surrounded by a layer of capsule having loose irregular connective tissue consisting of collagen and reticular fibres. The pig and present bio-model are different as the species, but pineal gland as the organ component is a common factor among them. Hence, in the present histological studies on pineal gland, the comparison was made despite of difference of species. The findings were analogous to the observations by Gornowicz *et al.* (2004)^[10] in the turkey pineal organ in which the pineal body was covered by a connective tissue capsule with numerous blood vessels. The thickness of the capsule differed depending on the region of the organ and it was particularly prominent on the apical surface of the pineal. The thin structured tunics which enter into the parenchyma doesn't allow the formation of complete parenchymal lobulation. Instead, the lacunae were observed facilitating the formation of different lobes. Due to formation of lacunae the pineal gland doesn't remain as the compact gland. In majority of cases the horizontal lobes were occurred in pineal bodies with parallel orientation of lamellae of different cells. Similar observations were made by Kumar and Kumar (2011)^[9] in the pineal gland of pig, as they reported the connective tissue trabeculae from the capsule penetrating the parenchyma and dividing the gland into lobes and lobules. This was also comparable to the observations of Gornowicz *et al.* (2004)^[10] in the turkey pineal organ as the pineal parenchyma was formed by oval or round follicles which number ranged from 60 to 80 on the middle-sagittal section. Oval, usually larger, follicles were situated mostly in the rostral and distal areas of the club-shaped apical part of the organ and round, usually smaller, vesicles in the remaining areas of the gland. The follicles contained a lumen, which was variable in size and empty. Lacunae may be the comparable structure with vesicles which were encountered into the pineal body and functions for the provision of brain sand. It might be the similar packaging structure helps to maintain the horizontal lobes to have the pineal body in shape. The trabeculae were also shown the presence of blood vessels.

Histologically, the tissues of pineal gland showed the parenchyma differentiated into two types of cells viz. the pinealocytes and the astrocytes. Pinealocytes were the major and chief cells which were characterized by centrally placed nuclei and random distribution. The astrocytes were identified with cylindrical shape and were lesser in number compared to pinealocytes. They were observed both individually as well as in clusters. Similar observations on pineal gland of pigs by Babu and Ramayya (2014)^[11] were reported. The parenchyma of the pineal gland consisted of pinealocytes, glial cells and blood capillaries. The pinealocytes were the chief cells and distributed throughout the gland and arranged as clusters. Microscopically, the pinealocytes and some glia cells were predominant cells in the pineal gland of the yellow-toothed cavy (*Galea spixii wagler*) and red-rumped agouti (*Dasyprocta leporina linnaeus*) as reported by Camara *et al.* (2015)^[12]. Similar outcome were revealed by Beheiry and Moselhy (2016)^[13] in the pineal gland of adult camel as they too observe the pinealocytes and glia cells as the two types of parenchymal cells. The present observations were not different with morphometric finding of Bhatnagar and Lall (2005)^[14] in the pineal gland of insectivorous bat (*Rhinopoma kinneari*) during various developmental and reproductive states. The pinealocytes were observed round to oval in shape

and characterized by the presence of a large and oval nucleus. The nucleus was attributed by large quantity of stainable euchromatic and prominent basophilic nucleolus. The conlusional studies were favored by the report by Matsunaga *et al.* (2011)^[7] in Swiss mice's pineal gland, pinealocyte like cells spreading all over the gland and piercing adjacent structures. These cells had large round nuclei with remarkable loose chromatin and acidophilic cytoplasm with few granules. Astrocytes were visualized as cells with elongated strong basophilic nuclei. These cells had extensions which stretched out between the pinealocytes. No calcifications were found in the pineal glands. A single high-diameter artery entering the gland stalk, showing a remarkable quantity of erythrocytes within was observed which indicated high vascularity. Similar observations were made in the pineal gland of pig by Kumar and Kumar (2011)^[9], as they observed the parenchyma of the gland constituted by pinealocytes, glial cells, fine blood capillaries and the nerve bundles. The pinealocytes constituting the majority of cell population were distributed throughout the gland having an arrangement in the form of irregular groups, small clusters, rosettes or follicles. The chief cells representing the pinealocytes were distributed diffusely in a narrow zone at the periphery whereas; these cells were closely packed to form a syncytium like arrangement towards the centre. This was in contrary with the finding by Bhatnagar and Lall (2005)^[14] in the observations made in the pineal gland of insectivorous bat (*Rhinopoma kinneari*) as their study does not mention any literature regarding glial cells or astrocytes. But, Kumar and Kumar (2011)^[9] reported in pineal gland of pig, the glial cells interspersed in between groups of pinealocytes, yet could not be distinguished in the form of astrocytes, oligodendroglia and microglial cells even with the special stains.

The pinealocytes were detected with four different types on the basis of amount and distribution of the chromatin material. The first type of pinealocytes (P1) appeared small sized cells with euchromatic cytoplasm. The second (P2) types of cells were large sized and with the euchromatic cytoplasm. The third types of pinealocytes (P3) were observed with heterochromatic cytoplasm while the fourth types of cells (P4) were showed extremely faint chromatin material. The findings in present studies are very much encouraging towards the understandings of ancient times, wherein, the circadian clock which maintains day and night for complete 24 hours works via eight units of 3 hours each. In the present study's findings of four different pinealocytes symbolizes the expression that each of the pinealocyte has worked for 2 units. However Babu and Ramayya (2014)^[11] in their studies on the pineal gland of pigs reported the pinealocytes as round to oval shaped with dark cytoplasm and euchromatic nuclei. The pinealocytes were differentiated into two types viz. light and dark by Bhatnagar and Lall (2005)^[14] in the observations made in the pineal gland of insectivorous bat (*Rhinopoma kinneari*) during various developmental and reproductive states. In the light pinealocytes cytoplasm was agranular and stained weakly. However, in dark pinealocytes, the cytoplasm was strongly eosinophilic. These pinealocytes were randomly arranged and did not manifest any specific pattern. The mean diameter of nucleus was 30 μm . The nuclei of pinealocytes also exhibited differential basophilia. Intrapineal neurons; intra pineal cavities and blood vessels were also observed. However, slight differences were noticed within gender of the same species, which were negligible, but the basic components were the same. The pinealocytes of pineal gland

of pig as observed by Kumar and Kumar (2011) ^[9] in their investigation were categorized into two types on the basis of distribution of chromatin material and staining affinity of cytoplasm. The round to oval shaped lighter pinealocytes had fine dusting of euchromatin material irregularly throughout the nucleus whereas, small sized dark pinealocytes possessed fine aggregation of deeply basophilic heterochromatin material masking the details of nucleoli. The astrocytes were classified into two types on the basis of shape and size. The first astrocytes (A1) were observed in elliptical shape but with pointed end while another (A2) cells were observed as completely elliptically cylindrical with no pointed ends. But Babu and Ramayya (2014) ^[11] reported the glial cells larger than the pinealocytes in their histomorphological observations on the pineal gland of pigs. They categorized the glial cells into three types based on their nuclear morphology, viz., the type-I cells were large round type with and basophilic nucleus, the type-II cells were smaller and without process, the type-III cells were elongated and appeared like smooth muscle cells and showed two distinct cytoplasmic processes. Kumar and Kumar (2011) ^[9] in their histomorphological studies of pineal gland of pig categorized the glial cells into 4 types based on nuclear morphology. Type-I glial cells had large round to oval, less basophilic nuclei with fine chromatin material condensed in smaller clumps irregularly throughout the nucleus. The glial processes presented more eosinophilic and granular feature as compared to the cytoplasm of the cell. Type-II glial cells were significantly smaller in size with round to oval nuclei having strongly basophilic chromatin material which tended to accumulate in larger clumps particularly towards the outer nuclear membrane. These cells were having a sparse distribution along with type-I glial cells. Type-III glial cells were elongated, ovoid in shape mainly associated with fine blood capillaries. The number of these cells showed a positive correlation with the vascularity of the gland parenchyma. The type-IV cells possessed nuclei which were largest amongst all the cell types in the pineal gland of pig.

Conclusion

The pineal gland was observed located in the triangular space formed between both the cerebral hemispheres and the cerebellum and was found attached with its covering meningeal components. The length and thickness of pineal gland were examined which were observed as was 6.549 ± 0.350 mm and 0.949 ± 0.061 mm, respectively. Microscopically the pineal gland was observed which was surrounded by a thin tunic of connective tissue. The surrounding thin connective tissue septa were observed entering into the parenchyma of gland. But, the thin structured tunics which enter into the parenchyma doesn't allow the formation of complete parenchymal lobulation. The lacunae were observed facilitating the formation of different lobes and it remained as the component which doesn't allow pineal body to be the compact gland. The trabeculae showed the presence of blood vessels. Histomorphologically the different cells were observed with vigorous occurrence at periphery of the pineal bodies. Various sized rounded pinealocytes were randomly distributed with cylindrical and somewhat disorderly shaped astrocytes, the glial cells in the parenchyma of pineal gland.

References

1. Ralph CL. Structure and Alleged Functions of Avian

Pineals. Department of Biology, University of Pittsburgh, Pittsburgh, Pennsylvania 15213. Am. Zoo. 1970; 10:217-235.

2. Singh UB, Sulochana. Handbook of Histological & Histochemical Techniques, Premier Publishing House, Hyderabad, 1996.
3. Bancroft JD, Stevens A, Turner DR. Theory and Practice of Histological Techniques. 4th ed. Churchill Livingstone, New York, 1994, 99-112.
4. Luna LG. Manual of histological staining methods of the Armed forces in institute of pathology, the blackiston division, McGraw -HILL Book Company, New York. Co. N.Y, 1960, 162-164.
5. Fejer Z, Rohlich P, Szel A, David C, Zadori A, Manzano MJ *et al.* Comparative ultrastructure and Histochemistry of the avian pineal organ. Micros. Res. and tech, 2001.
6. Barcelos RP, Filadelpho AL, Suzymeire B, Weferson JG. The morphology of the pineal gland of the Magellanic penguin (*Spheniscus magellanicus* Forster). J Morphol. Sci. 2015; 32(3):149-156.
7. Matsunaga MM, Crunfli F, Fernandes GJM, Rossi JWC, Esteves A. Morphologic analysis of mice's pineal gland. Laboratory of Anatomy, Alfenas Federal University – UNIFAL, MG, Brazil. J Morp. Sci. 2011; 28(3):157-160.
8. Peng K, Feng Y, Zhang G, Liu H, Song H. Anatomical study of the brain of the African ostrich. Turkish Journal of Veterinary and Animal Sciences. 2008; 3:235-241.
9. Kumar P, Kumar P. Histology, histochemistry and scanning electron microscopy of the pineal gland of the pig. CCS, Haryana Agricultural University, Hisar, Haryana 125 004 India Indian. Jour. of Ani. Sci. 2011; 81(10):1025-1028.
10. Gornowicz BP, Lewczuk B, Prusik M, Nowicki M. Post-hatching development of the turkey pineal organ. Histological and immunohistochemical studies. Neuro. endo. crinol. Lett. 2004; 26(4):383-392.
11. Babu AP, Ramayya PJ. Microanatomical studies on the pineal gland of pig. Indo-Am. J Agric. And Vet. Sci. 2014; 24:67-71.
12. Camara FV, Lopes IR, Deoliveira GB, Bezerra FV, Deoliveira RE, Oliveira JCM *et al.* The morphology of the pineal gland of the yellow-toothed cavy (*Galea spixii* wagler) and red-rumped agouti (*Dasyprocta leporina linnaeus*). Doi:10.1002/jemt.22519. Micros. Res. Tech. 2015; 78(8):660-666.
13. Beheiry RR, Moselhy AAA. Macro and microscopical studies on the pineal gland of camel with immunohistochemical localization of pinealocytes and glia cell markers. DOI:10.21474/IJAR01/1317 Int. J. Adv. Res. 2016; 4(8):1154-1163.
14. Bhatnagar S, Lall SB. Morphometric and histochemical alterations in the pineal gland of Insectivorous bat (*Rhinopoma kinneari*) during various developmental and reproductive states. Anna. of Neuros, 2005, 12(2).