



E-ISSN: 2320-7078

P-ISSN: 2349-6800

[www.entomoljournal.com](http://www.entomoljournal.com)

JEZS 2021; 9(1): 331-333

© 2021 JEZS

Received: 30-10-2020

Accepted: 10-12-2020

**Dipanwita Das**

Department of Veterinary  
Pathology, C.V.Sc & A.H. Orissa  
University of Agriculture and  
Technology, Bhubaneswar,  
Odisha, India

**KGV Manikanta**

Department of Veterinary  
Pathology, C.V.Sc & A.H. Orissa  
University of Agriculture and  
Technology, Bhubaneswar,  
Odisha, India

**Sachin Kumthekar**

Chief Veterinary Pathologist;  
Diagnovet, Pune, Maharashtra,  
India

**K Haripriya Achary**

Department of Veterinary  
Pathology, C.V.Sc & A.H. Orissa  
University of Agriculture and  
Technology, Bhubaneswar,  
Odisha, India

**Mohan M Deshkar**

Canine World, Veterinary  
Physician

## Hemangiosarcoma in German shepherd dog

**Dipanwita Das, KGV Manikanta, Sachin Kumthekar, K Haripriya Achary and Mohan M Deshkar**

DOI: <https://doi.org/10.22271/j.ento.2021.v9.i1e.8165>

**Abstract**

A geriatric German shepherd dog was presented for indigestion and ascites. The dog was lethargic, had tachycardia with intermittent vomiting, episodes of weakness, occasional pulse deficits, and anorexia. Radiography, ultrasonography, quick assessment tests, and a complete blood (cell) count (CBC)/biochemistry panel indicated internal hemorrhage and potential problems with hemostasis. The dog was euthanized. A necropsy, with histopathology confirmed diagnosis of splenic hemangiosarcoma.

**Keywords:** Hemangiosarcoma, dog, biochemistry, radiography, ultrasonography

**Introduction**

Hemangiosarcoma is the cancer of vascular endothelium., which is an aggressive tumor in dogs noticed in age 6-17 years with high mortality rate and median survival of 3–6 months with a with an outcome of grave prognosis <sup>[1]</sup>. Most commonly seen clinical signs are lethargy, anorexia, episodic occurrence of tumour in dogs and presence of fluid filled abdomen. The spleen is the most common site for the occurrence of visceral hemangiosarcoma with noticeable hemiabdomen and chances of organ rupture <sup>[2]</sup>. When tumour ruptures, it also leads to anaemic condition which can be revealed through pale mucous membrane. The condition is diagnosed on the basis of clinical signs and haematological changes such as anemia, thrombocytopenia, DIC, etc. radiography and ultrasonographic study reveals enlarged spleen with multiple nodules, free fluid in abdomen and masses in heart or other abdominal organs. Splenectomy is usually followed by adjuvant doxorubicin-based chemotherapy; however, adding only meagre chances of incremental survival <sup>[1]</sup>. Consequently, to avoid further pain to their pets much due to aggressive chemotherapy and toxicity issues, euthanasia is chosen. Subsequently, the owners may opt for euthanizing their pets considering their unbearable pain and trouble. In the present paper we report a case of hemangiosarcoma in German shepherd dog with major focus on its clinical features and histopathological diagnosis.

**Case Description**

This case was presented with the history of intermittent vomitions, episodes of weakness, exercise intolerance, increased respiratory rates and anorexia. The dog has been suffering since last 3 months and has been under treatment, but no improvement observed. Temperature was in normal range around 101.7F. Potbelly appearance of abdomen was noticed upon palpation. Constipation was noticed for three days with anorexia. Examination of blood and faecal samples was done. Faecal sample results revealed the presence of mucus, mild fat globules with some undigested food. Haematology parameters revealed low hemoglobin and TEC with high TLC.

The haemoglobin value was lower than normal range 9.3 g/dL indicating that the animal was anemic. Serum biochemical parameters were also tabulated below. TEC count is low and TLC values are high with increased lymphocyte count which might interpret mild regenerative anemia along with moderate reactive neutrophilia and moderate monocytosis. Serum biochemistry revealed elevated levels of BUN with 28mg/dL, mild AST value of 76 and CPK value of 1310. Radiography and ultrasound examinations were done as well. Upon abdominal radiography, it revealed opacity of the abdomen with ground glass appearance with no visualization of abdominal organs which can reveal the ascites condition. Ultrasound examination of abdomen revealed presence of fluid in abdomen which suggests the ascites condition and spleen revealed hypochoic regions which suggestive of neoplasia.

**Corresponding Author:****Dipanwita Das**

Department of Veterinary  
Pathology, C.V.Sc & A.H. Orissa  
University of Agriculture and  
Technology, Bhubaneswar,  
Odisha, India

## Material and Method

**Postmortem examination:** As the condition of animal is not improving, the owner was agreed to euthanize the dog. Upon euthanization, postmortem examination was done. After the death of the German shepherd dog of 10 years age following treatment, the carcass was presented for necropsy. Loose motion, Fever, potbelly, weightloss, vomition, intermittent straining, later constipation, anorexia, jaundice, and dyspnoea were reported as the clinical signs. The treatment carried out was as follows - I/v fluids, injection Aminoven, Ridema, antibiotics, supportive. Necropsy was conducted with standard procedure.

**Histopathological examination:** Morbid tissues from these organs were collected in 10% formal saline. These tissues were further processed to form paraffin blocks. Sections of 4 micron were taken and detail histopathological examination was carried out to study the microscopic lesions [10].

## Results and Discussions

Abdomen has noticed straw colour like fluid oozing out and no specific gross lesions have noticed upon examination of different organs. However, spleen had shown some nodular like growths on its surface which was depicted below. The nodules were thick upon palpation and were quite suggestive of neoplastic growths as per the reports of ultrasound. Tissue sample was collected for histopathological examination for any presence of tumour cells. The tissue section doesn't reveal much tumor cells as much of the field is covered by hemorrhages in the tissue.

Hemangiosarcoma (HSA), an aggressive, malignant tumor originating from vascular endothelial cells, is the most common splenic tumor in dogs, accounting for 51% to 66% of all splenic neoplasms [1-4]. Canine HSA is locally infiltrative and readily metastasizes hematogenously through lymphatic drainage or via local seeding after tumor rupture [3-5]. Greater

than 80% of cases are reported to have metastasized by the time of clinical diagnosis, with common sites of metastasis including the lung, liver, and omentum [3, 4, 6]. Up to 25% of the splenic tumors have a corresponding cardiac tumor (right atrial and auricular) [1, 4]. Hemangiosarcoma can affect almost any breed of dog, but German shepherd, golden retriever, and Labrador retriever breeds seem to be the most affected [3-5]. The tumor occurs predominantly in older dogs between 8 and 10 years of age; mean age at time of diagnosis is 9 to 12 y [1-4]. Thrombocytopenia (Table no. 1) is the most common hemostatic abnormality for dogs with HSA [2, 3, 7]. (Fig. 1 & 2) Hemangiomas and HSA are usually readily differentiated from each other based on histopathology alone, with hemangiomas having a more uniform appearance and organized architecture. The neoplastic endothelial cells in hemangiomas have minimal anisokaryosis, very low mitotic rate and appear more differentiated than those of HSA [1, 9]. Unlike HSA, hemangiomas are often curable with complete surgical resection alone [3]. However, HSA can sometimes be difficult to identify because it tends to be heterogeneous in appearance and can be pleomorphic on histological examination. This may lead to confusion with other soft tissue sarcomas or undifferentiated carcinomas [5, 6, 9]. The HSA tumor is usually located around the periphery of the lesion in-situ, with hematoma and necrosis accounting for most of the mass seen grossly [3]. This risk unsuccessful capture of a representative sample on biopsy.

## Conclusion

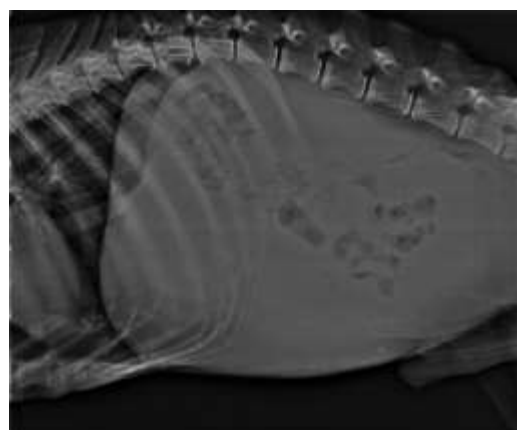As it is a condition with grave prognosis, it is better for the owner to have routine check-ups of the dog. If the dog seems very much lethargic, it is best to go for diagnostic imaging to eliminate the possibility of hemangiosarcoma. It can also help the veterinary clinician to treat and prevent the advances in disease course in case of hemangiosarcoma.

**Table 1:** Haematology Results

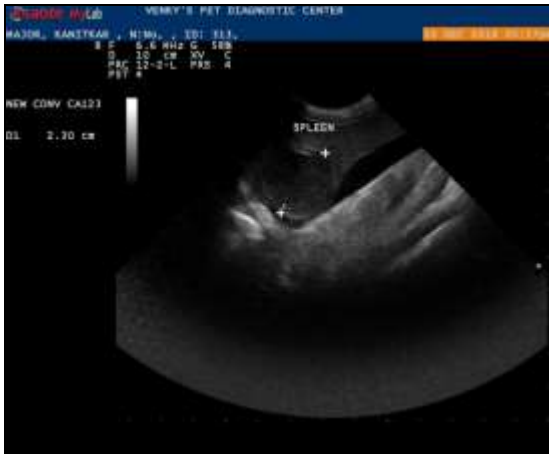Parameter	Result	Ref. interval	Interpretation
Haematocrit (%)	27.8	37.0-55.0	LOW
Haemoglobin (g/dL)	9.3	12.0-18.0	LOW
MCHC (g/dL)	33.5	30.0-36.9	
Total Erythrocyte count (Millions/ $\mu$ L)	4.63	4.8-9.3	LOW
Total Leucocyte Count (per $\mu$ L)	33200	6000-16900	HIGH
Total Lymphocyte/Monocyte count (per $\mu$ L)	12300	1100-6300	HIGH
Platelet Count (K/ $\mu$ L)	391000	175000-500000	

**Table 2:** Serum Biochemistry

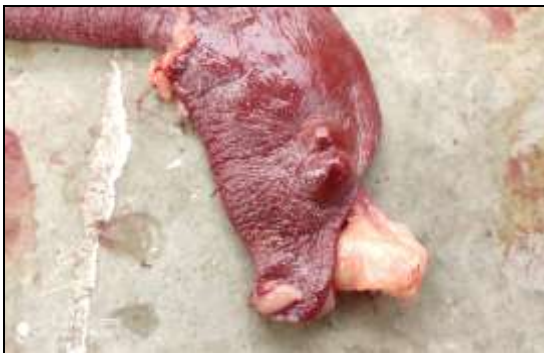Parameter	Result	Ref. Interval	Interpretation
BUN (mg/dL)	28.0	7-27	HIGH
Creatinine (mg/dL)	1.3	0.5-1.8	
Uric Acid (mg/dL)	<0.1	0.0-1.0	
Total Protein (g/dL)	5.3	5.2-8.2	
Albumin (g/dL)	2.2	2.2-3.9	
Globulin (g/dL)	3.1	2.5-4.5	
A:G ratio	0.7:1	0.7:2.0	
ALT (U/L)	43	10-100	
AST (U/L)	76	0-50	HIGH
ALKP (U/L)	83	23-212	
T. Bilirubin (mg/dL)	<0.1	0.0-0.9	
CPK (U/L)	1310	59-895	HIGH
Amylase (U/L)	779	500-1500	
Lipase (U/L)	609	200-1800	



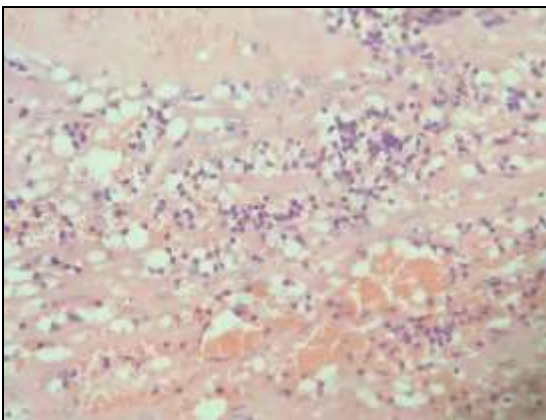
**Fig 1:** Left lateral radiograph of the abdomen showing hemoabdomen



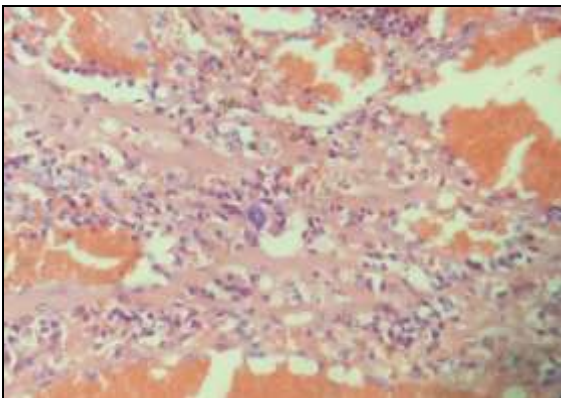
**Fig 2:** ultrasonography showing hypoechoic enlarged spleen



**Fig 3:** Photomicrograph of spleen showing nodular structure



**Fig 4:** Splenic tissue showing congested foci with dilated blood vessels



**Fig 5:** splenic parenchyma showing congested blood vessels and presence of neoangiogenesis with neoplastic features of vascular endothelium with large nucleus and proliferative changes

### Acknowledgement

We are obliged and thankful to Dr. Chandrakant Mote (Assistant professor, Dept of Pathology, Shirwal Veterinary College) for his valuable insight on the histopathological interpretation.

### References

1. Helfand SC. Canine hemangiosarcoma: A tumor of contemporary interest. *Cancer Therapy* 2008;6:457-462.
2. Chaikin P, Welihozkiy A. Hemangiosarcoma in a Dog: Unusual Presentation and Increased Survival Using a Complementary/Holistic Approach Combined with.
3. Metronomic Chemotherapy. *Hindawi Case Reports in Veterinary Medicine*, 2018. Article ID 6160980. <https://doi.org/10.1155/2018/6160980>
4. Withrow SJ, Vail DM. *Small Animal Clinical Oncology*. St. Louis, Missouri: Elsevier 2001, 639-644.
5. Clifford CA, Mackin AJ, Henry CJ. Treatment of canine hemangiosarcoma: 2000 and beyond. *J Vet Intern Med*. 2000;14:479-485.
6. Bertazzolo W, Dell'Orco M, Bonfanti U *et al*. Canine angiosarcoma: Cytologic, histologic and immunohistochemical correlations. 2005. *Vet Clin Path*; 34: 28-34. 6. Ferrer L, Fondevila D, Rabanal RM, Vilafranca M. Immunohistochemical detection of CD31 antigen in normal and neoplastic endothelial cells. *J Comp Path* 1995;112:319-326.
7. Fankhauser R, LeRoy BE, Tarpley HL, Bain PJ, Johnson MA, Latimer KS. Canine Hemangiosarcoma. *Vet Clin Path Clerkship Program*, 2004. <http://www.vet.uga.edu/VPP/clerk/frankhauser/index.php>
8. Hammer AS, Couto CG, Swardson C. Hemostatic abnormalities in dogs with hemangiosarcoma. *J Vet Intern Med* 1991, 511-514.
9. Hsieh TC, Wu P, Park S, Wu JM. Induction of cell cycle changes and modulation of apoptogenic/anti-apoptotic and extracellular signalling regulatory protein expression by water extracts of I'm-Yunity (PSP). *BMC Complementary and Alternative Medicine* 2006;6(30).
10. Luna LG. *Manual of histology staining methods of Armed Forces Institute of Pathology*, Mc graw Hill Book Company, New York, 1968.