Journal of Entomology and Zoology Studies

Available online at www.entomoljournal.com

E-ISSN: 2320-7078
P-ISSN: 2349-6800
www.entomoljournal.com
JEZS 2021; 9(1): 1229-1233

Received: 30-10-2020
Accepted: 28-12-2020

Biswajit Dutta
Assistant Professor, Department of Veterinary Pathology, College of Veterinary Science, Assam Agricultural University, Khanapara, Guwahati, Assam, India

Krishna Kalita
Department of Veterinary Pathology, College of Veterinary Science, Assam Agricultural University, Khanapara, Guwahati, Assam, India

Sulekha Choudhary Phukan
Professor, Department of Veterinary Parasitology, College of Veterinary Science, Assam Agricultural University, Khanapara, Guwahati, Assam, India

Karthikan Sadhasivam
MVSc Scholar, Department of Veterinary Pathology, College of Veterinary Science, Assam Agricultural University, Khanapara, Guwahati, Assam, India

Smita Kakoti
MVSc Scholar, Department of Veterinary Public Health, College of Veterinary Science, Assam Agricultural University, Khanapara, Guwahati, Assam, India

Rishabh Sarmah
MVSc Scholar, Department of Veterinary Pathology, College of Veterinary Science, Assam Agricultural University, Khanapara, Guwahati, Assam, India

Corresponding Author:
Biswajit Dutta
Assistant Professor, Department of Veterinary Pathology, College of Veterinary Science, Assam Agricultural University, Khanapara, Guwahati, Assam, India

Pathology of Aspergilosis in ducks and its clinical management

Biswajit Dutta, Krishna Kalita, Sulekha Choudhary Phukan, Karthikan Sadhasivam, Smita Kakoti and Rishabh Sarmah

DOI: https://doi.org/10.22271/j.ento.2021.v9.i1q.8309

Abstract
The present study was carried out to investigate the pathology of Aspergillosis in ducks. A total of 10 cases were recorded during the months of June & July, 2019. The diagnosis was made on the basis of clinical signs, gross & microscopic alterations and isolation of the fungus. The clinical signs observed in the affected ducks include respiratory distress, dyspnoea, gasping and accelerated breathing associated with loss of appetite, stunted growth, lethargy and increased thirst. Grossly, there were presence of white-yellowish caseous nodules in the lung, airsacs, gizzard, liver, thoracic wall and abdominal serosa. Histopathological examination revealed the presence of focal granulomatous lesions in the lungs characterized by central necrotic area with infiltration of heterophils, macrophages, epithelioid cells and formation of giant cells. Similar type of lesions were also recorded in liver and gizzard. Invasion of fungal hyphae at the peri-bronchiolar and interstitial tissue and haemorrhages were also noticed. On the 5th day post incubation, there were presence of blackish green colonies in the SDA plates.

Keywords: Aspergillosis, Assam, ducks, pathology

Introduction
Aspergillosis is a non-contagious disease of avian, which is caused by a fungal species under the genus *Aspergillus*. This mycosis was described many years ago, but continues to be a major cause of mortality in captive birds and less frequently, in free-living birds. Although Aspergillosis is predominantly a disease of the respiratory tract, all organs can be involved [1]. The disease occurs under immune compromised situations of the host or when the bird is exposed to an overwhelming number of spores. Stress is the main predisposing factor for the development of the disease [2]. The disease can occur as an acute form with high mortality and morbidity especially in brooding age called brooder pneumonia [3], but also has the tendency of chronic form in older birds. The clinical signs observed in these birds were respiratory distress, dyspnoea, gasping and nasal discharge in some birds [4]. The warm, humid environment of the farm sheds, feed stores, floor etc., favor its growth. It is a contaminant of every environment because of its adaptability to growth substrates and the production of spores that remain viable under extremely harsh conditions [5]. Typical lesions are fungal nodules or plaques within the lungs and on the air sacs [6].
This present paper deals with the Aspergillosis in ducks. A detailed gross and microscopic pathology and clinical management Aspergillosis has been discussed.

Materials and Methods
Ethical approval
The approval from the Institutional Animal Ethics Committee (IAEC) was not required for the present study since the samples were collected from the animals without animal experimentation and dead animals during necropsy.

Sample collection
The study was conducted to diagnose aspergillosis in ducks during physical visit of the farms and when submitted for post- mortem examination to the Department of Pathology, CVSc, AAU, Khanapara, Guwahati-22 (Assam). The clinical signs exhibited by the affected birds and the history provided by the farmers were properly recorded.

Necropsy and Histopathological examination

The post-mortem was carried out systematically following standard protocol on the birds. The physical condition of the birds and the gross alterations in different organs were carefully recorded. For histopathological examination, representative tissue samples were collected in 10% formol saline solution. After proper fixation, paraffin embedded tissue sections of 4-6µ were prepared and stained by routine Haematoxylin & Eosin technique for microscopic examination [7]. Direct microscopic examination was performed by using Lactophenol cotton blue in the impression smear for detection of the fungi.

Isolation of the Fungus

The isolation of the *Aspergillus* spp. was carried out from the affected organs i.e. lung, liver and airsac. The samples were inoculated to Sabouraud Dextrose Agar (SDA) plates and incubated at 37 ◦C for 7 days. *Aspergillus fumigatus* was identified according to its specific colony characteristics, slides were also prepared for identification of mycelium and hyphial arrangement with lactophenol blue staining method [8].

Results and Discussion

Aspergillosis may involve many body systems; fungal spores most commonly invade trachea, air sacs and lung. Signs depend on the number of spore that enters the body and organ system affected but can be generally reflected as disease of respiratory tract, occasionally the CNS [9].

The clinical sign observed in the affected ducks includes respiratory distress, dyspnoea, gasping and accelerated breathing associated with loss of appetite, stunted growth, lethargy and increased thirst. The clinical signs are in agreement with the earlier findings in poultry [10, 11]. The rapid and difficult breathing and start breathing with an open mouth (gaspers) due to the gradual obstruction of the air passage [12]. On the otherhand Ambily and Mini (2017) reported that there was no clinical signs except for listlessness and dyspnoea in Japanese Quail during outbreak of Aspergillosis [13]. Planel *et al.* (2001), Bhattacharya (2003) and Chu *et al.* (2012) reported similar findings in commercial duck flocks [14-16].

On post mortem examination, there was presence of white-yellowish caseous circumscribed plaques throughout the lungs surface, inside the lungs, scattered in ventral surface of sternum, air passages (Fig. 1A) and airsacs (Fig. 1B) . Similar lesions could also been seen in heart and thoracic wall. The size of the nodules varies from few mm to several cm in diameter. The lung parenchyma was consolidated. Similar findings of nodular lesions were reported [17, 18].

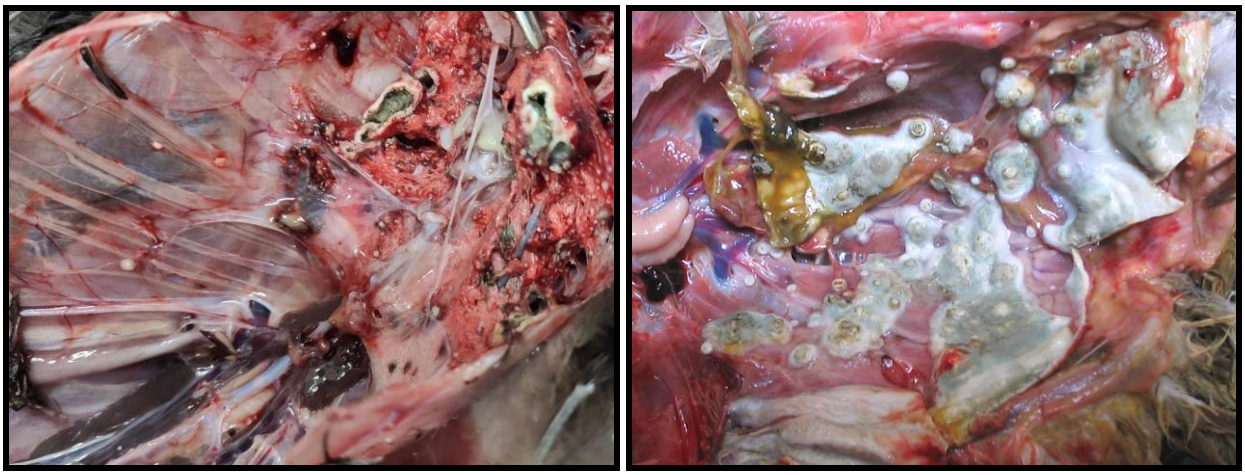

A. B.

Fig 1: Gross lesion in Aspergillosis, white-yellowish caseous circumscribed plaques **(A)** throughout the lungs surface, inside the lungs, scattered in ventral surface of sternum, air passages **(B)** airsacs.

In few cases, white-yellowish caseous lesions could also been seen in the hepatic parenchyma (Fig. 2A) with or without mottling of the spleen. Similar lesions in the liver and spleen were described [13]. However, Femenia *et al*., 2010 could not able to produce the lesions in the liver and brain during experimental infection [19]. Similar white-yellowish caseous lesions were also seen in serosal surface of the intestine (Fig. 2B) and gizzard. Richard (1991) explained that after 6 days of exposure, inflammatory and necrotic foci seemed to regress in surviving birds exhibiting well-organized granulomas encapsulated by a thick layer of fibrous tissue [6]. Musa *et al* (2014) also reported similar lesions in the intestine and gizzard along with along with trachea, heart, lung and pancreas [20]. Presence of lesions in different organs like lung, airsac, gizzard, intestine etc. indicated systemic spread of the fungus. Arne (2011) established that after 24 hpi via aerosol route, the conidia appeared in the circulation [21].

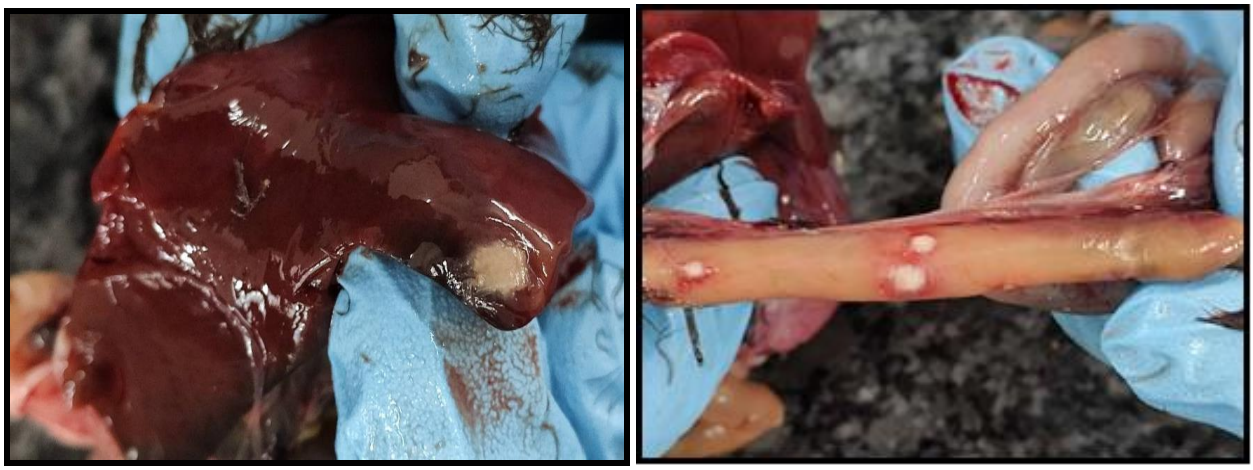

A. B.

Fig 2: Gross lesion in Aspergillosis, white-yellowish caseous circumscribed plaques **(A)** in the liver **(B)** in intestinal serosa.

Microscopically, focal granulomatous reaction was observed in the lungs (Fig. 3A). The center of the granulomatous foci contained caseous necrosis and necrotic cellular debris surrounded by rims of heterophils, lymphocytes, macrophages, epithelioid cells and multinucleated giant cells (Fig. 3B). The alveoli and the bronchiolar lumina were filled with heterophils and necrotic debrices. The findings of present study was strongly agreement with the previous study [13, 22]. The normal architecture of the lung and air sacs were replaced by disseminated granulomatous foci. Various fungal elements like conidia and septate hyphae (Fig. 3B) seen. Ambily and Mini (2017) also demonstrated fungal hyphae in the tissue [13].

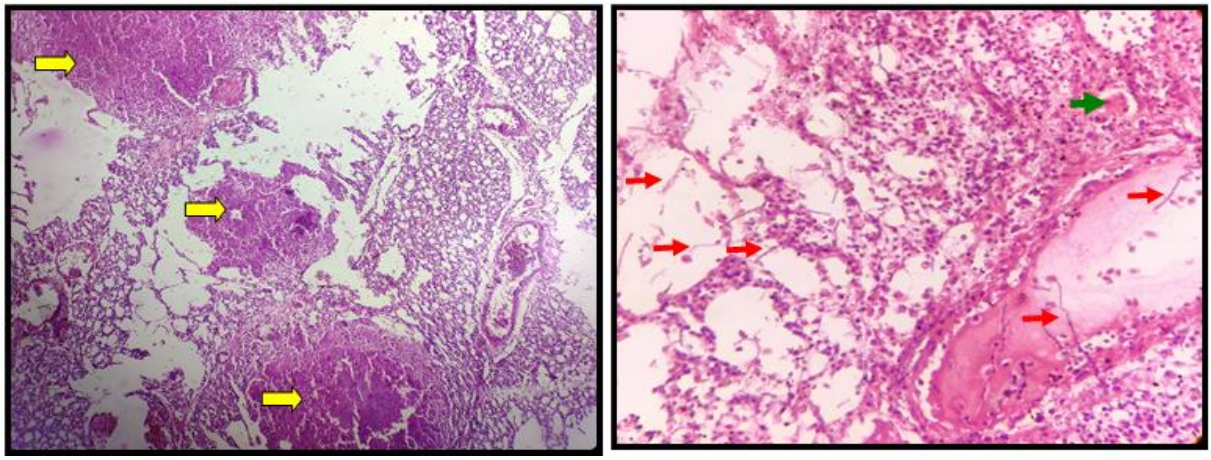

A. B.

Fig 3: Microscopic lesion in Aspergillosis **(A)** focal granulomatous reaction in the lungs (yellow arrow); **(B)** infiltration of heterophils, lymphocytes, macrophages, epithelioid cells and formation of multinucleated giant cells (green arrow) and presence of fungal hyphae (red arrow).

More severe, inflammatory lesions on the pleura and the underlying pulmonary lobules of lungs in experimentally infected *Aspergillus fumigates* infection was studied earlier [19].

The air sacs membranes were thickened due to infiltration of heterophils, lymphocytes & macrophages. Giant cells were also seen in the membrane. Airsacculitis and mycotic granulomatous pneumonia was also reported earlier by Kaboudi *et al* (2018), where branched septate hyphae, about 10–15 µm in diameter were demonstrated [4].

Our findings are in concordance with the results of Richard *et al.* (1991), Chu *et al.* (2012) and Sultana *et al.* (2014) in commercial turkeys, ducks and chickens, respectively [6, 16, 18].

Hubben (1958) described the same lesions found in meninges and cerebral sections in ducks and turkeys manifesting nervous symptoms caused by *Aspergillus* spp. Infection [23]. Mycelia may be visible in necrotic centers in haematoxylin-and-eosin stained sections either as unstained or faintly basophilic staining mycelia but they are best demonstrated with fungal stains [34].

On the 5th day post incubation, blackish green colonies were observed on the SDA plates (Fig. 4A). Lactophenol cotton blue staining of these colonies revealed conidiophore with flask shaped vesicle and large number of conidia (Fig. 4B). On the basis of these microscopic and macroscopic features, the fungus was identified as *Aspergillus fumigates.*

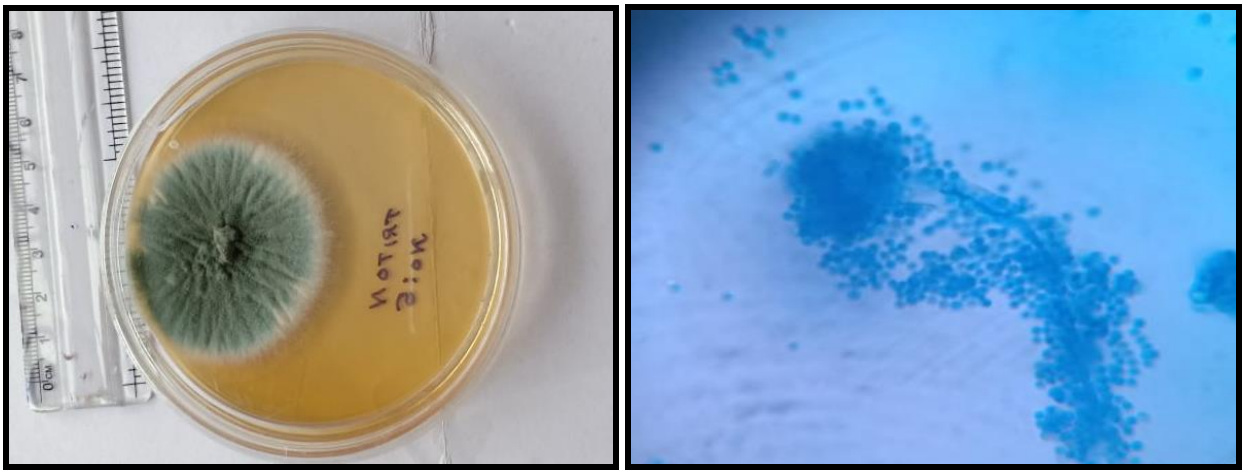

A. B.

Fig 4: (A) in SDA after 5 dpi; (B) conidiophore with flask shaped vesicle and large number of conidia

In this way, the microscopic structures, associated to the cultural properties (growth, colonies aspect), corresponding to the genus *Aspergillus* and are considered as a diagnosis criteria of the fungal species [25]. Our findings were in agreement with the results of Yokota *et al.* (2004), Sajid *et al.* (2006) and Dutta *et al*. (2017) who reported that white to green mold growth on the walls of caseous thickened air sacs of infected ostrich, commercial poultry flocks and broiler respectively [5, 10, 26]. Ustimenko (1982) also isolated *Aspergillus fumigatus* from lung tissue of dead chicken [27].

The ducks of the affected flock was treated with Copper sulphate solution. Fresh stock solution was prepared by dissolving 50 gm of copper sulphate in a mixture of 250 ml vinegar and 750 ml clean water. Then 2 ml of the stock solution/litre of drinking water was given for 7 days. At the same time, Griseofulvin tab was given @ 2mg/lit drinking water for 7 days. Apart from this, litter materials were replaced. The treatment of the flock & the litter with copper sulphate was found to be effective as the severity of the clinical sign in the affected birds reduced from 3rd day and recovered completely within 5-7 days from commencement of the treatment. Musa *et al.* (2014) and Dutta *et al.* (2017) also used copper sulphate in the treatment of Aspergillosis [5, 20]. Leishangthem (2015) used include itraconazole, fluconazole, clotrimazole, miconazole, ketoconazole and amphotericin B for treating Aspergillosis in birds [28]. The disease condition might be occurred due to improper hygiene and sanitation with improper ventilation and high humidity which led to mouldy litter at the onset of rainy season [29].

Aspergillus commonly grows in damp soils, decaying materials, organic debris and free grains. High numbers of conidia are released into the atmosphere and are inhaled by human, bird and other animals. These spores travel through upper respiratory tract to the lungs. If spores are localized in the lungs, the fungi may be disseminated to other parts of the body and the diseases often leading to death [30]. The diagnosis can be confirmed by demonstration of characteristic organism with their septed hyphae in tissue section [31]. In the present study, the disease was diagnosed on the basis of history, clinical signs, gross & microscopic examination and isolation of the fungus.

Aspergillus spp. are opportunistic pathogens with ubiquitus distribution and they flare up under stressful circumstances causing acute infections especially in young birds. Acute aspergillosis causes high morbidity and heavy mortality within 24 to 48 hours of infection [32].

Humidity and temperature conditions encountered in poultry farms promote the rapid growth of hyphae resulting in a copious production of airborne hydrophobic conidia, which are later dispersed and inhaled by the birds resulting in heavy infection [33]. The presence of litter material adhering to the feet of the bird was an obvious indication of poor management practices in the farm. Hence, strict hygienic practices in the farm were recommended. Proper housing of the birds so as to avoid overcrowding, provision of feed with low moisture content and incorporation of dry litter material are essential pre requisites for successful quail farming because antifungal therapy is not of much use in this case.

Conclusion

In conclusion, the present investigation reported the clinico-pathological study of Aspergillosis in ducks. The disease was diagnosed on the basis of clinical signs, gross & microscopic lesions and isolation of the fungus.

Acknowledgments

Authors were highly grateful to PI, ADMaC, Core Lab-1, CVSc, AAU, Khanapara, Guwahati-22 (Assam) for providing necessary facilities for isolation of the fungus.

References

1. Beernaert LA, Pasmans F, Van WL, Haesebrouck F, Martel A. Aspergillus infections in birds: a review. Avian Pathology 2010;39(5):325-331.
2. Saif YM, Fadly AM, Glisson JR, McDougald LR, Nolan LK. Disease of poultry. 12th edn. Iowa State University Press, Ames, London 1999, 542-550.
3. Badhy SC, Amin KMR, Kabir SML, Paul BK, Das SK. Brooder pneumonia: Histopathological changes in the lungs of broiler chickens. International Journal of Biopharma Research 2003;1(1):55-58.
4. Kaboudi K, Rejeb A, Bouzouaia M, Munir MT, Umar S. Outbreak of Respiratory Aspergillosis in Backyard Duck Flock in Tunisia. International Journal of Livestock Research 2018;8(7):361-368.
5. Dutta B, Konch P, Konch C, Gogoi SM, Farhad HM, Kakoty SP. Clinicopathological studies of Brooder pneumonia in Broiler Chicken. International Journal of Chemical Studies 2017;5(3):510-512.
6. Richard JL. Aspergillosis In: Disease of Poultry. 9th edn.

Calnek BW, Barnes HJ, Beard CW, Reid WM, Yoder HW. Jr., eds. Iowa State University Press. Ames, Iowa. 1991, 326-334.
7. Culling CFA. Handbook of histological & histochemical technique. 3rd edn. Butterworth and Co 1974.
8. Darise HL. Medically important Fungi. A guide to identification 1987, 14-15.
9. Atlaman RB. Avian Medicine and Surgery. Saunders, Philadelphia, USA 1997, 89-92.
10. Sajid MA, Khan IA, Rauf U. *Aspergillus fumigatus* in commercial poultry flocks, a serious threat to poultry industry in Pakistan. Journal of Animal and Plant Sciences 2006;16(3-4):79-82.
11. Pascal A, Thierry S, Wang D, Deville M, Le Loc'h G, Desoutter A. *Aspergillus fumigatus* in Poultry. International Journal of Microbiology 2011;746356: 1-14.
12. Aguilar RF, Redig PT. Diagnosis and treatment of avian aspergillosis. Current Veterinary Therapy XII. Philadelphia, PA: WB Saunders 1995, 1294-1299.
13. Ambily R, Mini M. Incidence of Systemic Aspergillosis in Japanese Quails (*Coturnixcoturnix japonica*) in A Private Farm. Trends in Bioscience 2017;10(14):2593-2595.
14. Planel R, Herault L, Gavaret T. Granulomesd'originemycosiquesur des canes pékin futures reproductrices. Bull Group Technology Veterinary 2001;10:247-249.
15. Bhattacharya A. *Aspergillus fumigatus* infection in Khaki Campbell ducks in an organized duck farm in Tripura. Indian Veterinary 2003;80:1178-1179.
16. Chu KS, Kang MS, Lee JW. A case of Aspergillosis in commercial domestic ducks. Korean Journal of Veterinary Service 2012;35:165-168.
17. Akan M, Haziroglu R, Ilhan Z, Sareyyupoglu B. A case of Aspergillosis in a broiler breeder flock. Avian diseases 2002;49:497.
18. Sultana S, Harun-ur-Rashid SM, Islam N, Ali Z. Pathological investigation of avian Aspergillosis in commercial broiler chicken at Chittagong district. International Journal of Advances Research of Biological Sciences 2014;1(8):74-85.
19. Femenia F, Fontaine JJ, Lair-Fulleringer S, Berkova N, Huet D, Towanou N *et al*. Clinical, mycological and pathological findings in turkeys experimentally infected by *Aspergillus fumigates*. Avian Pathology 2010; 36(3):213-9.
20. Musa IW, Aliyu G, Ismail A. Aspergillosis in broilers: Reports of three cases from a commercial and two broiler breeder farms in Zaria, Nigeria. International Journal of Current Microbiology and Applied Sciences 2014;3:932-938.
21. Arne P, Thierry S, Wang D, Deville M, Le Loc'h G, Desoutter A *et al*. *Aspergillus fumigatus* in Poultry. International Journal of Microbiology 2011, 1-14.
22. Akkoc A, Yilmaz R, Cangul IT, Ozyigit OM. Pulmonary Aspergillosis and Amyloid Accumulation in an Ostrich (*Struthio camelus*). Turkish Journal of Veterinary and Animal Sciences 2009;33(2):157-160.
23. Hubben K. Case report: Aspergillus Meningo-Encephalitis in Turkeys and Ducks. Avian Diseases. 1958;2:110-116.
24. EL-Rawy EM, Khader AA, Mahmoud MS, Zaki ES. Preparation and evaluation of combined oil adjuvant vaccine against duck pasteurellosis and Riemerella anatipestifer infection in ducks. Group. 2020;5(1):18-21.
25. Hungerford LL, Campbell CL, Smith AR. Veterinary mycology laboratory manual. Ames: Iowa State University Press 1998.
26. Yokota T, Shibahara T, Wada Y, Hiraki R, Ishikawa Y, Kadota K. *Aspergillus fumigates* infection in ostrich (*Struthio camelus*). Journal of Veterinary Medicine and Science 2004;66(2):201-204.
27. Ustimenko AN. Aspergillosis of fowls and sanitary condition of incubators in U.S.S.R. Poultry Abstracts 1982;8(4):138.
28. Leishangthem GD, Singh ND, Brar RS, Banga HS. Aspergillosis in Avian Species: A Review Journal of Poultry Science and Technology 2015;3:01-14.
29. Okoye JO, Gugnani HC, Okeke CN. Pulmonary infections due to *Aspergillus flavus* in turkey poults and goslings. Mycoses 1989;3:336-339.
30. Powell KA, Renwick A, Peberdy JF. The genus Aspergillus: From taxonomy and genetics to industrial application. Plenum Press, New York 1994, 380.
31. Marks SL, Stauber EH, Ernstrom SB. Aspergillosis in an ostrich. Journal of American Veterinary Medical Association 1994;204:784-785.
32. Dhama KR, Barathidasan R, Tiwari R, Singh SD. "Aspergillosis: An Important Fungal Disease of Poultry and other Birds". Poultry World 2012;9:7-9.
33. Khosravi AR, Nosrati AC, Shokri H. Protein profiles of *Aspergillus* species isolated from tea gardens and factories air in northern Iran. Jundishapur Journal of Microbiology 2013;6(1):4-10.
34. Ficken MD. Respiratory System. In: Randall CJ, Reece RL, editors. Color Atlas of Avian Histopathology. London: Mosby-Wolfe 1996, 89-109.