Journal of Entomology and Zoology Studies

Available online at www.entomoljournal.com

E-ISSN: 2320-7078
P-ISSN: 2349-6800
www.entomoljournal.com
JEZS 2021; 9(2): 127-129

Received: 22-01-2021
Accepted: 24-02-2021

Tuan Van Ngo
(1) Hong Bang International University, Ho Chi Minh City, Vietnam
(2) Graduate University of Science and Technology, Vietnam Academy of Science and Technology, Ha Noi City, Vietnam

Thuan Thi Tran
Hong Bang International University, Ho Chi Minh City, Vietnam

Nga Thi Nguyen
Hong Bang International University, Ho Chi Minh City, Vietnam

Chi Nguyen Quynh Ho
(1) Graduate University of Science and Technology, Vietnam Academy of Science and Technology, Ha Noi City, Vietnam
(2) Institute of Tropical Biology, Vietnam Academy of Science and Technology, Ho Chi Minh City, Vietnam

Tram Le Ngoc Vo
Xuan Dieu Secondary school, My Tho City, Tien Giang Province, Vietnam

Long Thanh Le
(1) Graduate University of Science and Technology, Vietnam Academy of Science and Technology, Ha Noi City, Vietnam
(2) Institute of Tropical Biology, Vietnam Academy of Science and Technology, Ho Chi Minh City, Vietnam

Thao Thi Phuong Nguyen
(1) Graduate University of Science and Technology, Vietnam Academy of Science and Technology, Ha Noi City, Vietnam
(2) Institute of Tropical Biology, Vietnam Academy of Science and Technology, Ho Chi Minh City, Vietnam

Corresponding Author:
Long Thanh Le
(1) Graduate University of Science and Technology, Vietnam Academy of Science and Technology, Ha Noi City, Vietnam
(2) Institute of Tropical Biology, Vietnam Academy of Science and Technology, Ho Chi Minh City, Vietnam

Effects of lead on structures of zebrafish intestine and oocytes

Tuan Van Ngo, Thuan Thi Tran, Nga Thi Nguyen, Chi Nguyen Quynh Ho, Tram Le Ngoc Vo, Long Thanh Le and Thao Thi Phuong Nguyen

Abstract
This study aimed to assess the effects of lead exposure on structure of intestine and oocytes of zebrafish. Zebrafish were exposed to lead in various concentration at 0.1 µg/l, 1 µg/l, 10 µg/l, 20 µg/l, 100 µg/l. The results demonstrated that zebrafish from lead treatment group exposed the modification structure of intestine, by an increase of intestinal villi and cell number. Lead treatment induced the reduction of lipid droplet number in zebrafish oocytes. However, the increased lead concentration was resulted in the increase of lipid droplet in zebrafish oocytes. These results revealed that lead exposure can give rise to the abnormality on structure of intestine and oocytes of zebrafish.

Keywords: intestine, oocyte, lead exposure, zebrafish

Introduction
Heavy metals are widely used in the industrial production process. Heavy metals are well-known environmental pollutants due to their toxicity, persistence in the environment, bioaccumulative nature, and directly affect the health of human and organism. Health risks come from the toxicity of heavy metals mainly include kidney and skeletal damages, neurological disorders, endocrine disruption, cardiovascular dysfunction, and carcinogenic effects [1]. Copper can induced the changes in the gastrointestinal, cardio-vascular, hematological, hepatic, renal, and CNS function. Zinc can give rise to vomiting, chest tightness, nausea, excitement, coldness, unconsciousness, and coma; even death may occur from pulmonary edema and liver damage. Higher Iron intake may cause to vomiting, diarrhea, gastrointestinal bleeding, metabolic acidosis, shock, hypo-tension, tachycardia, cardiovascular collapse, coagulation deficits, hepatic necrosis, and possibly death. Manganese can result in dopaminergic dysfunction, neurochemical, neurobehavioral, neuroendocrine changes, and cardiovascular toxicity [2, 3].
Zebrafish showed a numerous advantages to be a toxicological testing model. The first characteristic regards to their small size, husbandry, and early clear morphology [4]. This investigation aimed to evaluate the effects of lead exposure on structure of intestine and oocyte of zebrafish.

Material and Methods
Animals
The zebrafish were kept in the laboratory for one week for the beginning of the experiments to make sure they were free of disease. Fish were bred in a 14 h:10 h Light: Dark cycle. The fish were fed daily with commercially dry flakes. Zebrafish were treated with lead in different concentration, including 0.1 µg/l, 1 µg/l, 10 µg/l, 20 µg/l, 100 µg/l. Fish from control group were bred in tank without lead exposure.

Hematoxylin and Eosin staining
After lead treatment, the intestine and oocytes were collected and fix in 4% paraformaldehyde. The samples were used for Hematoxylin and Eosin staining in University of Medicine and Pharmacy, Ho Chi Minh City. Structures of intestine and oocytes were observed and analyzed under microscope.

Statistical analysis

Data are presented in the format mean ± SD. The samples were triplicated and the difference between the experimental groups was assessed using one way ANOVA analysis. After comparing by ANOVA, the result is considered to have significantly different value when $P<0.05$.

Results

Lead treatment induced the morphological changes in zebrafish intestine. The Figure 1 demonstrated that the increase of intestinal villi was observed in zebrafish treated with high lead concentration. In addition, the cell number in intestinal villi was also increased in zebrafish from high lead concentration treatment group. These results revealed that lead treatment gave rise to the abnormality in zebrafish intestine.

As seen in the Figure 2, the morphology of oocyte was changed in zebrafish treated with lead. The number of lipid droplet was decreased in oocyte of zebrafish treated with high lead concentration. However, the lipid droplet diameter of zebrafish from lead treatment group was higher than the control group.

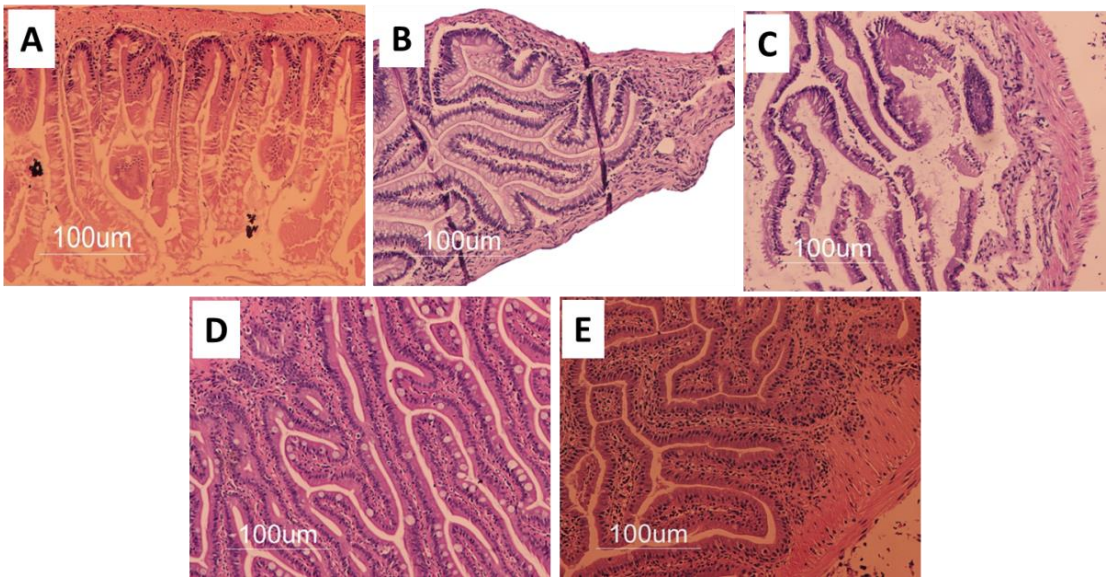

Fig 1: Intestine structure of zebrafish by HE staining. A: control group; B, C, D, E: groups of 0.1 µg/l, 1 µg/l, 10 µg/l, 100 µg/l. Scale bar: 100 µm.

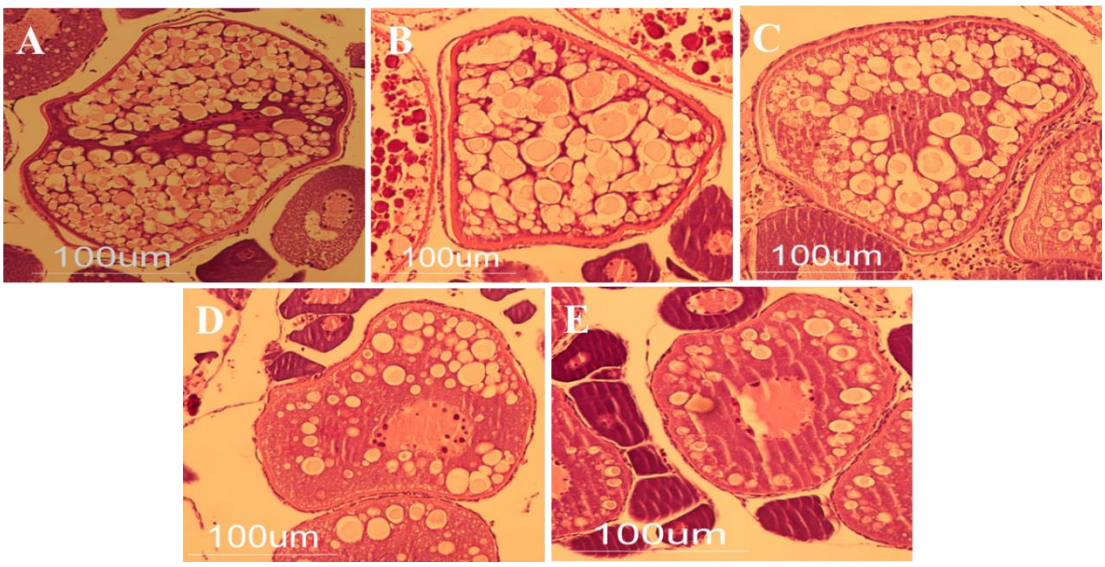

Fig 2: Oocyte structure of zebrafish by HE staining. A: control group; B, C, D, E: groups of 0.1 µg/l, 1 µg/l, 10 µg/l, 100 µg/l. Scale bar: 100 µm.

Discussion

The aim of this study is to determine the morphological changes in intestine and oocytes of zebrafish exposed to lead. These above results showed that lead exposure of zebrafish was resulted in the modification of intestine and oocyte structure, especially in intestinal villi and lipid droplet. The previous study reported that, 5 ppm lead exposure for 30 days is gives rise to decrease lipid droplet total, phospholipid and cholesterol in liver and oocyte of *Anabas testudineus* fish during reproductive season [5].

According to research by Jinling Cao (2019), heavy metals can suppress the growth of zebrafish and significantly affect reproduction in both sexes by damaging the structure of the gonads, altering steroid hormone levels and expression of endocrine-related genes in zebrafish. This study showed that heavy metals adversely affect the reproductive endocrine system in zebrafish and showed a potential threat to fish populations living in metal contaminated waters [6]. Changes

caused by heavy metal contaminants during oocyte maturation may be related to egg toxicity, metal accumulation in eggs or direct effects of metals on gene generation. The oocyte maturation is most sensitive to metal toxicity. Consequently, various disturbances caused by heavy metal contaminants during oocyte development lead to decreased egg quantity and quality [7]. In the study of Chhaya Bhatnagar *et al*. (2007), Fluoride induced the degeneration in the intestinal mucosa and villi [8]. Microscopic changes in the intestinal tissue exhibited many degenerative bacteria inside the lumen attached to the intestinal epithelium, this binding is associated with impairment of intestinal cells and microvilli [9]. According to El-Sayed Mohamed Younis *et al*. (2013), the observation of histopathological changes in the intestines of both *Oreochromis niloticus* and *Lates niloticus* showed the serious degenerative and necrotic changes in the intestinal mucosa under cadmium exposure [10]. This study has identified the negative effects of lead in the zebrafish intestine and oocytes. The further research is still needed to expand understanding into the effects lead exposure on structure and function of other organs in zebrafish

Acknowledgements
This work is funded by Hong Bang International University under grant code GV2008.

References

1. Renieri EA, Alegakis AK, Kiriakakis M, Vinceti M, Ozcagli E, Wilks MF *et al*. Cd, Pb and Hg Biomonitoring in Fish of the Mediterranean Region and Risk Estimations on Fish Consumption. Toxics 2014;2(3):417-442.
2. Renieri EA, Safenkova IV, Alegakis AK, Slutskaya ES, Kokaraki V, Kentouri M *et al*. Cadmium, lead and mercury in muscle tissue of gilthead seabream and seabass: Risk evaluation for consumers. Food and Chemical Toxicology 2019;124:439-449.
3. Yadav KK, Gupta N, Kumara V, Choudharyb P, Khan SA. GIS-based evaluation of groundwater geochemistry and statistical determination of the fate of contaminants in shallow aquifers from different functional areas of Agra city. India: levels and spatial distributions. RSC Advances 2018;8:15876-15889.
4. Hill AJ, Teraoka H, Heideman W, Peterson RE. Zebrafish as a Model Vertebrate for Investigating Chemical Toxicity. Toxicological Sciences 2005;86(1):6-19.
5. Tulasi SJ, Reddy PJ, Rao JVR. Accumulation of lead and effects on total lipids and lipid derivatives in the freshwater fish *Anabus testudineus* (Bloch). Ecotoxicology and Environmental Safety. 1992;23:33-38.
6. Cao J, Wang G, Wang T, Chen J, Wenjing G, Wu P *et al*. Copper caused reproductive endocrine disruption in zebrafish (Danio rerio). Aquatic Toxicology 2019, 211.
7. Ambani MM. Effects of reproductive biology on heavy metal pollution on the histopathological structure of gonads in India. Department of Zoology. Acharya NG Ranga Agricultural University, Hyderabad, India, 2015.
8. Chhaya Bhatnagar MBBCR. Fluoride-induced histopathological changes in gill, kidney, and intestine of fresh water teleost, *Labeo rohita*. Fluoride 2007; 40(1):55-61.
9. Abdelhamed H, Ibrahim I, Baumgartner W, Lawrence ML, Karsi A. Characterization of Histopathological and Ultrastructural Changes in Channel Catfish Experimentally Infected with Virulent Aeromonas hydrophila. Frontiers in Microbiology 2017;15(8):1519.
10. Younis ESM, Abdel-Warith AWAM, Nasser AAA, Ebaid H, Mubarak M. Histological Changes in the Liver and Intestine of Nile Tilapia Oreochromis niloticus, Exposed to Sublethal Concentrations of Cadmium. Pakistan Journal of Zoology 2013;45(3):833-841.