



E-ISSN: 2320-7078

P-ISSN: 2349-6800

www.entomoljournal.com

JEZS 2021; 9(2): 572-577

© 2021 JEZS

Received: 15-12-2020

Accepted: 02-02-2021

Tanvi Mahajan

Division of Veterinary Anatomy,
Sher-e-Kashmir University of
Agricultural Sciences &
Technology, Jammu, Jammu
and Kashmir, India

Kamal Sarma

Division of Veterinary Anatomy,
Sher-e-Kashmir University of
Agricultural Sciences &
Technology, Jammu, Jammu
and Kashmir, India

Jonali Devi

Division of Veterinary
Physiology and Biochemistry,
Sher-e-Kashmir University of
Agricultural Sciences &
Technology, Jammu, Jammu
and Kashmir, India

Corresponding Author:**Tanvi Mahajan**

Division of Veterinary Anatomy,
Sher-e-Kashmir University of
Agricultural Sciences &
Technology, Jammu, Jammu
and Kashmir, India

Histological and histochemical studies on the development of nephron and juxta glomerular apparatus in goat foetii (*Capra hircus*)

Tanvi Mahajan, Kamal Sarma and Jonali Devi

Abstract

The present study was conducted on the kidneys of 18 goat foetii which were divided into three groups based on their estimated ages containing 6 foetii in each group. At 45 days of gestation (Crown Rump Length, CRL=5.3 cm), the differentiating mesenchymal cells near the capsule were observed having a cord like arrangement. At 50 days of gestation (CRL=7.6 cm), the formation of the nephrogenic vesicles and their elongation into S-shaped structures increased in all the three zones of the cortex *i.e.* subcapsular, intermediate and juxta medullary zones. At 59 days (CRL=8.10 cm) of gestation, the renal corpuscles of the juxta medullary region of the kidney resembled those of the mature kidney in shape and structure. At 62 days (CRL=10.10 cm) of foetal age, true juxta glomerular cells were noticed. Majority of the histochemicals exhibited increased reactions in the kidney with advancing gestational age of the goat foetii. It could be concluded that the microscopic structures of the goat kidney showed development with the advancement of foetal age.

Keywords: Foetii, goat, histochemistry, histology, juxta glomerular apparatus, nephron

1. Introduction

Kidneys are the main organs of the urinary system which are responsible for the regulation of fluid volume, acid base balance and electrolyte composition^[1]. The development of the kidney is a complicated process in all mammals as it develops into pronephros, mesonephros and metanephros^[7]. The pronephros and mesonephros degenerated during prenatal life but the metanephros form in lumbar region and remains on the functional kidney in adults. The development of metanephros in animals follows an accelerated time course when compared with the human^[2]. In ungulates, it becomes functional at an early embryonic age due to the low permeability of placenta^[4]. Paucity of available literature on the nephron and juxta glomerular apparatus of the metanephros in goat foetii prompted this present study.

2. Materials and Methods

The present study was conducted on 18 goat foetii which were collected from the slaughter houses in and around Jammu city and were investigated in the Division of Veterinary Anatomy, Faculty of Veterinary Sciences & A.H., SKUAST-J, R. S. Pura, Jammu. These foetii were ranged from early pregnancy to near full term. Immediately after collection, the umbilical cords of these foetii were ligated properly and were cleaned with cotton soaked with water to remove the amniotic fluid. The weight of each foetus was recorded with the help of analytical balance. The approximate age of the foetii was calculated by putting the body weight values in the formula postulated^[15] for estimation of age in goat foetii as mentioned below-

Formula for estimation of foetal age in goat^[15]

$$W^{1/3} = 0.096 (t-30).$$

Where, W= body weight of foetus in gm.

t= age of the foetus in days.

The collected foetii were then divided into three groups based on their estimated ages *viz.* Group-I (below 50 days), Group-II (between 50 to 100 days) and Group-III (above 100 days of age), each group containing at least 6 foetii in each group. After estimation of age, the kidneys were used for histological and histochemical studies.

The kidneys were fixed in 10% Neutral Buffered Formalin solution [10]. The tissue pieces from the kidneys were processed for paraffin block preparation by an alcohol-benzene schedule [10]. Tissue sections of 5-6 μ thickness were obtained from these blocks on clean glass slides with the help of rotary microtome and subsequently subjected to staining with various histological and histochemical methods.

3. Results and Discussion

Histology

Nephron

Group-I

At 45 days of gestation (CRL=5.3 cm), the differentiating mesenchymal cells near the capsule were observed having a cord like arrangement and at few places, they were arranged in clusters. The mesenchymal cells in some areas of the cortex, aggregated as nephrogenic vesicles. A vesicle at one of the ends of a dividing ampulla grew into a double walled S-shaped body (Fig. 1) consisted of the lower cup shaped and upper tubular segments. This was in agreement with the findings reported in rat foetus [12]. According to them, they observed no developed glomeruli in the kidneys where dense mesenchymal tissue takes place in the early stage of development.

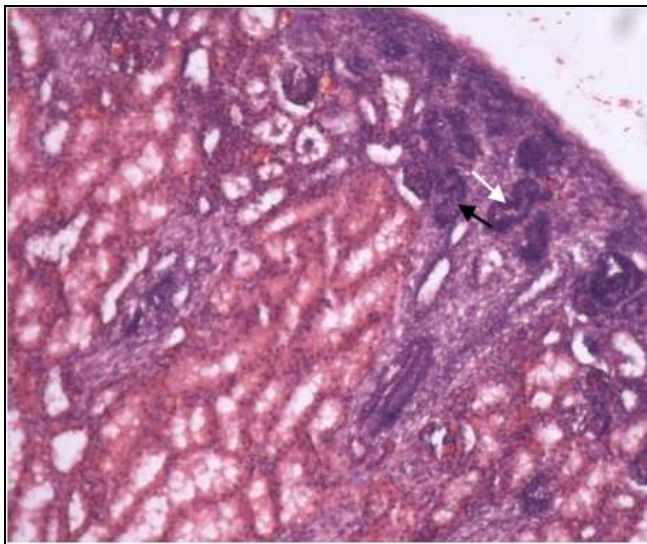


Fig 1: Photomicrograph of the kidney of 45 days old goat foetus showing S-shaped bodies (arrows), H&E, 100X.

At 48 days of gestation (CRL=7.5 cm), the Bowman's capsule of the juxta medullary region enclosed a glomerular mass of cells and occasional angioblasts. Similar findings were reported in human foetii according to which the immature glomeruli developed as epithelial cell masses enclosed by the parietal and visceral layer of Bowman's capsule [17]. The proximal convoluted tubules were lined by simple columnar epithelium. Their rounded vesicular nuclei occupied the broad basal half of the cells whereas the distal convoluted tubules were lined by cuboidal epithelium (Fig. 2). The centrally placed nuclei of these cells appeared close to each other as compared to those of the proximal segment. Their nuclei were smaller than those of the proximal tubules.

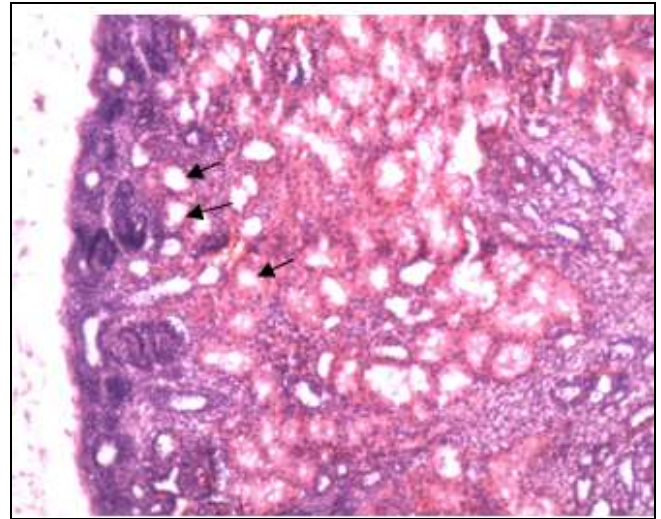


Fig 2: Photomicrograph of the kidney of 48 days old goat foetus showing developing proximal and distal convoluted tubules (arrows), H&E, 100X.

At 50 days of gestation (CRL=7.6 cm), the formation of the nephrogenic vesicles and their elongation into S-shaped structures increased in all three zones of the cortex *i.e.* subcapsular, intermediate and juxta medullary zones. Similar observations were made in goat embryos at 58 days of gestation [3]. The lower cup shaped end of these structures was crescentic with a potential Bowman's space between the outer and inner epithelial walls. Furthermore, the cells which gave rise to Bowman's capsule and the epithelial portion of the glomeruli were different entities [6]. The ingrowing of mesenchymal cells gave rise to glomerular capillaries. These capillary vessels invaded the space between the middle and lower limbs of the S-shaped body [13].

Group-II

At 59 days (CRL=8.10 cm) of gestation, the renal corpuscles of the subcapsular region were although crescentic in shape, the same in the juxta medullary region of the kidney (metanephros) resembled those of the mature kidney in shape and structure. The tubular segments of grown up nephrons in all three zones *i.e.* subcapsular, intermediate and juxta medullary zones showed division into the proximal convoluted tubule, a loop of Henle and distal convoluted tubule (Fig. 3). Similar observations were made in goat embryos at 58 days of gestation [3]. The ascending and descending loops of Henle could not be differentiated histologically from the proximal and distal convoluted tubules at this stage. The thick ascending limb of the loop of Henle was demonstrated at the age of 23.0 cm Curved Crown Rump Length (CVRL). Similar findings were reported in goat embryos [3, 5]. The thin segment of the loop was lined by simple squamous epithelium. It was similar to the earlier reports in goat embryos [5]. At 80 days of gestation (CRL=16.3 cm), the renal corpuscles of the similar structure were seen throughout the cortex of the kidney (metanephros). However, renal glomeruli showed their development in dogs by in-growth of interstitial mesenchyme into the Bowman's capsule [11].

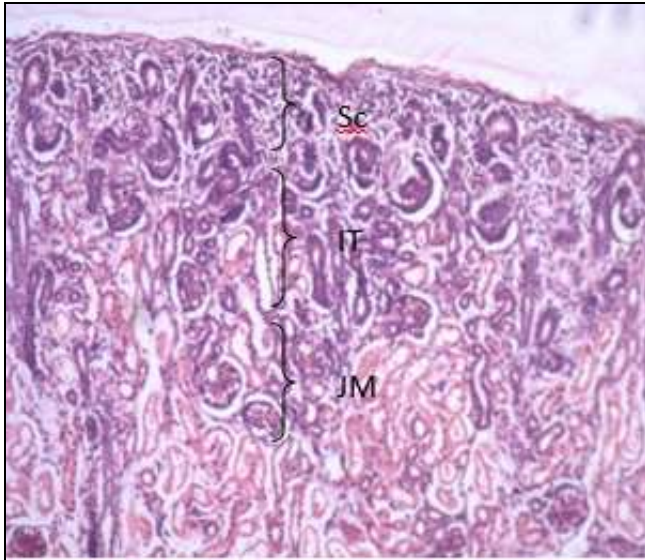


Fig 3: Photomicrograph of the kidney of 59 days old goat foetus showing subcapsular (Sc), Intermediate (IT) and juxta medullary regions, H&E, 100X.

Group-III

The epithelium of the proximal convoluted tubules rested on a distinct basement membrane. At 135 days of gestation (CRL=32.90 cm), a distinct brush border was observed at the apical border of the lining columnar cells of the proximal convoluted tubules (Fig. 4). These tubules were lined by simple columnar epithelium in the foetii of 4.1 cm and 5.7 cm. The formation of microvilli at the luminal end of the epithelial cells was first formed at the age of 11.2 cm CVRL. The coiling of the proximal convoluted tubule also appeared at this age. In the foetii of 23.0 cm CVRL, these tubules were lined by simple cuboidal to the pyramidal type of cells along with microvilli, which indicated its reabsorptive and secretory activities as reported in goat embryos [3,5].

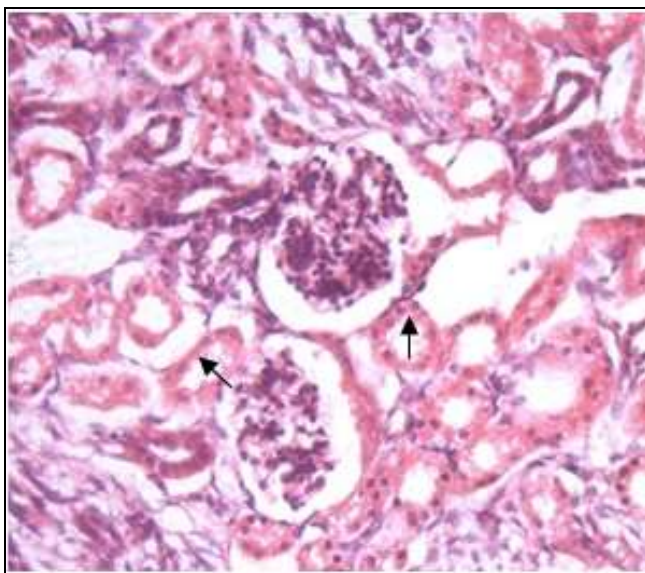


Fig 4: Photomicrograph of the kidney of 135 days old goat foetus showing brush borders (arrows) in the proximal convoluted tubules, H&E, 200X.

Juxta Glomerular Apparatus

Group-I

In the foetus of 50 days gestational age (CRL=7.6 cm), the renal corpuscles were spherical in shape and the majority of

them contained vascular glomeruli. Near the vascular pole of few nephrons, the afferent arterioles were lined by differentiating elongated mesenchymal cells. The cytoplasm of these cells was granular and eosinophilic with spherical shaped nuclei, which might be referred to as the future juxtaglomerular cells. True juxtaglomerular cells were noticed in goat embryos of 70 mm CRL. The distal convoluted tubule was observed placing itself in close association with the afferent and efferent arterioles at some places. Some cells of the cuboidal epithelium of the distal convoluted tubule became aggregated which could be referred as the forerunners of the macula densa (Fig. 5) as reported in sheep [16].

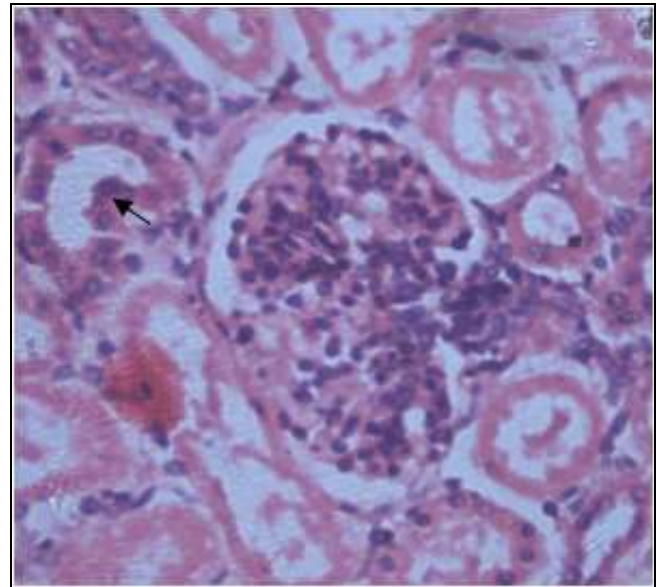


Fig 5: Photomicrograph of the kidney of 50 days old goat foetus showing macula densa (arrow), H&E, 400X.

Group-II

At 62 days (CRL=10.10 cm) of foetal age, true juxta glomerular cells were noticed (Fig. 6). They had a granular cytoplasm with ovoid nuclei.

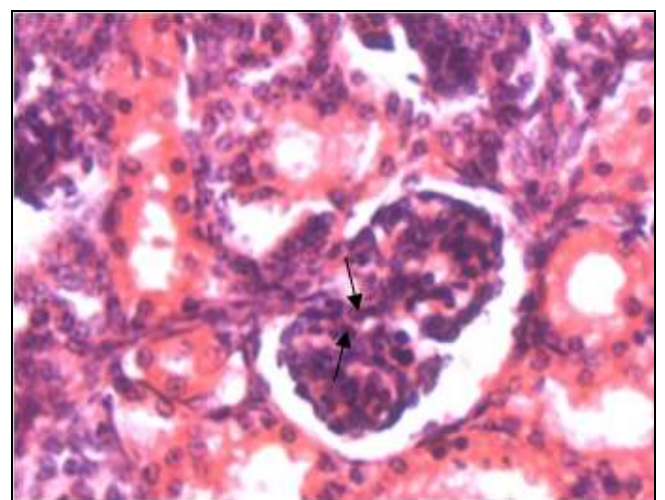


Fig 6: Photomicrograph of the kidney of 62 days old goat foetus showing juxta-glomerular cells (arrows), H&E, 400X.

Group-III

The cytological characteristics of the juxta glomerular cells and the macula densa were similar to the description of the previous group.

Histochemistry

Glycogen

In the present study, the capsule in this group showed weak reactions to glycogen. However, the glomerulus exhibited a moderate to strong reaction (Fig. 7). The parietal & visceral layers of the Bowman's capsule and the loop of Henle showed moderate reactions to glycogen. Again, the proximal and distal convoluted tubules, arched collecting tubules and straight collecting tubules exhibited moderate to strong reactions to glycogen. The thin segment was lined by flattened or low cuboidal cells, as described in the adult kidneys of various animals [14, 18].

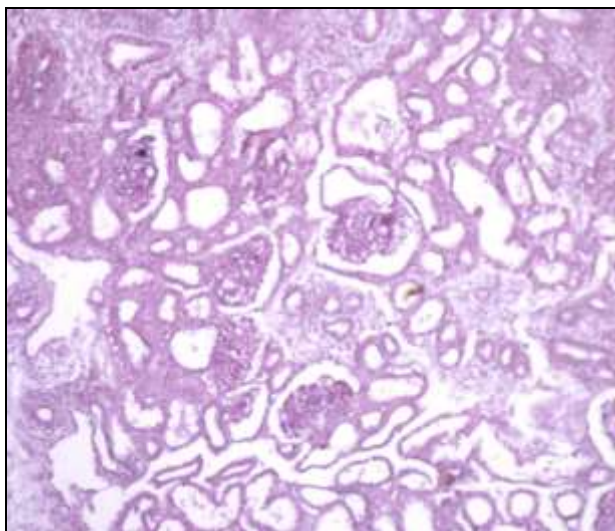


Fig 7: Photomicrograph of the kidney of 50 days old goat foetus showing reactions to glycogen, Mc Manus method, 100X.

Group-II

In the kidney (metanephros) of these foetii, the capsule showed moderate to strong reactions to glycogen. Again, the glomerulus and parietal and visceral layers of the Bowman's capsule showed intense and moderate reactions, respectively. A similar reaction was observed in the kidney of various laboratory animals [18]. The proximal and distal convoluted tubules, a loop of Henle, arched collecting tubules, straight collecting tubules and papillary ducts exhibited strong reactions to glycogen. The juxta glomerular cells, renal pelvis, macula densa and renal stroma showed similar kinds of reactions as the previous group.

Group-III

The capsule showed moderate to strong reactions to glycogen. The glomerulus was intensely reactive to glycogen with parietal & visceral layers of the Bowman's capsule showed moderate reactions. Glycogen was seen in the infranuclear zone of the epithelial cells, lining the proximal convoluted tubules in goat embryos of mid gestation and onwards [19]. The proximal and distal convoluted tubules, a loop of Henle, arched collecting tubules, straight collecting tubules and papillary ducts exhibited strong reactions to glycogen. The juxta glomerular cells exhibited strong reactions while the macula densa was intensely reactive to glycogen. The renal

stroma also showed moderate to strong reactions to glycogen.

Basic Proteins

Group-I

In the present study, the capsule showed weak reactions to basic proteins. Similarly, the glomerulus and parietal and visceral layers of the Bowman's capsule showed strong and weak to moderate reactions to basic proteins, respectively (Fig. 8). Again, the proximal and distal convoluted tubules, loop of Henle, arched collecting tubules, straight collecting tubules and papillary ducts exhibited moderate to strong reactions to basic proteins. These findings were in agreement with the findings reported in the goat [3, 5].

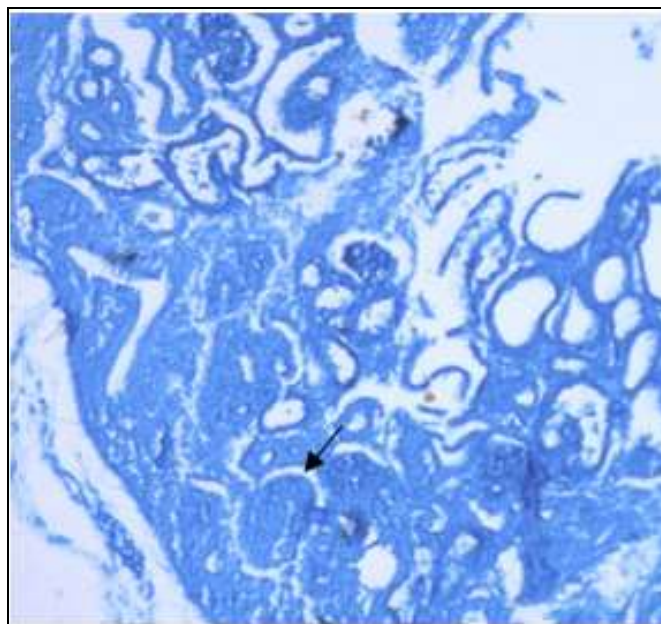


Fig 8: Photomicrograph of the kidney of 46 days old goat foetus showing reactions by Bowman's capsule to basic proteins (arrow), Bromophenol Blue method, 100X.

Group-II

In this age group, the capsule showed moderate reactions to basic proteins. Again, the glomerulus and parietal and visceral layers of the Bowman's capsule showed strong and weak to moderate reactions to basic proteins, respectively. The proximal and distal convoluted tubules, a loop of Henle, arched collecting tubules, straight collecting tubules and papillary ducts exhibited moderate to strong reactions to basic proteins. The juxta glomerular cells were moderately reactive to basic proteins.

Group-III

In this goat foetii, the capsule showed moderate to strong reactions to basic proteins. The glomerulus exhibited an intense reaction. Again, the parietal and visceral layers of the Bowman's capsule, the proximal and distal convoluted tubules, a loop of Henle, arched collecting tubules, straight collecting tubules and papillary ducts exhibited strong reactions to basic proteins (Fig. 9). The juxta glomerular cells were moderate to strongly reactive to basic proteins.

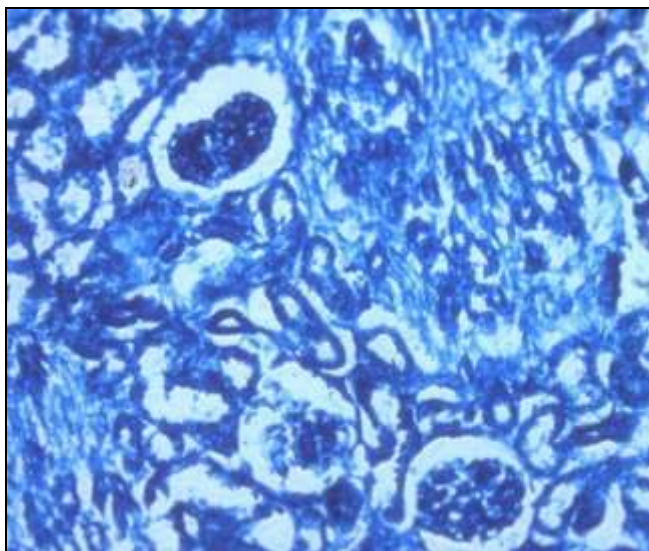


Fig 9: Photomicrograph of the kidney of 121 days old goat foetus showing reactions to basic proteins (arrow), Bromophenol Blue method, 200X.

Neutral mucopolysaccharides

Group-I:

In the present study, the capsule showed the moderate reaction to neutral mucopolysaccharides. Similarly, the glomerulus and parietal and visceral layers of the Bowman's capsule showed moderate to strong and moderate reactions to neutral mucopolysaccharides, respectively (Fig. 10). The proximal convoluted tubules showed moderate to strong reactions while the distal convoluted tubules, a loop of Henle, arched collecting tubules, straight collecting tubules, papillary ducts, renal pelvis, macula densa and renal stroma exhibited moderate reactions to neutral mucopolysaccharides. It may be correlated with the secretory and reabsorptive activities of these tubules [1].

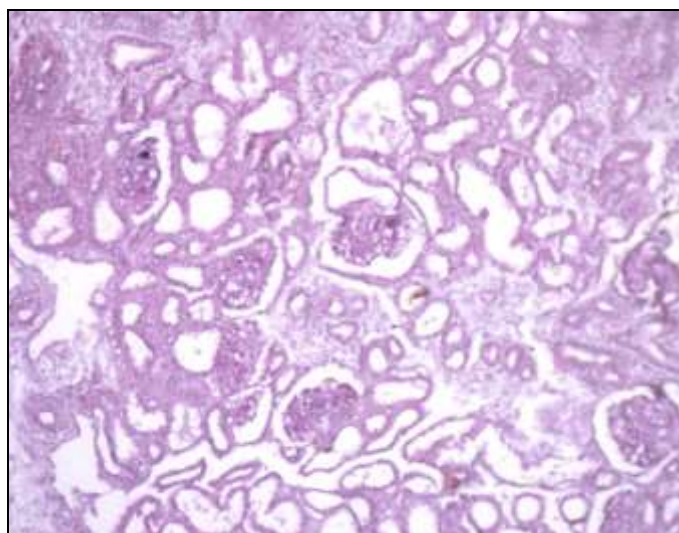


Fig 10: Photomicrograph of the kidney of 48 days old goat foetus showing reactions to neutral mucopolysaccharides, PAS method, 100X.

Group-II

In this age group, all the compartments of the foetal kidney (metanephros) showed almost similar reactions to neutral mucopolysaccharides as the previous group except that the juxta glomerular cells were moderately reactive to neutral mucopolysaccharides.

Group-III

In these goat foetii, all the compartments showed the similar reactions to neutral mucopolysaccharides as the previous group.

Acidic mucopolysaccharides

Group-I

In the present study, the capsule showed the weak reaction to acidic mucopolysaccharides. However, the glomerulus exhibited moderate to strong reaction (Fig. 11). The parietal & visceral layers of the Bowman's capsule and proximal convoluted tubules showed moderate to weak reactions while the distal convoluted tubules exhibited moderate reactions to acidic mucopolysaccharides. These findings were in agreement with the findings reported in the goat according to which mild reaction of acid mucopolysaccharides was observed in the kidney [3, 5].

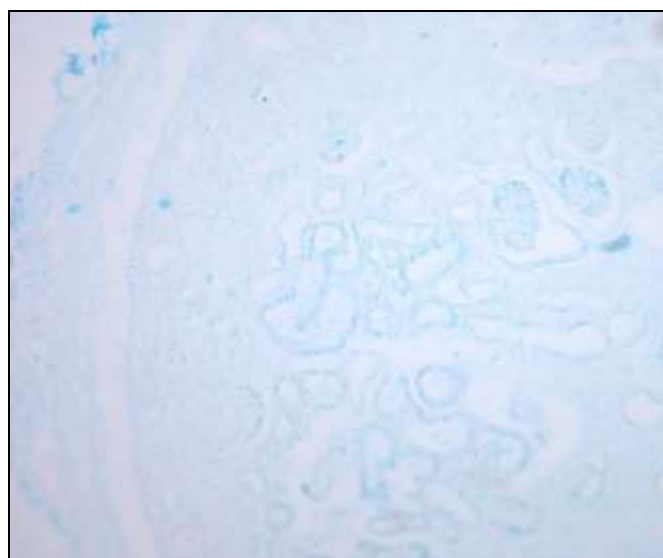


Fig 11: Photomicrograph of the kidney of 48 days old goat foetus showing reactions to acidic mucopolysaccharides, Alcian Blue method, 100X.

Group-II

The capsule showed moderate to strong reactions to acidic mucopolysaccharides. The glomerulus exhibited a strong reaction (Fig. 12). The parietal and visceral layers of the Bowman's capsule and proximal convoluted tubule were moderate to strongly reactive. Again, distal convoluted tubules, loop of Henle, arched collecting tubules, straight collecting tubules and papillary ducts exhibited moderate reactions to acidic mucopolysaccharides. The juxta glomerular cells exhibited moderate reactions. These findings were similar to the findings reported in the goat foetus [3].

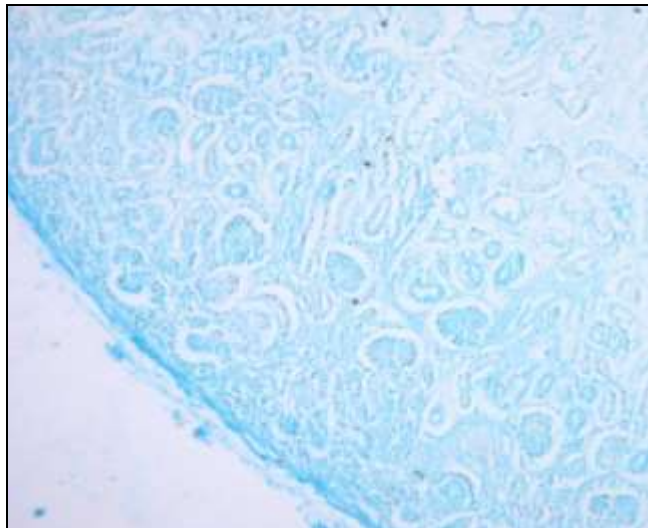


Fig 12: Photomicrograph of the kidney of 82 days old goat foetus showing reactions to acidic mucopolysaccharides, Alcian Blue method, 100X.

Group-III

In this age group, all the compartments of the foetal kidney (metanephros) showed almost similar reactions to acidic mucopolysaccharides as the previous group.

4. Conclusion

Microscopic observations revealed that the differentiating mesenchymal cells had a cord like arrangement and aggregated as nephrogenic vesicles near the capsule. The proximal convoluted tubule was lined by simple columnar epithelium and the distal convoluted tubule was lined by simple cuboidal epithelium in all stages of development. The renal corpuscles of the juxta medullary region of the kidney resembled those of the mature kidney in shape and structure. Also, the histochemical moieties showed that the capsule of foetii of group-I showed weak reactions to glycogen which intensified in older foetii. Similarly, the other structural components of the kidney showed enhanced histochemical reactions to basic protein, neutral & acidic mucopolysaccharides and glycogen with advancing gestational age of the goat foetii.

5. Acknowledgement

The work described here was the part of the M.V.Sc thesis of the first author. The facilities provided by the Division of Veterinary Anatomy, F.V.Sc & A.H., SKUAST-Jammu, India are duly acknowledged.

6. References

1. Banks WJ. Applied Veterinary Histology. Edn 4, Mosby Year book, St. Louis, USA, 1993, 374-389.
2. Canfield PJ. Development of the Bovine Metanephros. *Anatomia Histologia Embryologia* 1980;9:97-107.
3. Chaudhary AR, Farooqui MM, Chandra P. Histological and certain histochemical studies on the metanephros of goat (*Capra hircus*) in prenatal period-secretory part. *Indian Journal of Veterinary Anatomy* 2002;14:8-15.
4. Davies JC. Nephric development in the sheep with reference to the problem of the ruminant pronephros. *Journal of Anatomy* 1952;85:56-61.
5. Gopinath S. Morphogenesis of the kidney in goat. Ph.D. thesis. Haryana Agricultural University, Hisar, India 1985.

6. Jokelainen P. An electron microscopic study of the early development rat metanephric nephron. *Acta Anatomica*. 1963;47:1-71.
7. Latshaw WK. Veterinary Developmental Anatomy-A Clinically Oriented Approach Blackwell Scientific Publication Limited, Oxford, England 1987.
8. Longley JB, Fisher ER. Alkaline phosphatase and periodic acid-Schiff reaction in the proximal tubules of the vertebrate kidney. A study in segmental differentiation. *The Anatomical Record* 1954;120:1-22.
9. Longley JB. Histochemistry of the kidney in "The Kidney". Edn Rouiller and Muller, Academic Press, New York, 1969;I:157-237.
10. Luna LG. Manual of histological staining methods of armed forces, Institute of Pathology, Edn 3, McGraw Hill Book Company, New York 1968, 153-173.
11. Mullnik JWMA. Development of renal glomerulus in dogs. *Veterinary Bulletin* 1971;41:708.
12. Onarlioglu B, Gursoy E, Kaloglu C. Renal morphogenesis of rat foetus. *Turkish Journal of Animal Sciences* 1997;21:493-496.
13. Potter EL. Development of the human glomerulus. *Archives of Pathology* 1965;80:241-255.
14. Rouiller CH. General anatomy and histology of the kidney in "The Kidney". Edn Rouiller and Muller, Academic Press, New York 1969;I:61-140.
15. Singh Y, Sharma DN, Dhingra LD. Morphogenesis of the testis in goats. *Indian Journal of Animal Sciences* 1979;49:925-931.
16. Stratford BF, Ryan GB. Morphogenesis of the renal juxta glomerular apparatus and peripolar cells in the sheep. *Cell Tissue Research* 1982;222:101-111.
17. Vernier RL, Birch-Anderson A. Studies of the human foetal kidney. *Journal of Pediatrics* 1962;60:754-768.
18. Yadava PR, Colhoun ML. Comparative histology of the kidney of domestic animals. *American Journal of Veterinary Research* 1958;19:958-931.